

**DEVELOPMENTAL BIOLOGY OF THE *SCHISTOSOMA MANSONI*  
IN THE INTERMEDIATE HOST SNAIL.**

DISS  
BIO  
1484  
e-1



**A THESIS SUBMITTED IN PARTIAL FULFILMENT OF THE  
REQUIREMENT FOR THE DEGREE OF DOCTOR OF PHILOSOPHY**



**BY  
ILLAHI BUX KALHORO  
DEPARTMENT OF BIOLOGICAL SCIENCES, QUAID-I-AZAM  
UNIVERSITY, ISLAMABAD PAKISTAN**

**2005**

DEVELOPMENTAL BIOLOGY OF THE *SCHISTOSOMA MANSONI*  
IN THE INTERMEDIATE HOST SNAIL.



A THESIS SUBMITTED IN PARTIAL FULFILMENT OF THE  
REQUIREMENT FOR THE DEGREE OF DOCTOR OF PHILOSOPHY



BY  
ILLAHI BUX KALHORO  
DEPARTMENT OF BIOLOGICAL SCIENCES, QUAID-I-AZAM  
UNIVERSITY, ISLAMABAD PAKISTAN

2005

IN THE NAME OF ALLAH,

THE MOST GRACIOUS, THE MOST MERCIFUL



Thanking

HIM

with full heart and devoted tongue

**This thesis is dedicated to my entire family, for their love and support, particularly to my mother. This thesis is also dedicated to my late father Ali Mohammed and younger brother Hadi Bux Kalhoro who died during present study.**

## CERTIFICATE

This thesis by **Illahi Bux Kalhoro**, is accepted in its present form by the Department of Biological Sciences, as satisfying the thesis requirements for the degree of Doctor of Philosophy in Biology.

Supervisor *Samina Jalali*  
Prof. Dr. Samina Jalali

1) External Examiner *Jahangir Arshad*  
Dr. Jahangir Arshad

2) External Examiner *AN*  
Dr. Allah Nawaz

Chairperson *Samina Jalali*  
Prof. Dr. Samina Jalali

Dated:- 18-6-2005

## TABLE OF CONTENTS

	Page
<b>ACKNOWLEDGEMENTS</b>	i
<b>THESIS ABSTRACT</b>	ii-v
<b>ABBREVIATION</b>	vi-vii
<b>GENERAL INTRODUCTION</b>	1-13
Schistosomiasis	1-2
Histopathological findings and diagnosis	2-3
Treatment and control	3-4
Importance of genus <i>Schistosoma</i>	6
Schistosomes found in Indo-Pakistan subcontinent and other regions of the world	6-10
Life cycle of schistosome in general	10
Developmental stage in the intermediate host snails	11
Effects of <i>Schistosoma mansoni</i> on the intermediate host snails	12-13
<b>CHAPTER 1.</b>	14-71
Histological studies of post-penetration by the miracidia of <i>Schistosoma mansoni</i> into snails of <i>Biomphalaria glabrata</i> .	
Abstract	14-15
Introduction	16-19
Materials and methods	20
Results	21-67
Discussion	68-71
<b>CHAPTER 2.</b>	72-116
Histopathological studies of the snails of <i>Biomphalaria glabrata</i> due to the mother sporocysts of <i>Schistosoma mansoni</i> .	
Abstract	72-73
Introduction	74
Materials and methods	75
Results	75-112
Discussion	113-116



<b>CHAPTER 3.</b>	117-136
Histopathological studies of the snails of <i>Biomphalaria glabrata</i> due to the daughter sporocysts and cercariae of <i>Schistosoma mansoni</i> .	
Abstract	117-118
Introduction	119-121
Materials and methods	121
Results	122-133
Discussion	134-136
<b>CHAPTER 4.</b>	137-171
Histopathological studies of the ovotestis of the snails of <i>Biomphalaria glabrata</i> during <i>Schistosoma mansoni</i> infections.	
Abstract	137-138
Introduction	139-142
Materials and methods	143
Results	143-166
Discussion	167-171
<b>APPENDIX</b>	172-175
<b>REFERENCES</b>	176-186

## LIST OF TABLES

CHAPTER 1.	Page
Table No.1.1 Distribution of the mother sporocysts in various infected organs among susceptible and resistant snails of <i>Biomphalaria glabrata</i> mass-exposed to miracidia of <i>Schistosoma mansoni</i> over a period of 10 DPE..	22
Table No.1.2 Number of infected snails and types of mother sporocysts of <i>Schistosoma mansoni</i> in the foot of the infected susceptible and resistant snails of <i>Biomphalaria glabrata</i> .	25
Table No.1.3 Mean diameter ( $\pm$ SEM) of the mother sporocysts in the foot of susceptible and resistant snails.	29
Table No.1.4 Number of infected snails and types of mother sporocysts of <i>Schistosoma mansoni</i> in the head of the infected susceptible and resistant snails of <i>Biomphalaria glabrata</i> .	31
Table No. 1.5 Mean diameter ( $\pm$ SEM) of the mother sporocysts in the head of susceptible and resistant snails.	34
Table No.1.6 Number of infected snails and types of mother sporocysts of <i>Schistosoma mansoni</i> in the lip of the infected susceptible and resistant snails of <i>Biomphalaria glabrata</i> .	36
Table No.1.7 Mean diameter ( $\pm$ SEM) of the mother sporocysts in the lip of susceptible and resistant snails.	39
Table No.1.8 Number of infected snails and types of mother sporocysts of <i>Schistosoma mansoni</i> in the tentacles of the infected susceptible and resistant snails of <i>Biomphalaria glabrata</i> .	41
Table No.1.9 Mean diameter ( $\pm$ SEM) of the mother sporocysts in the tentacles of susceptible and resistant snails.	46
Table No.1.10 Number of infected snails and types of mother sporocysts of <i>Schistosoma mansoni</i> in the mantle of the infected susceptible and resistant snails of <i>Biomphalaria glabrata</i> .	48
Table No.1.11 Mean diameter ( $\pm$ SEM) of the mother sporocysts in the mantle of susceptible and resistant snails.	51
Table No. 1.12 Number of infected snails and types of mother sporocysts of <i>Schistosoma mansoni</i> in the various organs of the infected susceptible and resistant snails of <i>Biomphalaria glabrata</i> .	53-54
Table No. 1.13 Mean diameter ( $\pm$ SEM) of the mother sporocysts in the various organs of susceptible and resistant snails.	66
<b>CHAPTER 2.</b>	
Table No. 2.1 Distribution of the host responses in the various organs of the susceptible and resistant snails of <i>Biomphalaria glabrata</i> mass exposed to miracidia of <i>Schistosoma mansoni</i> over a period of 10 DPE.	76
Table No. 2.2 Number of host responses in the foot of the infected susceptible and resistant snails of <i>Biomphalaria glabrata</i> .	80
Table No. 2.3 Number of host responses in the head of the infected susceptible and resistant snails of <i>Biomphalaria glabrata</i> .	83





Table No. 2.4 Number of host responses in the lip of the infected susceptible and resistant snails of <i>Biomphalaria glabrata</i> .	86
Table No. 2.5 Number of host responses in the tentacles of the infected susceptible and resistant snails of <i>Biomphalaria glabrata</i>	89
Table No. 2.6 Number of host responses in the mantle of the infected susceptible and resistant snails of <i>Biomphalaria glabrata</i> .	92
Table No. 2.7 Number of host responses in the anus of the infected susceptible and resistant snails of <i>Biomphalaria glabrata</i> .	95
Table No. 2.8 Number of host responses in the various organs of the infected susceptible and resistant snails of <i>Biomphalaria glabrata</i> .	98
Table No. 2.9 Number of host responses in the over all organs of the infected susceptible and resistant snails of <i>Biomphalaria glabrata</i> .	100
Table No. 2.10 Mean diameter ( $\pm$ SEM) of the infiltration of hemocytes in the various organs of susceptible and resistant snails of <i>Biomphalaria glabrata</i> .	104
Table No. 2.11 Mean diameter ( $\pm$ SEM) of the encapsulation in the various organs of susceptible and resistant snails of <i>Biomphalaria glabrata</i>	108
Table No. 2.12 Mean diameter ( $\pm$ SEM) of the cyst formations in the various organs of susceptible and resistant snails of <i>Biomphalaria glabrata</i>	112
<b>CHAPTER 3.</b>	
Table No.3.1 Number of infected snails and daughter sporocysts of <i>Schistosoma mansoni</i> found in the various organs of the susceptible and resistant snails of <i>Biomphalaria glabrata</i> .	123
Table No.3.2 Chi-square test applied on the total numbers of infected snails and daughter sporocysts present in the various organs of the susceptible and resistant snails of <i>Biomphalaria glabrata</i> .	125
Table No. 3.3 Mean diameter ( $\pm$ SEM) of the daughter sporocysts in the various organs of susceptible and resistant snails of <i>Biomphalaria glabrata</i> .	130
<b>CHAPTER 4</b>	
Table No. 4.1 Number and mean diameter ( $\pm$ SEM) of the acini of the ovotestis of the susceptible snails of the <i>Biomphalaria glabrata</i> .	144
Table No. 4.2 Number of the various types of the female germinal cells present normal and infected acini of the ovotestis of the susceptible snails of the <i>Biomphalaria glabrata</i> .	146
Table No. 4.3 Mean diameter ( $\pm$ SEM) of the various types of the female germinal cells found in the normal and infected acini of the ovotestis of the susceptible snails of the <i>Biomphalaria glabrata</i> .	157
Table No. 4.4 Mean diameter ( $\pm$ SEM) of the various types of the male germinal cells found in the normal and infected acini of the ovotestis of the susceptible snails of the <i>Biomphalaria glabrata</i> .	166

## LIST OF FIGURES

GENERAL INTRODUCTION	Page
1) Global distribution of the schistosomiasis.	5
 <b>CHAPTER 1.</b>	
2) Scheme of organization of the <i>Biomphalaria</i> snail.	17
3) Miracidium of <i>Schistosoma mansoni</i> .	18
4) Developmental stages of the <i>Schistosoma mansoni</i> mother sporocysts in the various organs of the susceptible snails of the <i>Biomphalaria glabrata</i> .	44
5) Developmental stages of the <i>Schistosoma mansoni</i> mother sporocysts in the various organs of the resistant snails of the <i>Biomphalaria glabrata</i> .	64
 <b>CHAPTER 2.</b>	
6) Development of the host responses due to the <i>Schistosoma mansoni</i> mother sporocysts in the various organs of the susceptible and resistant snails of the <i>Biomphalaria glabrata</i> .	
a-f) Infiltration of hemocytes, inflammation and various stages of the encapsulation of the single and double mother sporocysts.	106
g-k) Encapsulation of the multiple mother sporocysts and various stages of the cysts formation.	110
 <b>CHAPTER 3.</b>	
7) Daughter sporocysts of the <i>Schistosoma mansoni</i> and host responses in the various organs of the susceptible, resistant and giant snails of the <i>Biomphalaria glabrata</i> .	128
8) Mature daughter sporocysts and cercariae of the <i>Schistosoma mansoni</i> and host responses in the various organs of the susceptible and resistant snails of the <i>Biomphalaria glabrata</i> .	133
 <b>CHAPTER 4.</b>	
9) Histopathology of acini, atretic and previtellogenic oocytes in the ovotestis of the susceptible snails	
a-d) Histology of the acini, normal early and atretic oogonia present in the acinus of the ovotestis of the susceptible snails.	148
e-i) Histopathology of the infected previtellogenic oocytes	150
10) Histopathology of the stage I and II vitellogenic oocytes	
a-b) Histopathology of the normal and infected stage I vitellogenic oocytes	152
c-h) Histopathology of the stage I oocytes and normal II vitellogenic oocytes	153
i-l) Histopathology of the irregular shaped stage II vitellogenic oocytes	155
11) Histology of the spermatogenic cells in the acini of the ovotestis of the susceptible snails.	159
12) Histology of the spermatocytes, spermatids and mature sperms of the snails.	
a-d) Histology of the spermiogenesis.	161
e-f) Spermatids and mature sperms are visible close the sidewall of the acinus	163
g-j) Mature sperms are close to Sertoli cells, oocytes and below spermatids.	164

## ACKNOWLEDGEMENTS

First of all, I would like to thank Almighty Allah, Who has sustained me with His manifold blessings.

Sincere gratitude is given to my supervisor and chairperson, **Prof. Dr. Samina Jalali**, for her supervising my project, invaluable advice, help, great patience and confidence throughout my Doctoral studies.

I would like to gratitude, Chairperson Department of Biological Sciences, for her continuous encouragement and cooperation during study.

I would also like to express my gratitude to: Dr. S.A. Shami, Ex. Associate Professor, Quaid-I-Azam University, Islamabad for helping in statistical analysis. I would like to offer many thanks to Prof. Dr. Afsari S. Qureshi and Dr. M. Afzal, for providing me computer and scanning facilities.

I am highly grateful to Professor Dr. Bashir Ahmed Sheikh, Vice Chancellor, Sindh Agriculture University, Tando Jam for sparing me to study at the Quaid-I-Azam University, Islamabad.

The tremendous moral support of my teachers in the Faculty of Animal Husbandry and Veterinary Sciences, S.A.U. Tando Jam and friends, especially Dr. Amir Bakhsh Kalhoro, G.B. Issani, M.G. Perdehi, R.U. Rind, Prof. N.N. Ansari, N.A. Kanhar, T.Z. Avesi, L.A. Khan, and Zaheer Nasir (PASTIC) greatly exceeds my ability but not my desire to thank them.

Immeasurable thanks to my mother, brothers, and cousins for their unending love and support throughout the long ordeal. I would like to thank Hajani Ameer Zadi (wife), Hajani Hamida, Hajani Halima, Hajani Safya, Saiqa, Faiza and Sana (daughters), Haji Noor Illahi and Farhaz Illahi (Ali Mohammed) (sons) for their patience and understanding during my stay in Islamabad.

The studies in this thesis were carried out at Developmental Biology Laboratory, Quaid-I-Azam University, Islamabad.

***ILLAHI BUX KALHORO***

## Thesis Abstract

Snails from *Biomphalaria glabrata* stock, unselected ordinary (Albino) susceptible, selected pigmented resistant and giant intermediate hosts of *Schistosoma mansoni* were studied for the developmental biology and histopathology. Histological serial sections of 128 snails of the three groups mass exposed to miracidia (MI) of *S. mansoni* were carried out in order to analyze the determination, location, migration and development of the various stages of the parasite and host responses.

In chapter one comparative histology of above snails (50 susceptible, 55 resistant and 3 giant) of *B. glabrata* have been studied for development of the mother sporocyst (MS) after 1-10, 30 and 40 DPE. After penetration by *S. mansoni* MI detailed histological examination of various organs of the susceptible snails showed normal development of MS from 1-10 DPE. MS were visible in the foot, head, lips, tentacles, mantle, anus and buccal mass of the susceptible snails after 1-4 DPE. The beginning of the migration of the MS was observed at 3 and 4 DPE in the mantle, muscles of the anus and buccal mass of the susceptible snails. At 5 DPE some broad, few irregular, thin, elongated MS were observed in the above mentioned organs, neck and reached in the kidney of the susceptible snails. The next step of the migration of the MS was observed in the kidney at 5 DPE. From 6 DPE and onwards within the body of the mature MS embryos of the daughter sporocysts (DS) were found in the foot, head, lip, tentacles, mantle, kidney and esophagus of the susceptible snails. After 8 DPE in the foot, head, and lip of the susceptible snails within the body of the mature MS developed few embryos of the DS ruptured tegument and migrating towards deeper organs. After 9 and 10 DPE MS are visible in the pericardial cavity of the heart and respiratory epithelium of the lung of the susceptible snails. In resistant snails MS were located in the foot, head, lip, tentacles, mantle, anus, buccal mass, neck and columellar muscles from 1-10 DPE. Single MS were observed in the foot, head, lip, tentacles, mantle, neck, anus and buccal mass of these snails throughout infection period. While multiple MS were only visible in the tentacle and columellar muscles of the resistant snails after 9 DPE. No any further migration or mature MS was observed in these snails. During infections four types of the MS (single, multiple, mature and migratory) were recognized in the susceptible snails. Among all infected organs the highest total number of the 24 single and 189 multiple MS found in the head and foot of the susceptible snails respectively. In the resistant snails few number of single and multiple MS were found. Chi-square test results shows highly significant difference in between the overall MS in various infected organs of the susceptible and resistant snails ( $\Sigma X^2_{(1)} 21.58, P < 0.001$ ).

The body of the MS was characterized by thin tegument with cells, some germinal cells contained scanty cytoplasm, nuclei with prominent nucleolus, muscles, vacant spaces, apical gland and penetration glands at 1-2 DPE. At 2 DPE single MS further grow and become multiple at 3 DPE and onwards in the susceptible snails. After 5 DPE great proliferation of the germinal cells increased their number and size so that they occupy practically entire body of broad MS. The germinal cells as they increase in size have increased amount of cytoplasm and their nuclei are with prominent nucleoli. The germinal cells spread or distribute to form few clusters and masses of large numbers of these cells inside the body of the mature MS from 6 DPE and onwards. In the susceptible snails few embryos of the DS ruptured tegument and migrated towards deeper organs after 8 DPE. In the resistant snails development of the MS is characterized by tegument, vacant spaces, prominent penetration glands, few germinal cells had nuclei with nucleoli and little

cytoplasm. Very few MS exhibits thin tegument, dark nuclei of germinal cells, increased vacant spaces, spread penetration gland and surrounded by hemocytes reaction. The highest mean diameter of the single MS found in the head susceptible snails ranges between  $37.65 \pm 5.55 \mu\text{m}$  and  $99.75 \pm 9.38 \mu\text{m}$  from 1-10 DPE. In the foot of the resistant snails mean diameter ( $\pm$  SEM) of the single MS ranges between  $48.08 \pm 2.15$  and  $92.91 \pm 18.53 \mu\text{m}$  during the infection.

The giant snails had white patches on the regions of the ventral surface of the foot and selected for gigantism. In the posterior surface of the foot multiple MS were surrounded by strong hemocytes and mature MS containing embryos of DS after 30 DPE. In later infection at 40 DPE MS were visible in the most of the above organs, mantle rim, mantle cavity, radula, kidney, respiratory epithelium of the lung, shell epithelium, salivary glands, hemocytes producing organ and albumin glands of the resistant snails. MS was single in the foot, head, tentacles, buccal mass, neck, radula, and hemocytes producing organ. While increasing numbers of the multiple and mature MS were visible in the anus, mantle, kidney, respiratory epithelium of the lungs and albumin glands of the animals.

In chapter two histopathological studies of the susceptible, resistant and giant snails have been done during the development of the MS. The histological examination of the various organs shows infiltration of hemocytes, encapsulations and cysts are developed in some of the susceptible snails. Whereas, in addition to these host responses early tissue reaction was visible in the resistant snails from 1-10 DPE. These responses were found in the foot, head, lip, tentacles, mantle, gut, mantle cavity and kidney of the susceptible snails. However, in the resistant snails these responses were also noticed in the first six organs mentioned earlier in the susceptible snails, pharynx, mantle rim, anus and respiratory epithelium of the lung during the period of the infection. The number of the infected organs of the snails was counted. Chi-square test result shows highly significant difference between the infected organs of the susceptible and resistant snails ( $\Sigma X^2_{(1)} 33.47, P < 0.001$ ).

The histopathological studies of an infiltration of hemocytes exhibited accumulation of the several layers of the cells in the various organs of the snails. Similarly, an encapsulation of the MS was also surrounded by few to several layers of the hemocytes in the resistant snails. In case of the susceptible snails an encapsulation exhibited complete destruction of the multiple MS. The cyst was also surrounded by thin layers of hemocytes and characterized by complete destruction of the MS, few remains of the nuclei of the germinal cells, and increase vacuolated necrotic spaces.

After 30 DPE in the posterior surface of the foot of the giant snails few multiple MS were surrounded by strong hemocytes reaction. An infiltration of the hemocytes was observed in the foot and tentacle of these snails. An encapsulation of the MS and granulomas were also visible in the foot of the giant snails. In later infection after 40 DPE an infiltration of the hemocytes was visible in the respiratory epithelium of lung, kidney, gut, and heart of resistant snails. Inflammation and thin outer layer of respiratory epithelium of lung of resistant snail was also observed. An encapsulation of the MS was visible in the mantle, mantle cavity, and respiratory epithelium of lung of these snails. A cyst formation was also seen in the foot, head, tentacle, mantle, mantle cavity, mantle collar, buccal mass columellar muscles, lung, kidney, and gut of the resistant snails.

In chapter three development of the DS and cercariae (C) plus host responses in the various organs of the susceptible, resistant, and giant snails have been studied. At 9 and 10 DPE few DS were observed in the posterior viscera which include gut, digestive gland, and

ovotestis of the susceptible snails. The DS increased in number, multiplied and migrated in the deeper tissues of above organs at 15 DPE. In the digestive glands greater number of the DS was observed on 30 and 40 DPE respectively. Whereas, in resistant snails sections were made only on 9, 10 and 40 DPE. No DS was observed on 9 and 10 DPE, however, in later infection at 40 DPE the increased number of the DS visible in the gut and digestive glands of the resistant snail. Chi-square test results shows highly significant difference between the infected susceptible and resistant snails and DS found in the gut, digestive glands and ovotestis of the snails ( $\Sigma X^2_{(3)} 511.9, P < 0.001$ ).

The convoluted, longitudinal and broad shaped DS exhibits thick red tegument with spines at 9 DPE. Initially germinal cells were smaller then they increased in size, contained round or oval nucleus with prominent dark nucleoli in the center. At 20 DPE mature DS contained several germballs of the cercaria, tegument with prominent nuclei of cells, increase vacant spaces and in few early developments of the cercaria was observed. The head region, pre and post-acetabular and penetration glands and short tail region of the cercariae were also visible within the body of the DS. This stage further developed in digestive gland and ovotestis, matured and free cercariae were visible in the susceptible snails at 30 and 40 DPE respectively. During these developments few areas of an infiltration of hemocytes was visible in these organs. In the digestive glands thin walls and overgrowth was also prominent. Atrophy of the acini of the ovotestis was observed in these snails. At 30 DPE in the anterior surface of the foot of giant snails few mature DS containing few germballs and some encapsulations of the cercariae were visible. Enormous numbers of the DS and normal cercariae were observed in the digestive glands and ovotestis of these snails. Whereas, in the gut of the resistant snails at 40 DPE some mature DS contained several germballs of the cercaria. The range mean diameter of the DS found in the gut, digestive gland and ovotestis of the susceptible snails was  $33.01 \pm 4.41 \mu\text{m}$  to  $238.79 \pm 19.08 \mu\text{m}$ . In the chapter four histopathology of ovotestis of the unselected susceptible snails of *B. glabrata* the intermediate host of *S. mansoni* were studied after 9, 10, 15, 20, 30 and 40 DPE. The ovotestis was composed of transverse, longitudinal and irregular shapes and sizes of acini in the sectioning material and collecting canal. In *S. mansoni* infection the highest mean diameter of the acini was  $312 \pm 28.76 \mu\text{m}$  at 20 DPE. At 30 and 40 DPE infection of the mature DS and cercariae were progressing in the ovotestis of the snails. During these days the mean diameter of the acini was reduced. After detailed histological examination four types of female germinal cells were recognized. They are early oogonia, previtellogenic, stage I and II vitellogenic oocytes. Few atretic oogonia were also found during the infections. Early oogonia are very thin elongated, few in number, mostly located in the sidewall of the acinus, surrounded by dark thin outer membrane and cytoplasm at 9 DPE. They possess dark scanty cytoplasm. Atretic oogonia are surrounded by prominent outer membrane, filled with strongly dark cytoplasm with few vacuoles. Normal previtellogenic oocytes are spindle, elongated and oval shaped with darkly stained homogenous cytoplasm and spherical nucleus with one or two nucleolus. The stage I oocytes are mostly quadrilateral and triangular in shape. They are located close or below the stage II vitellogenic oocyte at the dorsal regions and sidewalls of the acini. The stage I vitellogenic oocyte is surrounded by few nurse cells with thin nuclei. These oocytes show prominent plasma membrane, dark vacuolated cytoplasm with yolk deposition and round nucleus. The early oogonia and previtellogenic oocytes have thin cell membrane, dark homogenous cytoplasm and nucleus with prominent nucleolus. The stage I and II

## Abbreviation

$\mu\text{m}$  = Micro meter  
*A* = *Australorbis*  
A = Acinus  
AG = Apical gland  
*B* = *Biomphalaria*  
BV = Blood vessel  
C = Cercariae  
°C = Centigrade  
CY = Cyst  
DPE = Days post-exposure  
DPX = Distrene-Plasticizer and Xylene  
DS = Daughter sporocyst  
DSG = Dividing spermatogonia,  
E = Eye  
EC = Early cercaria  
EM = Embryos  
EN = Encapsulation  
EOO = Early oogonia  
EPI = Epithelium  
F = Fibers  
FC = Free cercaria  
Fig = Figure  
G = Gut  
GB = Germballs  
GC = Germinal cells  
GI = Gizzard  
GL = Glycogen  
H = Hemocytes  
h = hour  
HE = Heart  
kg = Kilogram  
LS = Longitudinal section  
M = Migratory sporocyst  
MC = Mature cercaria  
ME = Membrane  
mg = Milligram  
MI = Miracidia  
ml – Mili liter  
MPE = Months post-exposure  
MS = Mother sporocyst  
MU = Mucous glands  
MUC = Mucous cells  
N = Necrosis  
NC = Nurse cells  
NM = Neural mass

No = Number  
NU = Nucleus  
OC = Oocyte  
PAS = Periodic acid and Schiff reaction  
PG = Penetration glands  
PGL = Pedal glands  
R = Resistant  
*S. Schistosoma*  
S = Susceptible  
SC = Sertoli cell  
S.E.M. Standard error and mean  
SG = Spermatogonia  
SP = Mature sperm  
SPC = Spermatocyte  
SPD = Spermatid  
T = Tegument  
TH = Thin  
TS = Transverse section  
WHO = World Health Organization  
WPE = Weeks post-exposure



# *GENERAL INTRODUCTION*

## General Introduction

### Schistosomiasis

Schistosomiasis is the fourth most prevalent disease in the world. It comprises a group of chronic diseases caused by schistosome (*S*), a genus of digenetic parasitic worms (Smith and Christie, 1986). Currently, 200 million people in 74 countries have this disease, 120 million of them have severe illness (Chitsulo et al., 2000). Infection results in a debilitating disease known as schistosomiasis or Bilharzia (Rabello et al., 1994). Endemic schistosomiasis is a disease of rural communities and its recent increase is due to the introduction of large scale irrigation schemes whenever water-filled canals become the breeding sites of snails (Jordon and Webbe, 1969). Various water snails act as the intermediate host. In many endemic countries, a high percentage of animals are infected with schistosomes, although many have low burdens and are asymptomatic. Severe outbreaks due to heavy infection is reported occasionally (Susan et al., 1998). It is a cyclozoonotic entity, which also affects millions of livestock throughout the tropical and sub-tropical areas. It has been recognized as an important disease of domestic ruminants (Vegila and Le Roux, 1929). This disease is caused by hypersensitivity reactions against worm eggs trapped in the venules (Hirata et al., 1993), producing anaemia, diarrhoea, abdominal pain and sometimes death (Rabello et al., 1994).

*S. mansoni* remains endemic in parts of Brazil, Venezuela, and the Caribbean. The majority of the *S. haematobium* infection is found in sub-Saharan Africa. *S. japonicum* infection still occurs in China, Indonesia, and the Philippines, despite substantial and largely successful control measures (Chitsulo et al., 2000). Pakistan and India have had contacts for centuries with countries such as Japan, China and Egypt, all of which have endemic human schistosomiasis (*S. japonicum*, in Japan and China, *S. mansoni* and *S. haematobium* in Egypt). Parasitic diseases generally present a major health problem specially in developing countries. However, the human urogenital tract is commonly infested by a few species of parasites. One of them is *S. haematobium*, not found in Pakistan, is a digenetic blood fluke that causes severe and varied urinary tract pathology. Evaluation of such pathology warrants careful history taking, eliciting patients

geographic origin or his exposure in an area endemic for a particular parasite (Khalid and Mahmood, 2001).

### **Histopathological findings**

Eggs laid by worms living in the mesenteric veins are trapped in the venules of various organs and these release antigens that produce varying degrees of tissue lesions. Among the affected organs, liver, intestines and spleen are the major sites of egg depositions in human schistosomiasis (Hirata et al., 1993). The liver biopsy showed mild dilation of sinusoid, with a foreign body granulomatous reaction in the lobules. The granuloma comprised of eosinophils, neutrophils and a few mononuclear cells around the eggs of *S. mansoni* which were oval shaped with a prominent lateral spine. However, light infections and delayed onset of egg excretion usually prevent detection of eggs in stool. Eosinophilia is conspicuous and constant feature (Khalil et al., 1993). The initial phase of *S. mansoni* infection shows gastrointestinal signs such as liquid or party diarrhoea, abdominal pain, hepatomegaly, dysentery, anorexia, pain on colon palpation and nausea/vomiting (Rocha et al., 1995). The main intestinal lesions due to *S. mansoni* infection are colonic polyposis, focal fibrosis and inflammation (Nash et al., 1982).

Acute schistosomiasis (Katayama fever) is common in areas of high transmission rates (Sasa, 1972). This phase of the disease is marked by hepatosplenomegaly and eosinophilia usually begins before a large number of eggs have been shed and subsides while increasing numbers of eggs continue to deposited in host tissue (Diaz-Rivera et al., 1957 and von Lichtenberg 1964). Common symptoms include fever, headache, generalized myalgias, right-upper-quadrant pain, and bloody diarrhea (Doherty et al., 1996; Bethlem et al., 1997; Cooke et al., 1999). Haemorrhagic enetritis, anaemia and emiciation, which develop after the onset of egg excretion, are the major clinical signs associated with the intestinal and hepatic forms of schistosomiasis in ruminants (Susan et al., 1998).

Chronic phase of schistosomiasis results from the host's immune response to schistosome eggs and the granulomatous reaction evoked by the antigens they secrete (Boros and Warren, 1970). The intensity and duration of the infection determine the amount of the antigen released and the severity of chronic fibro-obstructive disease. The

granulomas destroy the ova but result in fibrotic deposition in host tissues. Most granulomas develop at the sites of maximal accumulation of eggs—the intestine and the liver (in case of *S. mansoni* and *S. japonicum*) and the genitourinary tract (in the case of *S. haematobium*). However, periovular granulomas have skin, lung, brain, adrenal glands and skeletal muscles (King, 2001). These clinical symptoms may be absent or mild at a time when there is severe abnormality in the lung or liver of the laboratory mice (Garson and Williams, 1957) and rhesus monkeys (Bruce et al., 1962). The most significant lesion in severe chronic infections is marked periportal fibrosis of the liver (Clay pipestem fibrosis or Symmer's fibrosis) associated with splenomegaly and portal hypertension (Suitt et al., 1964; Jordon and Webbe, 1982).

### **Diagnosis**

Diagnosis of acute schistosomiasis depends on the identification of eggs in stool or in liver or rectal biopsy. However, light infections and delayed onset of egg excretion usually prevent detection of eggs in stool (Khalil et al., 1993). In the chronic forms is clinched when the characteristic eggs of the parasitic worm are found in urine or faeces; serological tests are of increasing value (Wilcocks and Manson-Bahr, 1972). Above procedures are laborious, time consuming and biopsies pose a threat to the patient (Pappas, 1988). The faecal examination revealed the presence of disease ranging from 7% to 21% with a mean of 13% infecting both cattle and buffaloes in various groups (Anwar and Gill, 1990). The diagnosis in endemic areas depends mainly on microscopic detection of eggs in stool or urine (Saad et al., 1994).

### **Treatment and control**

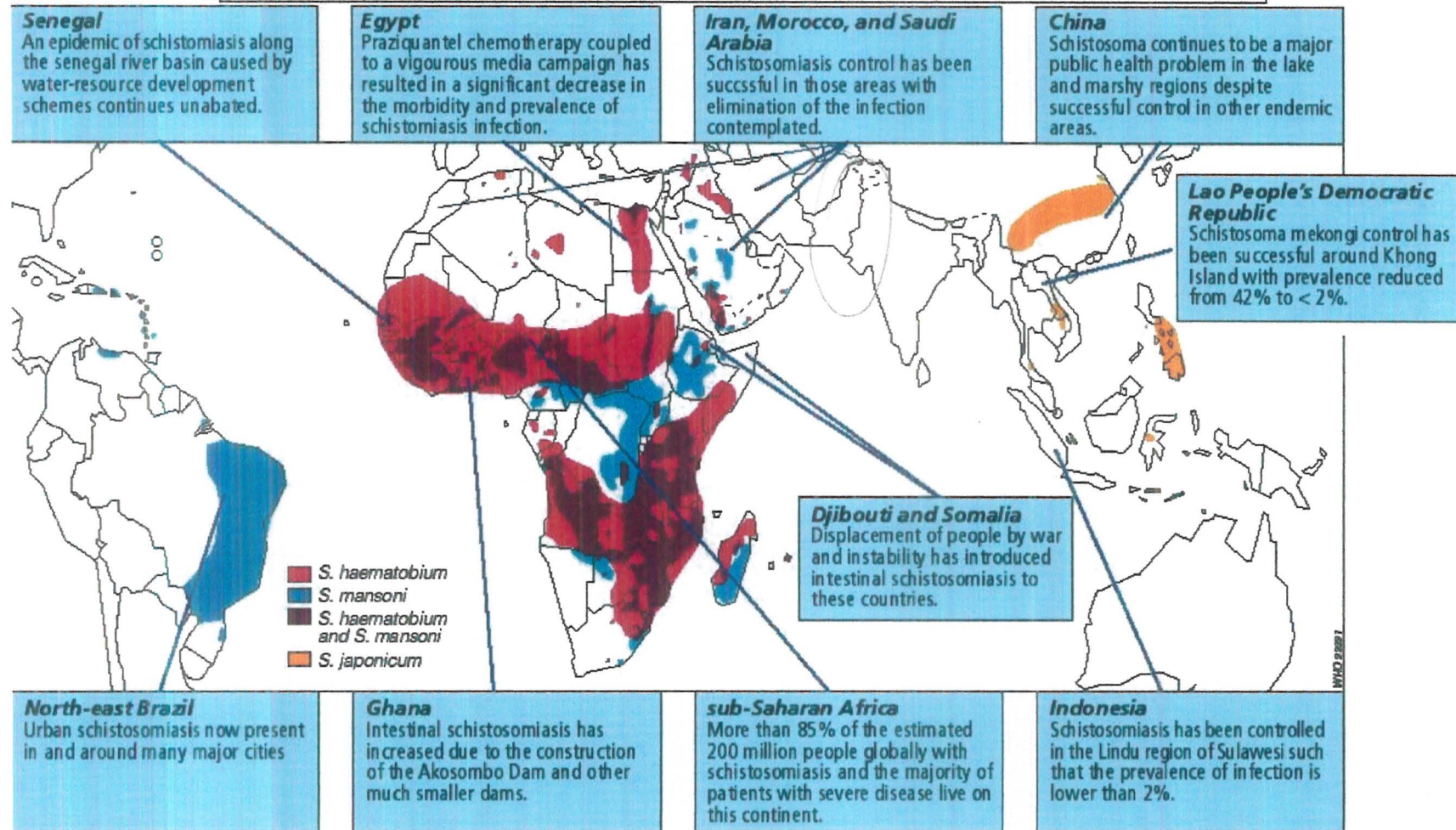
Paraziquental, a pyrazinoisoquinoline derivative, is the mainstay of treatment and a critical part of community-based schistosomiasis control programme. Optimal therapy requires two to three doses of 20 mg per kilogram given six to eight hours apart with food. Community-based control programmes usually treat patients with a single dose of 40 mg per kilogram (Ross et al., 2002). The only accepted prophylactics approach to the prevention of schistosomiasis is the elimination of all direct skin contact with water

infested with schistosome cercariae. Protection from schistosomal infection has been considered from four different perspectives:

- 1) destruction of schistosome-bearing snails,
- 2) elimination of cercariae by cercaricides,
- 3) use of protective fabrics and clothing, and
- 4) application of cercaricidal and/or cercarial repellents to the skin (Pellegrine, 1967).

The global distribution of the schistosomiasis and control programme in several countries of the world (WHO, 1993) are shown in Fig.1. Control of schistosomiasis is achieved by a combination of approaches including health education, water supply and sanitation, environmental management, control of intermediate snail hosts, and effective diagnosis and treatment (WHO, 1989). The best known example of an integrated control programme directed against schistosomiasis, caused by *S. japonicum*, was undertaken in China during the cultural revolution. This involved massive drainage scheme, redirecting waterways, filling-in of infested streams, removal of vegetation and hand destruction of snails, which entirely eliminated the snail, vector from considerable areas. This was accompanied by mass treatment of infected individuals and followed up by encouraging farmers and peasants with financial inducements to look out for snails (Molyneux, 1993).

**Fig.1 Global distribution of the Schistosomiasis (WHO, 1993).**



### **Importance of genus Schistosoma**

Schistosomes are metazoan parasites, which normally reside permanently *in copula* down to the ileocolic and coeliac branches of the superior and inferior capillaries at the mesenteric and hepatic vein of man and livestock (Rollinson and Simpson, 1987). An interesting features of these flukes is that the sexes are separate, the male being an elongate flat worm, with body curved into a longitudinal fold, the gynaecophoric groove, where as the female looks much like a small nematode except for the anterior and ventral suckers, lies (Dunne, 1978). Adults of subclass digenea are internal parasite of vertebrates and complete life cycle in definitive and intermediate hosts (Meglitsch, 1967). After an involved cycle of development in the snail, free-swimming larvae of the worm (cercariae) penetrate skin or mucous membrane of persons swimming or wading in contaminated waters (Jordan and Webbe, 1969). The *S. mansoni* cercariae, young parasites, enter the lymphatic system, then the blood stream, and reach the liver, which is the site of maturation and sexual differentiation (Amer, 1994). Transmission of the disease involves the penetration of the definitive host by the larval stage, cercariae (Newport et al., 1988) and the transformation into schistosomula (Smith and Jones, 1961). The schistosomula enter the blood stream, develop to maturity and migrate to the veins of abdominal organs (Jordan and Webbe, 1969). The population in the final host may unisexual (male or female) or mixed, resulting pairing of male and female, which produces eggs (Cameron and Thomas, 1951). The five species of schistosome which infect man are; *S. mansoni*, *S. haematobium*, *S. japonicum*, *S. mekongi* and *S. intercalatum* (WHO, 1985). There are 18 species of schistosome that can infect mammals but the successful out come of infection is dependent on the relation ship between parasite and its host.

### **Schistosomes found in Indo-Pakistan subcontinent and other regions of world**

Schistosomes are the blood flukes that parasitize humans, cattle, buffaloes, sheep, goats, dog, equine and variety of other animals. Besides in above mentioned regions and other areas of the world, various species such as *S. haematobium*, *S. indicum*, *S. spindalis*, *S. nasalis*, *S. incognitum* (Dunne, 1978; Urqhart et al., 1987), *S. bovis* are found in buffaloes in Punjab Pakistan (Anwar, 1982) and *S. mansoni* was found in a girl

in Karachi Pakistan (Khalil et al., 1993). The distribution of these schistosomes are as under.,

1) *S. haematobium* specie was discovered by Bilharz (1852) in intermediate snail host genera *Bulinus* in continental distribution in Africa and adjacent regions (Fig. 1). The mammalian order contains primate such as *Papio ursinus* (Chacna baboon) which may act as the definitive host. The geographic range is from Southern Europe (sporadically in Portugal, Spain and Cyprus), through the Middle East and Africa (from the Nile Delta to the South), to Indo-Pakistan and Burma (Dunne, 1978).

2) *S. indicum* specie was discovered by Montgomery (1906 a) from equine and infects variety of domestic animals on the Indian sub-continent. The eggs are oval and possess a terminal spine. This parasite resides in portal and mesenteric veins of ruminants, including the camel and the equine in Indo-Pakistan. Rodents are experimentally susceptible; the geographic range is from southern Europe (sporadically in Portugal, Spain, and Cyprus), through the Middle East and Africa (from the Nile Delta to the South), to Indo-Pakistan and Burma. This parasite is found in ruminants, occasionally in horses and dogs in Africa, Indo-Pakistan, Thailand, former Indo-Chinese countries and Indonesia (Dunne, 1978).

3) *S. nasalis* describe first by Rao (1933) is responsible for nasal schistosomiasis or snoring disease in cattle, sheep and goats. The adult worms are found in the veins of the nasal mucosa. The eggs are large and distinctive with a terminal spine. This parasite also infects horses in India and Pakistan (Urqhart et al., 1987). In India *S. nasalis* has been reported from Andhrapardesh (Rao and Murthy, 1964; Christopher and Rao, 1975; Sreeramula, 1982), Bihar (Varma, 1954; Sahay and Sahai, 1978) Karnatak (Naik, 1942; Rao and Naik, 1957; Muraleedharan et al., 1976 a,b,c). *S. nasalis* is relatively more prevalent and cause nasal granulomatous in cattle and buffaloes (Southgate and Agrwal, 1990).

4) *S. spindalis* specie was discovered by Montgomery (1906 b) from the portal and mesenteric veins of small and large intestines of cattle of Muktesar, India and now this parasite is found in Srilanka, Indonesia, Malaysia, Thailand and Vietnam. The parasite is found in ruminants, and occasionally horses and dogs, in Africa, Indo-Pakistan, Thailand, and the former Indo-Chinese countries, and Indonesia (Dunne, 1978). This parasite also



infects horses, and Pigs in Asia and the Far East (Urqhart et al., 1987). It causes schistosomal dermatitis in man. The cattle may show sub-clinical symptoms, but in severe infections, anaemia, diarrhoea and oedema may develop; occasional mortality has been recorded.

5) *S. incognitum* specie was described by Chandler (1926), who observed sub-terminal spined eggs in the samples of human stool in Bengal, India and Pakistan. The eggs are sub-oval in shape with one side comparatively flattened and the spine is short. Pig, sheep and dogs are naturally infected (Urqhart et al., 1987).

6) *S. bovis* specie was discovered by Sonsino (1876) and occurs in genera *Bulinus*, *Planorbium* and *Artiodactyla* in Africa. This is specially true in Sudan where 90% of infection occurs in 18 months age of cattle and is serious veterinary problem in the Mediterranean region, Middle East, Asia and southern Europe. The adult worms were found in the mesenteric veins of the intestine, bladder involvement appears in sheep suffering from a very heavy infection (Hussein et al., 1984 and Urqhart et al., 1987). In a survey study 12% of the cattle and buffaloes were positive with *S. bovis* in Rabwa city and its surroundings in Punjab, Pakistan (Anwar, 1982). The experimentally infected animals develop mucoid followed by diarrhoea and become dull and depressed. Packed cell volume and haemoglobin concentration of the infected animals showed progressive reductions when compared with uninfected controls. The animal were found necropsied and perfused at 12 weeks post-infection (WPI), and tissue egg densities and worm burdens was found to be 245n 215/g in the liver, 1133n 428/g in the small intestine and 758n 516/g in the large intestine. The mean worm burden was 3000 (Aradaib et al., 1995).

7) *S. mansoni* (Sambon, 1907). This specie lives in the blood vessels of the walls of the large intestine of man and causes the disease called intestinal schistosomiasis. It occurs in the Nile Delta and elsewhere in Africa, including South Africa, but in the Yemen region of Arabia (Fig. 1). In South America it occurs in Brazil, Venezuela and the lesser Antilles (Lapage, 1968). The infection is characterised by cutaneous lesions, diarrhoea with blood and mucus, hepatitis, anaemia and emaciation (Faust et al., 1968).

In the Indian sub-continent several species of fresh water mollusc are found including *Indoplanorbis exustus*, *Lymnaea luteola*, *Paludomus obesa*, *Ferressia tenuis*

and *Melanoides tuberculata*. Gadgill and Shah, (1995) expressed numerous snail species to miracidia originating from a patient with urinary schistosomiasis (*S. haematobium*) from Ginvi village of India and the only specie they found to shed schistosome cercariae despite heavy mortality, was the very small ancyliid snail, *F. tenuis*. In an examination of 1200 *F. tenuis* Sathe and Remapuker, (1983) found only 12 specimens to be infected with schistosome cercariae. Pathan, (1999) conducted his research work on the chemical control of schistosome susceptible intermediate host in and around Tando Jam and reported that 7% of the snails were shedding schistosome cercariae. However, the species of the genus *Schistosoma* was not known. Sahito, (2002) has done work on the laboratory screening of the schistosome susceptible intermediate snail host of *Biomphalaria* (*B*) specie. The snails were collected from lentic and lotic waters of 14 different areas from Taluka Tando Allahyar. This study revealed that 2.31% snails were naturally infected with schistosome cercariae. In order to identify the species of schistosome, the cercariae collected and pooled from infection-positive snails, were introduced to infection-free mice. The mice were left for 45 days to develop infection properly. The post-infection examination revealed that 25% mice developed infection. The microscopic examination of shape and size of eggs confirmed the *S. bovis* infection. On this evidence it is generally assumed that this specie is responsible for the transmission of disease.

Because potential intermediate host for disease is widely distributed through out India and Pakistan, and in both countries dams and man-made lakes are under construction in order to generate hydroelectric power, hence there may be new opportunities for the spread of this water-borne disease in the region.

There are some reports about prevalence of schistosome of veterinary importance in Pakistan and India. *S. haematobium* shaped eggs were reported in the urine samples of about 250 people of Gimvi village of India (Gadgill and Shah, 1952). The terminal spined schistosome eggs were reported from two stool and two urine samples originating in the environs of Dokur, Andhra Pardesh, India (Bidinger and Crompton, 1989). *S. indicum*, *S. spindalis*, *S. nasalis* from various localities of Punjab province of Pakistan were reported by Abdulssalam and Sarwar (1953). A total of 20,000 animals were examined from different localities of Punjab province of Pakistan and 13% cattle and buffaloes were infected with *S. indicum* and *S. bovis* (Anwar and Gill, 1990). A case of



*S. mansoni* infection has been diagnosed from a 7 years old girl from Karachi, Pakistan. The patient was a non-vegetarian and had no pets at home, nor had she travelled to any other region in the recent past (Khalil et al., 1993). Aradaib et al., (1995) reported a study in five experimentally infected Zebu calves with 30,000 cercariae of *S. bovis* while three calves were left un-infected as control. After five weeks post-infections animal were passing eggs in the faeces. The faecal egg count was found at peak between seven and nine week post-infection.

### **Life cycle of schistosome in general**

During the course of the life cycle of the blood fluke, *S. mansoni*, the various larval stages are exposed to a wide variety of environments ranging from a free-living aquatic one to one restricted to the tissues of its hosts (Bogitsch, 1975). The blood flukes produce non-operculated eggs, and are excreted by the host in faeces, or in the urine. The fertilized eggs hatch in water, ciliated larva miracidia emerges within a few hours (Faust et al., 1968). When the eggs of *S. mansoni* come in contact with the water, the enclosed miracidia breaks out of the shells by cracking them (Smith et al., 1975; Bloch, 1980). As soon as the miracidium has reached a suitable intermediate host snail the cycle can continue (De Marijke, 1995). The free-swimming miracidium finds and penetrates a suitable pulmonate snail, usually *B. glabrata*, and transform into mother sporocyst, which is located in the region of the host's head-foot or in the tentacles and mantle of the animal (Faust et al., 1968; Smith et al., 1975; Bloch, 1980). The miracidium transforms near the site of penetration and develops within 48 hours into saccular mother sporocyst. The embryos of daughter sporocyst soon develop in the body of the mother sporocyst, which escape into tissues of the snail by rupture of the wall of the mother sporocyst, make their way to the digestive glands, grow and give rise to next stage in the life cycle, the cercariae (Faust et al., 1968). It has been estimated that *S. mansoni* may produce in this manner an average of 3500 infective cercaria every day, all of which have been derived from a single fertilized egg; the total number of cercariae thus derived from a single, fertilized egg may be, in a period of months, 100,000-250,000 (Lapage, 1968). The complete life cycle requires 8 to 12 weeks; adult worms sometimes live for 20 to 30 years (Faust et al., 1968).



### **Developmental stages in the intermediate host snails of *B. glabrata***

The *S. mansoni* miracidia breaks out of the eggshells by cracking them and penetrated head-foot, tentacle or mantle of the snails of *B. glabrata*. The ciliated surface of the miracidium disappears and develops into mother sporocyst (Smith et al., 1975; Bloch, 1980). The development takes place only if the appropriate species of snail has been entered, otherwise the miracidium is destroyed by phagocytic action (Pan, 1965). In *S. mansoni* majority of mother sporocysts develop at the penetration point, normally in the subepithelial conjunctive of the cephalopodal zone with a preference for the lateral edges of the anterior third of the foot (Jourdane, 1982). Mature mother sporocysts are usually located in the foot and survive longest in the tissues of the head-foot, tentacle, pseudobranch and mantle collar (Pan, 1965). The sporocysts are sac-like organisms, which rely on absorption of their nutriment through their outer cuticle layer or tegument (Wright, 1966 a). The sporocyst tegument surface, which forms within a few hours after penetration interact with the host hemolymph (Bayne and Hull, 1988). The tegumental surface of the primary mother sporocyst of *S. mansoni* serves as an important interface for molecular communication between the parasite and molluscan intermediate host *B. glabrata* (Johnston and Yoshino, 1996). The tegument also serves as main target for the snail's internal defence system, in which circulating blood cells or hemocytes recognize, encapsulate or destroy incompatible schistosome larvae soon after invasion innately resistant snail hosts (Bayne and Yoshino, 1989; Loker, 1994; Yoshino and Vasta, 1996). After 8 days the mother sporocyst appears to have grown considerable into a non-motile convoluted tube into a globular shape (Pan, 1965). The embryos of daughter sporocyst soon develop in the body of mother sporocyst, which escapes into the tissues of the snail by rupturing the wall of the mother. The daughter sporocyst migrates to the digestive glands, where they grow and give rise to the next stage in the life cycle, the cercariae (Dawes, 1946, Cameron and Thomas, 1951, Faust et al., 1968). The first phase is concerned with normal development of *S. mansoni* cercariae within daughter sporocyst embedded in the digestive gland of *B. glabrata* (Cheng, 1973). Some developmental studies have been already done on the above stages of the parasite in different species of the snail (Meglitsch, 1967; Robson and Erasmus, 1970; Rifkin, 1971; Meuleman, 1972; Schutte, 1974 b).

### **Effects of *S. mansoni* on the intermediate host *B. glabrata***

The course of normal, compatible infection of *S. mansoni* in *B. glabrata* is as follows. The first signs appear almost five days after miracidia have penetrated when mother sporocysts have grown and caused local occlusion of blood sinuses, resulting in superficial swellings and, in deeper tissues, translucent patches due to accumulations of blood (Pan, 1963). Invasion of the molluscan host may occur either by active penetration of free-swimming miracidia or by ingestion of eggs, which will hatch only in the gut of appropriate mollusc. Establishment of the miracidium leads to its transformation into a mother sporocyst within which subsequent production of daughter sporocyst occurs. The outer cuticle layer of the sporocyst is also capable of active ingestion of tissues (Wright, 1966a). No further significant changes occur until after the daughter sporocysts have left the mother sporocyst, migrated to the digestive gland and matured. This leads to congestion of the blood sinuses in the visceral mass, especially around the stomach, and this in turn causes an oedematous condition of the head-foot region, which probably helps the subsequent escape of cercariae. At this stage there may be some activity of hypertrophic fibroblasts in the connective tissue of the digestive gland surrounding the daughter sporocyst, and congested arteries also contain slightly hypertrophic hemocytes, probably derived from the "lymphoid" tissue in the mantle (Pan, 1963). The histopathology of infected gastropod digestive glands show at the beginning of cercarial emergence there is increased activity of the snail connective tissues and hemocytes with a rapid rise in the number of hypertrophic fibroblasts. This activity is most pronounced in the presence of cercariae and particularly where emboli are formed in the vessels by groups of larvae. By this time the blood vessels contain large numbers of hypertrophic hemocytes which are larger than those normally present and the walls of the vessels become thickened by hyperplasia of the linings. Where cercariae become trapped in the tissues they are surrounded by hemocytes; those nearest to the larvae remain amoeboid while those further out appear to transform into fibroblasts and become concentrically arranged. Lysis of the cercariae follows and most of the debris is taken up by the hemocytes. Granulomata of this type are formed around cercariae which become trapped in any type of tissue and they are often visible in the living snail as small, opaque nodules which eventually disappear, probably due to resorption (Wright, 1966 a,b,c,d). The

susceptibility of the mollusc to trematode infections has shown to be affected by the sexual condition and age of the snail host (Lo, 1972; Richards, 1984). Susceptible snails are those which allow successful schistosome development and emergence of the cercariae (Lie et al., 1977). The present study was designed because of less information available on the intramolluscan development of *S. mansoni* and host responses in the various organs of the susceptible, resistant and Giant snails *B. glabrata*.

# CHAPTER NO.1



**Histological studies of post penetration by the miracidia of *Schistosoma mansoni* into the snails of *Biomphalaria glabrata*.**

**Abstract**

Comparative histology of three groups of the snails (50 susceptible, 55 resistant and 3 giant) of *Biomphalaria glabrata* have been studied for the development of the mother sporocyst (MS) after 1-10, 30 and 40 DPE. After penetration by *Schistosoma mansoni* miracidia (MI) detailed histological examination of various organs of the susceptible snails showed normal development of MS from 1-10 DPE. MS were visible in the foot, head, lips, tentacles, mantle, anus and buccal mass of the susceptible snails after 1-4 DPE. The beginning of the migration of the MS was observed at 3 and 4 DPE in the mantle, muscles of the anus and buccal mass of the susceptible snails. At 5 DPE some broad, few irregular, thin, elongated MS were observed in the above mentioned organs, neck and reached in the kidney of the susceptible snails. The next step of the migration of the MS was observed in the kidney at 5 DPE. From 6 DPE and onwards within the body of the mature MS embryos of the daughter sporocysts (DS) were found in the foot, head, lip, tentacles, mantle, kidney and esophagus of the susceptible snails. After 8 DPE in the foot, head, and lip of the susceptible snails within the body of the mature MS few embryos of the DS ruptured tegument and migrating towards deeper organs. After 9 and 10 DPE MS are visible in the pericardial cavity of the heart (1) and respiratory epithelium of the lung (3) of the susceptible snails. In resistant snails MS were located in the foot, head, lip, tentacles, mantle, anus, buccal mass, neck and columellar muscles from 1-10 DPE. Single MS were observed in the foot, head, lip, tentacles, mantle, neck, anus and buccal mass of the snails throughout infection period. While multiple MS were only visible in the tentacle and columellar muscles of the resistant snails after 9 DPE. The migration of the MS was noted in the neck, anus and columellar muscles of the snails after 3, 5 and 9 DPE respectively. No any further migration or mature MS was observed in these snails.

During infections four types of the MS (single, multiple, mature and migratory) were recognized in the various organs of the susceptible snails. Among all infected organs the highest total number of the 24 single and 189 multiple MS found in the head and foot of the susceptible snails respectively. These MS were also increasing in the other organs such as, tentacles, (21 and 77), lip (9 and 49), neck (1 and 42), buccal mass (2 and 16) and anus (1 and 12) of the susceptible snails. The highest total number of the mature and migratory MS was recorded in the foot (24 and 3), head (7 and 1), and tentacle (6 and 1) of the susceptible snails. The highest number 14 of the embryos of the DS was recorded in the mature MS found in the foot of the susceptible snails. In the resistant snails highest total number of the single and multiple MS found in the tentacles (12 and 3). In the foot of these snails highest number of the single MS was 11 and 8 multiple MS were visible in the columellar muscles of the snails. Chi-square test results shows highly significant difference in between the overall infected organs of the susceptible and resistant snails ( $\Sigma X^2_{(1)} 21.58, P < 0.001$ ).

In the foot, head, lip and tentacles of the susceptible snails the body of the MS was characterized by thin tegument with cells, some germinal cells contained scanty cytoplasm, nuclei with prominent nucleolus, muscles, vacant spaces, apical gland and penetration glands at 1-2 DPE. The muscle cells of the tegument are lightly stained. The nuclei and nucleoli of the muscles and germinal cells are darkly stained. Penetration glands and neural mass are pink in color. At 2 DPE single MS further grow and become multiple at 3 DPE and onwards in the foot, head, lip, tentacles, anus and mantle of the



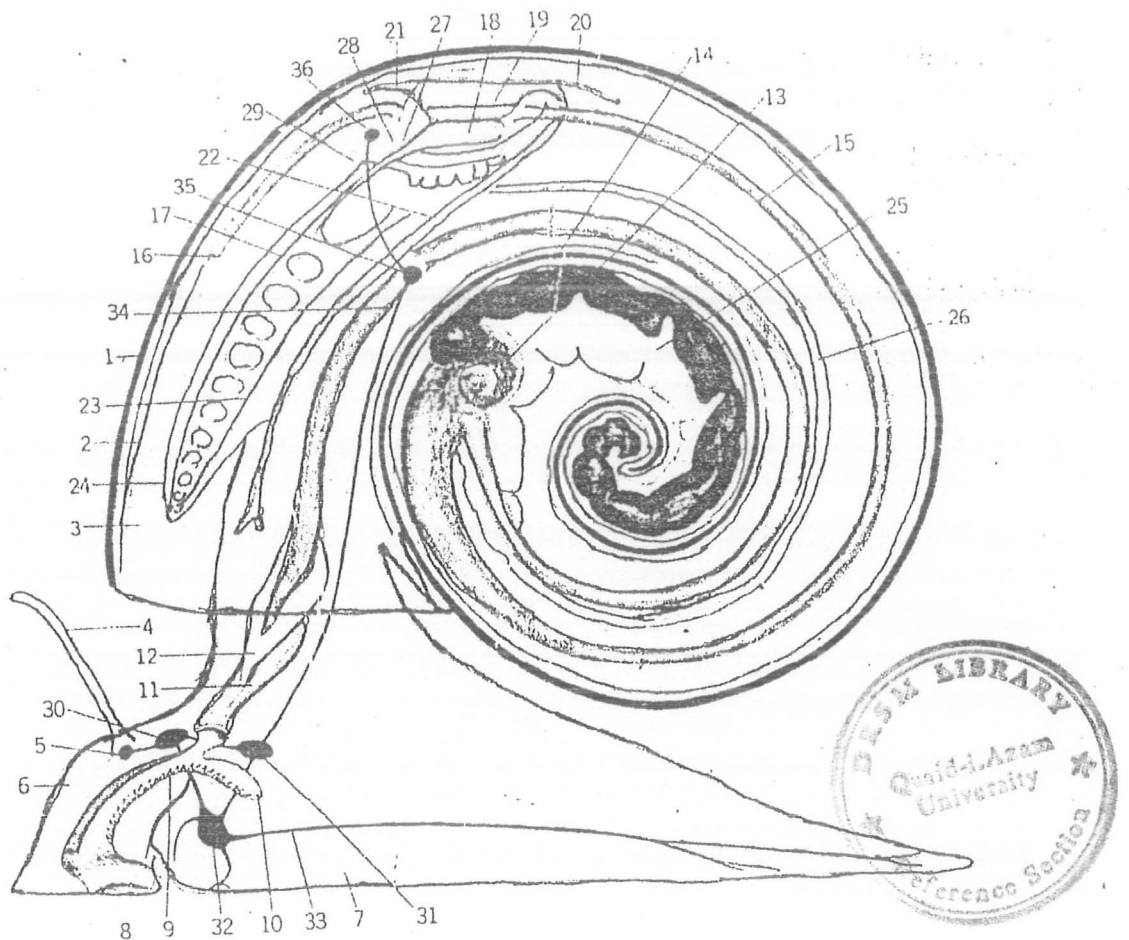
susceptible snails. The structure of the single and multiple MS is similar as mentioned above. After 5 DPE great proliferation of the germinal cells increased their number and size so that they occupy practically entire body of broad MS. The highest mean ( $\pm$  SEM) number of the germinal cells of MS present in the tentacle is  $30.6 \pm 6$  from 1-5 DPE. The germinal cells as they increase in size have increased amount of cytoplasm and their nuclei are with prominent nucleoli. The germinal cells spread or distribute to form few clusters and masses of large numbers of these cells and developed embryos of daughter sporocyst (DS) inside the body of the mature MS. The highest mean ( $\pm$  SEM) number of germinal cells in the embryos of DS within the body of mature MS is  $30 \pm 5.51$  at 6 DPE. In the head and lip of the susceptible snails DPE few embryos of the DS ruptured tegument and migrated towards deeper organs after 8 DPE. In the resistant snails development of the MS is characterized by tegument, vacant spaces, prominent penetration glands, few germinal cells had nuclei with nucleoli and little cytoplasm. Very few MS exhibits thin tegument, dark nuclei of germinal cells, increased vacant spaces, spread penetration gland and surrounded by hemocytes reaction. The highest mean diameter of the single MS found in the head susceptible snails ranges between  $37.65 \pm 5.55 \mu\text{m}$  and  $99.75 \pm 9.38 \mu\text{m}$  from 1-10 DPE. In the foot of the susceptible snails the highest mean diameter ( $\pm$  SEM) of the mature MS and embryos of the DS was  $256.72 \pm 14.89 \mu\text{m}$  and  $80.68 \pm 4.89 \mu\text{m}$  respectively. In the foot of the resistant snails mean diameter ( $\pm$  SEM) of the single MS ranges between  $48.08 \pm 2.15$  and  $92.91 \pm 18.53 \mu\text{m}$  during the infection. The giant snails had white patches on the regions of the ventral surface of the foot and selected for gigantism. In the posterior surface of the foot multiple MS were surrounded by strong hemocytes and mature MS containing embryos of DS after 30 DPE. In later infection at 40 DPE MS were visible in the most of the above organs of the resistant snails, mantle rim, mantle cavity, radula, kidney, respiratory epithelium of the lung, shell epithelium, salivary glands, hemocytes producing organ and albumin glands. MS was single in the foot, head, tentacles, buccal mass, neck, radula, and hemocytes producing organ. While increasing numbers of the multiple and mature MS were visible in the anus, mantle, kidney, respiratory epithelium of the lungs and albumin glands of the animals.

## 1.1 Introduction

*Biomphalaria glabrata* is the most prevalent vector of the schistosomiasis due to the high levels of compatibility and susceptibility to the parasite (Souza et al., 1995). Schistosomiasis is commonly thought of as a disease of vertebrates. Schistosomes require a molluscan intermediate host in which they not only undergo a series of developmental stages but also asexual reproduction (Cheng and Bier, 1972). Several different host-parasite interactions occur with different combinations of *B. glabrata* stocks and *S. mansoni* strains (Sullivan and Richards, 1981). These interactions are influenced by genes of the snails that control susceptibility and genes of the parasite that determine infectivity. Some gene combination allows the parasite to develop and proliferate because the snail fails to recognize it as foreign (Lewis et al., 1993).

*B. glabrata* is the intermediate host for the human pathogen *S. mansoni* (Fig. 2). It is often found very close to the surface of the water either fixed in floating vegetation or on the upper banks of canals and lakes (Jourdane and Theron, 1987). During the course of its life cycle, *S. mansoni* goes through distinct stages of differentiation. The miracidial stage may be considered a recapitulation of the ancestry of the adult forms (Bogitsh, 1975). As soon as the MI has reached a suitable snail the cycle can continue (De Jong-Brink, 1995). *S. mansoni* MI are attracted by water in which *B. glabrata* snails have been kept and penetrate to the body surface of snails by lytic enzymes secreted from the apical glands or the gut (Wajdi, 1966). MI remains infective to their snail *B. glabrata* host for about 8 to 12 hours (hrs) at temperatures between 24 to 28 °C (Fig. 3). MI actively searches for the snail *B. glabrata* and penetrates the skin of mantle or head-foot area within a few hrs (Prah and James, 1977). The penetration ability of MI can vary greatly depending on the snail-parasite combination (Kassim and Richards, 1979). When the penetration process is completed, development of MS takes place at the penetration point (Basch, 1976). Only a small proportion of the *S. mansoni* MI that enters the *A. glabratus* host and develop to mature MS (Pan, 1965).

Morphological features of host/parasite relationship have been specially studied in *B. glabrata* submitted to infection with *S. mansoni* MI (Newton, 1952, Barbosa and Barreto, 1960, Pan, 1965). Broadly speaking MS are sac-like organisms which rely on absorption of their nutrient through outer tegumental layer (Wright, 1966 a). MS are present in the skin surfaces of snails, 24 hrs or more after penetration. Most MS become elongated and have very thin tegumental wall at 48 hrs. After 96 hrs the body of MS is



**Fig.2 Scheme of organization of Biomphalaria snail.**

**External feature:** 1) shell; 2) mantle; 3) mantle cavity; 4) tentacle; 5) eye; 6) head; 7) Foot.

**Digestive tract:** 8) mouth; 9) radula; 10) radular sac; 11) esophagus; 12) salivary glands; 13) stomach; 14) digestive gland; 15) intestine; 16) anus.

**Circulatory system:** 17) efferent branchial vessel; 18) auricle; 19) ventricle; 20) Posterior aorta; 21) anterior aorta; 22) cephalic artery; 23) afferent branchial vessel; 24) gill.

**Urogenital system:** 25) ovotestis or gonad; 26) gonoduct; 27) nephrostome; 28) Reno pericardial canal; 29) nephridiopore.

**Nervous system:** 30) cerebral ganglion; 31) pleural ganglion; 32) pedal ganglion; 33) Pedal nerve trunk; 34) visceral nerve; 35) parietal ganglion and 36) visceral ganglion.

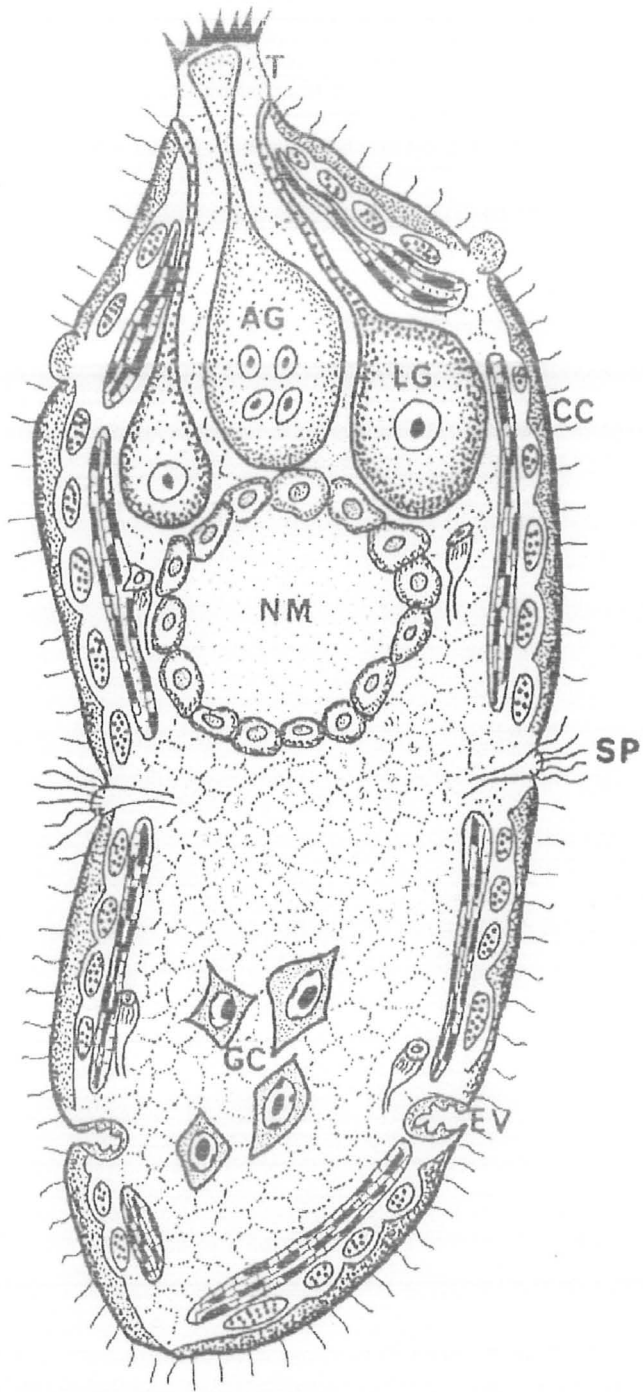


Fig. 3 A schematic cellular architecture of the miracidium of the *Schistosoma mansoni* (Jourdan and Theron, 1987): AG, Apical gland cell; CC, ciliated cell; EV, excretory vesicle; GC, germinal cell; LG, lateral gland cell; NM, neural mass; SP, sensory papilla.

almost filled with germinal cells and small centrally placed vacuoles (Pan, 1965). After 3 days post-exposure (DPE) multiplication of MS has taken place, it is composed of a closely packed mass of cells which are only to be distinguished from the surrounding tissues of the tentacle with some difficulty (Gordon et al., 1934). During the development of *S. mansoni* in *B. glabrata* it seems evident that number of MS can develop simultaneously in a single snail (Schutte, 1974 b). At the end of the first week proliferation of the germinal cells is so great that it comes to occupy practically the entire body cavity (Wajdi, 1966). After 7 DPE the first stage of development, there is a local multiplication of sporocyst; this is followed by migration of motile sporocysts, which are sometimes observed exuding from the base of the tentacle. The motile sporocysts are sausage or cigar shaped hyaline bodies and composed of cells with finely granular protoplasm (Gordon et al., 1934). MS grown considerably; appearing in most instances convoluted tubes coiled into a globular shape after 8 DPE (Pan, 1963). The larger MS have about 5 convolutions after 8 DPE (Pan, 1963). Histological examination of many sectioned susceptible snails revealed that small sporocysts could occasionally be found in the tentacles and sometimes found in "blisters" near the surface of the foot from 7-10 DPE (Lewis et al., 1993). The adult schistosome is different from the sporocyst structure or function (Kinoti et al., 1971). The adult parasites are dorsoventrally flattened, bilaterally symmetrical without a coelom (body cavity), definitive anus, circulatory, respiratory, skeletal system, flame bulbopronerphidia and connective tissues filling all spaces between organs and systems (Hyman, 1951). Whereas, the sporocysts lacks an alimentary canal, reproduces parthenogenetically and is completely sessile when mature (Kinoti et al., 1971).

## 1.2 Aims and objectives of present work

To determine the involvement of the number of organs with MS, and percentage of the infected susceptible and resistant snails.

To determine the locations, number of various types of the MS in the susceptible and resistant snails.

To study the migration and development of the MS in the susceptible and resistant snails.

To determine the mean diameter of the various types of the MS in the susceptible and resistant snails.

### 1.3 Materials and methods

#### 1.3.1 Source of materials

Selected pigmented resistant and unselected susceptible ordinary (Albino) snails of *B. glabrata* the intermediate host of *S. mansoni* were studied for development of the parasite. Each group comprised of 150 snails and mean diameter of shell of 300 animals of both groups used in this study was  $10.22 \pm 0.068$  and  $9.0 \pm 0.06$  mm respectively. In the both experiments animals were twice mass exposed with freshly hatched MI obtained from the livers of mice. In the first experiment a total of 50 + 55 susceptible and resistant snails were histologically processed from 1-10 and 40 days post-exposure (DPE). In the second experiment only three giant snails with spotty feet syndrome were infected up to 30 DPE. All the infected snails were processed histologically under the supervision of late Dr. N.W. Runham, in the histology laboratory, School of Biological Sciences, University of North Wales, Bangor United Kingdom in 1997.

#### 1.3.2 Methods

The infected snails were relaxed in 0.4% Nembutal anesthesia (Abbot laboratories) for 8-24 hours. Relaxed animals were fixed in Heidenhain's Susa fixative until shell became transparent. The shell of the animals was carefully removed without any damage of the tissues of the snails with artery forceps under dissecting microscope. For histological studies, snail bodies were dissected in to two portions (anterior areas include head-foot, tentacles, and anterior mantle cavity, and posterior portion consists of digestive glands and ovotestis). The animals were dehydrated in graded alcohol, infiltrated and embedded in historesin. Four  $\mu\text{m}$  thick serial sections were cut with a glass knife from animals using 5 repeats on every day. The slides were stained using polychrome method (Blackstock, Pers. comm.). The stained slides were mounted with DPX and a coverslips and dried on hot plate over night. Finally, the stained slides were interpreted on a light microscope. Detailed histological examination of the tissues of the snails and larval stages of the parasite was performed on serial sections. The size of the parasite found in the various organs of snails was estimated by measurements of their length and width with an ocular micrometer. The diameter of the MS (single, multiple and mature) and embryos of DS was obtained by at 3-5 random sections covering the parasite. Where ever single MS was not present in any organ length and width of the larger organism was measured from the multiple MS.



#### 1.4 Results

The results obtained in the present comparative study were made from the equal number (5+5 on each DPE) of the susceptible and resistant snails from 1-10 DPE. Additionally, 3+5 giant and resistant snails at 30 and 40 DPE respectively were also included. After exposing snails to *S. mansoni*, MI penetrated different organs of the susceptible and resistant snail's body. The development of the MS appeared in the various organs of the 41 susceptible and 32 resistant snails. The distribution of the MS in both the groups of snails is presented in Table No.1.1. In few susceptible and some resistant snails MS and host responses (multiple infections) were found. However, in majority of the animals either MS or host responses were developed. The MS appeared in maximum number 9 of the susceptible snails on 5, 6, and 8 DPE. MS were present in the foot, head and tentacles of the susceptible snails from 1-10 DPE. The overall appearance of MS in the various organs was also recorded higher number in the susceptible (12) and lower in the resistant (9) snails. Whereas, the maximum number (5) of the organs of the resistant snails on 9 DPE. The range of the percentage of the susceptible was 40 to 100% and in the resistant snails were 40 to 80%. The percentage and organs involvement was higher in the susceptible than resistant snails.

After detailed histological observations, MS found in the following organs of susceptible and resistant snails. Such as., in the foot, head, lip, tentacles, mantle, anus, buccal mass, neck, kidney, esophagus, respiratory epithelium of the lung and heart of susceptible snails from 1-10 DPE. In the susceptible snails some single, many multiple (branching), mature and migratory MS (development of the embryos of DS) were observed after 1, 3, 6 and 8 DPE respectively (Table Nos. 1,2,4,6,8, and 10). However, MS remained visible in the foot, head, lip, tentacles, mantle, neck, anus, buccal mass and columellar muscles of the resistant snails from 1-10 DPE. Whereas, in the resistant snails few single MS were visible in the organs mentioned earlier throughout infection except at 9 DPE few multiple MS were found in tentacle and columellar muscles of these snails. The chi-square test shows highly significant differences on over all infected organs among susceptible and resistant snails ( $\Sigma X^2_{(1)} 21.58, P < 0.001$ ) (Table No. 1.1.1). In later infection after 40 DPE MS were also observed in the last four organs plus mantle cavity, shell epithelium, radula, esophagus, salivary glands, lung, kidney, heart, hemocyte producing organ and albumin glands of the of these snails. In the foot of the giant snails few multiple and mature MS were visible in the posterior surface of the foot at 30 DPE.

Table No.1.1 Distribution of the mother sporocysts in the various infected organs among susceptible and resistant snails of *Biomphalaria glabrata* mass exposed to miracidia of *Schistosoma mansoni* over a period of 10 DPE.

DPE	Snails	Experimental snails	Positive	Percentage (%)	Infected organs												
					Foot	Head	Lip	Tentacle	Mantle	Anus	B.mass	Neck	Kidney	Espg	Cm	Heart	Lung
1	S	5	5	100	+	+	+	+	-	-	-	-	-	-	-	-	-
	R	5	4	80	+	+	-	+	-	-	-	-	-	-	-	-	-
2	S	5	4	80	+	+	-	+	-	-	-	-	-	-	-	-	-
	R	5	4	80	-	-	-	+	-	-	-	-	-	-	-	-	-
3	S	5	5	100	+	+	+	+	+	+	-	-	-	-	-	-	-
	R	5	4	80	+	+	-	+	-	-	-	+	-	-	-	-	-
4	S	5	5	100	+	+	+	+	-	-	+	-	-	-	-	-	-
	R	5	3	60	+	-	-	+	-	+	-	-	-	-	-	-	-
5	S	5	5	100	+	+	+	+	+	+	+	+	+	-	-	-	-
	R	5	4	80	+	+	-	+	-	-	+	-	-	-	-	-	-
6	S	5	5	100	+	+	+	+	+	+	+	+	+	-	-	-	-
	R	5	4	80	+	-	-	-	+	-	-	-	-	-	-	-	-
7	S	5	2	40	+	+	-	+	+	-	-	+	-	-	-	-	-
	R	5	3	60	-	-	-	+	-	-	+	+	-	-	-	-	-
8	S	5	5	100	+	+	+	+	+	+	+	+	-	+	-	-	-
	R	5	-	-	-	-	-	-	-	-	-	-	-	-	-	-	-
9	S	5	2	40	+	+	+	+	-	+	+	-	-	-	-	+	-
	R	5	2	40	+	+	-	+	+	-	-	-	-	-	+	-	-
10	S	5	3	60	+	+	-	+	+	-	+	+	+	-	-	-	+
	R	5	4	80	+	+	+	-	+	-	-	-	-	-	-	-	-
Total	S	50	41		10	10	7	10	6	5	6	5	3	1	-	1	1 = 65
	R	50	32		7	5	1	7	3	1	2	2	-	-	1	-	- = 29

B = Buccal, Cm = Columellar muscles, DPE = Days post-exposure, Espg = Esophagus, R = Resistant, S = Susceptible.



Table No. 1.1.1 Chi-square test based on over all infected organs due to the mother sporocysts among the susceptible and resistant snails.

Animals	Infected	Uninfected	Total
Susceptible	65 (47)	65 (83)	130
Resistant	29 (47)	101 (83)	130
Total	94	166	260

$\Sigma X^2_{(1)} 21.58 (P < 0.001)$



#### 1.4.1 Distribution of the MS in the foot of the susceptible and resistant snails.

The distribution, location, and total number of the single, multiple, mature and migratory MS found in the foot of the susceptible and resistant snails are presented in Table No. 1.2. Out of 50 susceptible snails, 24 animals had various type of the MS in the foot region, whereas, in the resistant snails 8 animals had only single type of the MS in the same region from 1-10 DPE. The range of the single MS present in the foot of the susceptible and resistant snails was 1-5 and 1-2 respectively during the above period of infection (1-10 DPE). All 5 susceptible snails were positive for the MS at 5 DPE. The variable numbers of various MS were found in the foot of susceptible snails from 1-10 DPE. The distribution of the MS were noted in the anterior (close to the epithelium) and posterior surfaces (connective and muscular tissues) of the foot of the susceptible and resistant snails. Very few single and multiple MS were observed in the susceptible animals up to 4 DPE. The range of single (1-6), multiple (2-67) and mature MS (2-8) was recorded in the foot of the susceptible snails up to 10 DPE. Greater numbers of multiple MS were observed on 5, 6, and 8 DPE, which were 53, 67 and 43 respectively. The maximum number (67) of multiple MS were recognized in the foot of these snails at 6 DPE. Whereas, up to 10 DPE in the foot of the resistant snails only 11 single type of the MS was recognized. Further the number of infected snails and MS were counted in the foot of the susceptible and resistant snails (Table No. 1.2.1). There are 24 infected susceptible ( $n = 24$ ) and 8 resistant snails ( $n = 8$ ). Chi-square test shows highly significant differences between the number of infected foot of the susceptible and resistant snails ( $\Sigma X^2_{(1)} = 11.76, P < 0.01$ ) (Table No. 1.2.1). Four kinds of the MS were recorded, such as single, multiple, mature and migratory types in the susceptible and in the resistant snails only single type of the MS was found. In the susceptible snail these were 23, 189, 24 and 3 respectively of the various types of the MS ( $n = 239$ ) and in the resistant snail only 11 single MS ( $n = 11$ ) were observed. Chi-square test shows highly significant differences between the number of the various types of the MS found in the foot of the susceptible and resistant snails ( $\Sigma X^2_{(3)} = 63.39, P < 0.01$ ) (Table No. 1.2.2).

Table No.1.2 Number of *Schistosoma mansoni* infected animals and various types of MS in the foot of the susceptible and resistant snails of *Biomphalaria glabrata*.

DPE	No of infected snails	No. of MS in the susceptible				No of infected snails	No. of MS in the resistant			
		Single	Multiple	Mature	Migratory		Single	Multiple	Mature	Migratory
1	1	1	-	-	-	2	3	-	-	-
2	2	2	-	-	-	-	-	-	-	-
3	2	1	2	-	-	1	1	-	-	-
4	3	3	2	-	-	1	2	-	-	-
5	5	6	53	-	-	1	1	-	-	-
6	4	5	67	4	-	1	1	-	-	-
7	1	3	4	5	-	-	-	-	-	-
8	3	2	43	8	3	-	-	-	-	-
9	1	-	8	2	-	1	2	-	-	-
10	2	-	10	5	-	1	1	-	-	-
Total	24	23	189	24	3	8	11	-	-	-

Table No. 1.2.1 Chi-square test based on foot of infected susceptible and resistant snails.

Animals	Infected	Uninfected	Total
Susceptible	24 (16)	26 (34)	50
Resistant	8 (16)	42 (34)	50
Total	32	68	100

$\Sigma X^2_{(1)} 11.76 (P < 0.001)$

Table No. 1.2.2 Chi-square test applied on total number of the various types of the MS found in the foot of the susceptible and resistant snails from 1-10 DPE.

Animals	No. of the MS				Total
	Single	Multiple	Mature	Migratory	
Susceptible	23 (32.50)	189 (180.68)	24 (22.94)	3 (2.87)	239
Resistant	11 (1.50)	- (8.32)	- (1.06)	- (0.13)	11
Total	34	189	24	3	250

$\Sigma X^2_{(3)} 63.39 (P < 0.001)$

#### 1.4.1.1 Histology of the MS in the foot of the snails

##### a) Susceptible snails

After penetration of miracidia normal development of the single, multiple, mature and migratory form of MS were observed in foot of the susceptible snails from day 1 onwards (Figs. 4a-f). The MS developed at the surface of the foot reached the blood sinus system after migration and reached the deeper tissues of the organ. The body of MS was characterized by the outer thin tegument with cells, few spread germinal cells, vacuoles and anteriorly located PAS positive penetration glands up to 3 or 4 DPE. Whereas, the structure of MS observed on 1 and 2 DPE consists of very thin tegument, few germinal cells and vacant spaces. On day 5 germinal cells accumulated forming clusters or masses of embryos of DS. Most of the normally developed MS are characterized by the presence of tegument with cells, penetration glands, their germinal cells possess increased amount of cytoplasm, round or oval nucleus with prominent nucleolus. Multiple MS consist of outer thin tegument, muscles and few germinal cells with inconspicuous nuclei. The development of embryos of DS are observed in the mature MS in the foot of the snails from day 6<sup>th</sup> and onwards. The body of the mature MS is characterized by thick tegument with cells, spaces in between the embryos with variable shape and size of germinal cells. The cytoplasm, nuclear membrane and nucleolus stained dark (Fig. 4c). These MS occupied enough spaces in the organ, ultimately they rupture the tegument and migrated to the deeper organs of the host (Fig. 4e). The mean ( $\pm$  SEM) number of the germinal cells of MS present in the foot is  $26.2 \pm 5$  from 1-5 DPE. The mean ( $\pm$  SEM) number of germinal cells in the embryos of DS within the body of mature MS is  $30 \pm 5.51$  at 6 DPE. The germinal cells show vacuolated large round nucleus with few granules of chromatin inside and distributed along the nuclear membrane. However, large size of darkly stained nucleolus is in the center of nucleus and light little homogenous cytoplasm of the cells is visible.

The cytoplasm of the epithelium of the foot surface stained lightly and nucleus darkly. Below the epithelium dense connective tissue is seen characteristically in the foot proper. Mucous cells are found concentrated in large numbers in foot gland and stained pink or blue with dark nuclei. Most of the smooth muscle fibers in the foot run singly in various directions through the dense connective tissue.

##### b) Resistant snails

In the resistant snails few single and few multiple MS were observed (Figs. 5a-d).



Very thin and irregular form of the MS was found in the foot of the snails from 1, 3-6, 9 and 10 DPE. The outer epithelium and connective tissues of the foot of the snails are normal. The irregular MS is characterized by thin tegument, germinal cells with darkly stained pyknotic nuclei, musculature, penetration gland and larger vacant space. At 4 DPE MS is thin with few germinal cells and penetration glands. The germinal cells are smaller in size as compared to susceptible snails. They possess lesser amount of cytoplasm and their nuclei are with prominent nucleolus (Fig.5b).

#### 1.4.1.2 Diameter of the MS in the foot of the susceptible and resistant snails

There are many differences in the structure and shape of the various types of MS developed in the foot of the snails. The mean diameter ( $\pm$  SEM) of the body of the MS developed in the foot of susceptible and resistant snails are presented in Table No. 1.3. The diameter of MS without embryo ranges between  $35.20 \pm 7.54 \mu\text{m}$  and  $84.35 \pm 8.95 \mu\text{m}$  from 1-10 DPE and maximum diameter  $84.35 \pm 8.95 \mu\text{m}$  was noted on 10 DPE in susceptible snails. Whereas, in resistant snails the diameter of MS ranges between  $48.08 \pm 2.15$  and  $92.91 \pm 18.53 \mu\text{m}$ . The mean diameter ( $\pm$  SEM) of the body of the mature MS, embryos of DS and its mean number developed in the foot of susceptible snails are presented in Table No. 1.3.1. The maximum mean diameter of mature MS in susceptible snails is  $256.72 \pm 14.89 \mu\text{m}$  at 9 DPE. At 6 DPE the maximum mean diameter ( $80.68 \pm 4.89 \mu\text{m}$ ) and number (14) of embryos of DS was recorded at 8 DPE.

Table No.1.3 Mean diameter ( $\pm$  SEM) of the mother sporocysts in the foot of susceptible and resistant snails.

DPE	MS diameter ( $\mu\text{m}$ )	
	Susceptible	Resistant
1	40.95 $\pm$ 8.55	55.41 $\pm$ 4.53
2	35.20 $\pm$ 7.54	-
3	54.28 $\pm$ 6.24	-
4	50.86 $\pm$ 4.84	48.08 $\pm$ 2.15
5	42.05 $\pm$ 3.02	-
6	37.65 $\pm$ 2.26	-
7	74.81 $\pm$ 5.38	-
8	77.26 $\pm$ 7.89	-
9	41.56 $\pm$ 6.59	92.91 $\pm$ 18.53
10	84.35 $\pm$ 8.95	-

Table No.1.3.1 Mean diameter ( $\pm$  SEM) of the mature mother sporocysts, number and diameter of the embryos of daughter sporocysts in the foot of susceptible snails

DPE	Mature MS	Embryos of DS	
	Diameter ( $\mu\text{m}$ )	Number	Diameter ( $\mu\text{m}$ )
6	131.21 $\pm$ 9.92	3	80.68 $\pm$ 4.89
7	123.06 $\pm$ 12.7	10	47.67 $\pm$ 1.22
8	103.50 $\pm$ 14.43	14	78.24 $\pm$ 4.89
9	256.72 $\pm$ 14.89	8	44.00 $\pm$ 2.44
10	132.84 $\pm$ 6.97	8	44.48 $\pm$ 1.97

#### 1.4.2 Distribution of the MS in the head of the susceptible and resistant snails.

The distribution and total number of the various types of the MS found in the head of the susceptible and resistant snails are presented in Table No.1.4. Out of 50 susceptible snails, 20 animals had various types of MS in the head, whereas, in the resistant snails 6 animals had only single type of the MS. The range number of the MS present in the head of the susceptible and resistant snails was 1-4 and 1-2 respectively during the infection (1-10 DPE). The distribution of the MS were noted in the anterior (close to the epithelium) and posterior surfaces (connective and muscular tissues) of the head of the susceptible and resistant snails. The range of single (1-9), multiple (4-31) and mature MS (1-3) was recorded in the head of the susceptible snails up to 10 DPE. Increasing number of multiple MS were observed on 5, 6, and 8 DPE, which were 13, 31 and 14 respectively. Whereas, up to 10 DPE in the head of the resistant snails only 6 single type of the MS were recognized. Further the number of infected snails and various MS were counted in the head of the susceptible and resistant snails (Table No. 1.4.1). There are 20 infected susceptible ( $n = 20$ ) and 6 resistant snails ( $n = 6$ ). Chi-square test shows highly significant differences between the number of infected head of the susceptible and resistant snails ( $\Sigma X^2_{(1)} = 10.18, P < 0.01$ ) (Table No. 1.4.1). Four kinds of the MS were recorded, such as single, multiple, mature and migratory types in the susceptible and in the resistant snails only single type of the MS was found. In the susceptible snail there were 24, 93, 7 and 1 MS of each type respectively. There are various types of the MS in susceptible snails ( $n = 125$ ) and in the resistant snails only 6 single MS. Chi-square test shows highly significant differences between the number of the various types of the MS found in the head of the susceptible and resistant snails ( $\Sigma X^2_{(3)} = 16.62, P < 0.01$ ) (Table No. 1.4.2).



Table No.1.4 Number of *Schistosoma mansoni* infected animals and various types of MS in the head of the susceptible and resistant snails of *Biomphalaria glabrata*.

DPE	No of infected snails	No. of MS in the susceptible				No of infected snails	No. of MS in the resistant			
		Single	Multiple	Mature	Migratory		Single	Multiple	Mature	Migratory
1	2	4	-	-	-	1	1	-	-	-
2	1	1	-	-	-	-	-	-	-	-
3	1	2	-	-	-	1	1	-	-	-
4	1	-	4	-	-	-	-	-	-	-
5	3	1	13	-	-	1	1	-	-	-
6	4	9	31	1	-	-	-	-	-	-
7	1	-	5	-	-	-	-	-	-	-
8	3	6	14	3	1	-	-	-	-	-
9	2	-	12	2	-	2	2	-	-	-
10	2	1	12	1	-	1	1	-	-	-
Total	20	24	93	7	1	6	6	-	-	-

Table No. 1.4.1 Chi-square test based on head of the infected susceptible and resistant snails.

Animals	Infected	Uninfected	Total
Susceptible	20 (13)	30 (37)	50
Resistant	6 (13)	44 (37)	50
Total	26	74	100

=  $\Sigma X^2_{(1)}$  10.18 (P < 0.001)

Table No. 1.4.2 Chi-square test applied on total number of the various types of the MS found in the head of the susceptible and resistant snails from 1-10 DPE.

Animals	No. of the MS				Total
	Single	Multiple	Mature	Migratory	
Susceptible	24 (28.63)	93 (88.74)	7 (6.68)	1 (0.95)	125
Resistant	6 (1.37)	- (4.26)	- (0.32)	- (0.05)	6
Total	30	93	7	1	131

=  $\Sigma X^2_{(3)}$  16.62 (P < 0.001)

#### 1.4.2.1 Histology of the MS in the head of the snails.

##### a) Susceptible snails

The structure of MS observed on 1 and 2 DPE consists of very thin tegument, few undifferentiated germinal cells, muscles, penetration glands and vacant spaces. The MS were multiple and mature at 3 and 6 DPE respectively. At 6 DPE within the body of MS extensive branching or multiplication of the MS is visible. There are numerous small MS showing bright red staining reaction in the tegument and light in the inner body region. On 8 DPE within the body of mature MS some variable sizes and shapes of dark embryos of DS are visible (Fig. 4d). Due to the presence of the embryos within the body of mature MS outer epithelium of the head was thin. The mean ( $\pm$  SEM) number of the germinal cells of MS present in the head is  $26.6 \pm 6$  from 1-5 DPE. The mean ( $\pm$  SEM) number of germinal cells in the embryos of DS within the body of mature MS is  $19 \pm 10.51$  at 6 DPE.

##### b) Resistant snails

Single irregular MS was located in the anterior surface of the head. The muscular tissues and mucous glands of head close to the MS were stained light and dark. MS is characterized by thick tegument, musculature, pyknotic dark nuclei, penetration gland, and vacant spaces at 1 DPE (Fig. 5a). In very few MS germinal cells and penetration glands are strongly stained. The epithelial layer of head is thinner in the region where MS is present, whereas, at other parts epithelial layer is thicker. Mucous glands were distinct and appeared blackish blue in the head of the snails.

#### 1.4.2.2 Diameter of the MS in the head of the susceptible and resistant snails

The mean diameter ( $\pm$  SEM) of the body of the MS developed in the head of susceptible and resistant snails are presented in Table No. 1.5. The diameter of MS ranges between  $37.65 \pm 5.55 \mu\text{m}$  and  $99.75 \pm 9.38 \mu\text{m}$  from 1-10 DPE and maximum diameter  $99.75 \pm 9.38 \mu\text{m}$  was noted on 4 DPE in susceptible snails. Whereas, in resistant snails the maximum diameter of MS was  $50.53 \pm 10.70 \mu\text{m}$  on 9 DPE. The mean diameter ( $\pm$  SEM) of the body of the mature MS, number and diameter of the embryos of DS developed in the head of susceptible snails are presented in Table No. 1.5.1. The maximum mean diameter of mature MS in susceptible snails is  $92.09 \pm 7.25 \mu\text{m}$  on 6 DPE. The maximum number of embryos of DS and mean diameter is 13 and  $70.09 \pm 10.97 \mu\text{m}$  respectively in the susceptible snail on 6 DPE.

Table No. 1.5 Mean diameter ( $\pm$  SEM) of the mother sporocysts in the head of susceptible and resistant snails.

DPE	MS diameter ( $\mu\text{m}$ )	
	Susceptible	Resistant
1	37.65 $\pm$ 5.55	-
2	38.62 $\pm$ 2.61	-
3	78.72 $\pm$ 7.59	-
4	99.75 $\pm$ 9.38	-
5	65.52 $\pm$ 4.53	-
6	48.89 $\pm$ 2.04	-
7	56.72 $\pm$ 1.79	-
8	76.77 $\pm$ 6.89	-
9	65.52 $\pm$ 7.51	50.53 $\pm$ 10.70
10	66.01 $\pm$ 9.78	-

Table No. 1.5.1 Mean diameter ( $\pm$  SEM) of the mature mother sporocysts, number and diameter of the embryos of daughter sporocysts in the head of susceptible snails.

DPE	Mature MS diameter ( $\mu\text{m}$ )	Embryos of DS	
		number	diameter ( $\mu\text{m}$ )
6	92.09 $\pm$ 7.25	13	70.09 $\pm$ 10.97
7	-	-	-
8	71.71 $\pm$ 9.61	5	57.05 $\pm$ 4.31
9	70.08 $\pm$ 8.03	10	40.75 $\pm$ 3.55
10	87.2 $\pm$ 4.31	6	44.82 $\pm$ 0.81

#### 1.4.3 Distribution of the MS in the lips of susceptible and resistant snails.

MI that entered the snails through the mouth usually penetrated the oral cavity to reach the lip of the snails. The distribution of various types of the MS found in the lip of the susceptible and resistant snails are presented in Table No. 1.6. Out of 50 susceptible snails, 13 animals had various MS in the lip, whereas, in the resistant snails 1 animal had single type of the MS. The range of the MS present in the lip of the susceptible snails was 1-4 during the infection (1-10 DPE). The variable numbers of various MS were found in the lip of susceptible snails from 1-10 DPE. The distribution of the MS were noted in the anterior (close to the epithelium) and posterior surfaces (connective and muscular tissues) of the lip of the susceptible and resistant snails. Very few single and multiple MS were observed in the susceptible animals up to 4 DPE. The range of single (1-4), and multiple (4-12) was recorded in the lip of the susceptible snails up to 10 DPE. The maximum numbers of multiple MS were observed on 5, 6, and 8 DPE, which were 12, 12 and 12 respectively. Further the number of infected snails and MS were counted in the lip of the susceptible and resistant snails (Table No. 1.6.1). There are 13 infected susceptible ( $n = 13$ ) and 1 resistant snail ( $n = 1$ ). Chi-square test shows highly significant differences between the number of infected lip of the susceptible and resistant snails ( $\Sigma X^2_{(1)} = 11.96, P < 0.001$ ) (Table No. 1.6.1). Four kinds of the MS were recorded, such as single, multiple, mature and migratory types in the susceptible and in resistant snail only former type of the MS was found. In the susceptible snail these were 9, 49, 2 and 1 respectively of the various types of the MS ( $n = 61$ ) and in the resistant snail only 1 single MS ( $n = 1$ ) was observed. Chi-square test shows significant differences between the number of the various types of the MS found in the lip of the susceptible and resistant snails ( $\Sigma X^2_{(3)} = 8.73, P < 0.05$ ) (Table No. 1.6.2).

Table No.1.6 Number of *Schistosoma mansoni* infected animals and various types of MS in the lip of the susceptible and resistant snails of *Biomphalaria glabrata*.

DPE	No of infected snails	No. of MS in the susceptible				No of infected snails		No. of MS in the resistant			
		Single	Multiple	Mature	Migratory	Single	Multiple	Mature	Migratory		
1	1	1	-	-	-	-	-	-	-	-	-
2	-	-	-	-	-	-	-	-	-	-	-
3	1	-	4	-	-	-	-	-	-	-	-
4	1	1	-	-	-	-	-	-	-	-	-
5	4	4	12	-	-	-	-	-	-	-	-
6	2	2	12	-	-	-	-	-	-	-	-
7	-	-	-	-	-	-	-	-	-	-	-
8	2	1	12	1	1	-	-	-	-	-	-
9	2	-	9	1	-	-	-	-	-	-	-
10	-	-	-	-	-	1	1	-	-	-	-
Total	13	9	49	2	1	1	1	-	-	-	-

Table No. 1.6.1 Chi-square test based on lip of the infected susceptible and resistant snails.

Animals	Infected	Uninfected	Total
Susceptible	13 (7)	37 (43)	50
Resistant	1 (7)	49 (43)	50
Total	14	86	100

$\Sigma X^2_{(1)} 11.96 (P < 0.001)$

Table No. 1.6.2 Chi-square test applied on total number of the various types of the MS found in the lip of the susceptible and resistant snails from 1-10 DPE.

Animals	No. of the MS				Total
	Single	Multiple	Mature	Migratory	
Susceptible	9 (9.84)	49 (48.21)	2 (1.97)	1 (0.98)	61
Resistant	1 (0.16)	- (0.79)	- (0.03)	- (0.02)	1
Total	10	49	2	1	62

$= \Sigma X^2_{(3)} 8.73 (P < 0.05)$

#### 1.4.3.1 Histology of MS in the lip of susceptible and resistant snails.

Many MS were developed in the lip of susceptible and very few in resistant snails. The MS were found in the anterior and posterior surfaces of the lip of susceptible snails on 5, 6 and 9 DPE. Few MS were multiple in the anterior surface of the lip of the susceptible snail at 3, 5, 6, 8 and 9 DPE. The body of irregular MS is characterized by the outer thin tegument with cells, spread penetration glands, muscles, few vacant spaces and germinal cells. Germinal cells possessed nuclei with nucleolus and scanty cytoplasm at 1 DPE. The structure of the mature MS present in the lip is same as described in the foot (Fig. 4e). The mean ( $\pm$  SEM) number of the germinal cells of MS present in the lip is  $21 \pm 4.59$  at 1, 3 and 5 DPE. On 8 DPE mature MS containing some embryos of DS and one of them ruptured tegument of MS and migrating deeper region of the lip. Due to presence of mature MS normal mucous cells, inflammation, and thin outer layer of epithelium is also observed.

#### 1.4.3.2 Diameter of the MS in the lip of the susceptible and resistant snails

The mean diameter ( $\pm$  SEM) of the body of the MS in the lip of snails is given in Table No. 1.7. The diameter of MS ranges between  $46.95 \pm 2.72 \mu\text{m}$  and  $90.95 \pm 19.52 \mu\text{m}$  from 1-9 DPE and maximum diameter  $90.95 \pm 19.52 \mu\text{m}$  was noted on 8 DPE in susceptible snails. Whereas, in resistant snails the diameter of MS was  $24.45 \pm 2.44 \mu\text{m}$  on 10 DPE. The mean diameter ( $\pm$  SEM) of the body of the mature MS, number and diameter of the embryos of DS in the lip of susceptible snails is given in Table No. 1.7.1. The maximum mean diameter of mature MS in susceptible snails is  $83.12 \pm 4.23 \mu\text{m}$  on 9 DPE. The maximum number 13 of embryos of DS and mean diameter was  $52.16 \pm 8.63 \mu\text{m}$  respectively in the susceptible snail on 8 DPE.



Table No.1.7 Mean diameter ( $\pm$  SEM) of the mother sporocysts developed in the lip of susceptible and resistant snails.

DPE	MS diameter ( $\mu\text{m}$ )	
	Susceptible	Resistant
1	47.27 $\pm$ 4.31	-
3	46.95 $\pm$ 2.72	-
4	56.23 $\pm$ 2.44	-
5	46.96 $\pm$ 4.97	-
6	50.85 $\pm$ 5.59	-
8	90.95 $\pm$ 19.52	-
9	47.91 $\pm$ 4.61	-
10	-	24.45 $\pm$ 2.44

Table No.1.7.1 Mean diameter ( $\pm$  SEM) of the mature mother sporocysts, number and diameter of the embryos of daughter sporocysts developed in the lip of susceptible snails

DPE	Mature MS diameter ( $\mu\text{m}$ )	Embryos of DS	
		number	diameter ( $\mu\text{m}$ )
8	79.05 $\pm$ 2.94	13	52.16 $\pm$ 8.63
9	83.12 $\pm$ 4.23	7	27.71 $\pm$ 3.55

#### 1.4.4 Distribution of the MS in the tentacles of susceptible and resistant snails.

From the result of present studies several pathways for MS migration are noted. After penetration of the MI in to the tentacles MS are formed at the penetration point. These MS enter the blood vascular system (peripheral blood sinuses, central artery of the tentacle) and from here there is beginning of their migration. Because of this, they were able to complete their migration despite the distance from the final site of infection. The distribution, location, and total number of the single, multiple, mature and migratory MS found in the tentacles of the susceptible and resistant snails are presented in Table No. 1.8. Out of 50 susceptible snails, 22 animals had various types of the MS in the tentacles, whereas, in the resistant snails 10 animals had few single and multiple MS in the same organ from 1-10 DPE. The range of the MS present in the tentacles of the infected susceptible (1-4) and resistant snails (1-2) during the above period of infection (1-10 DPE). The variable numbers of various MS were found in the tentacles of susceptible snails from 1-10 DPE. The distributions of the MS were noted in the apex, body, and base of the tentacles of the susceptible and resistant snails. Very few single and multiple MS were observed in the susceptible animals up to 3 DPE. The range of single (1-6), and multiple (3-24) was recorded in the tentacles of the susceptible snails up to 10 DPE. Greater numbers of multiple MS were observed on 5, 6, and 8 DPE, which were 12, 24 and 13 respectively. Whereas, in the resistant snails total number of the single (12) and multiple (3) MS were recorded up to 10 DPE. Further the number of infected snails and MS were counted in the tentacles of the susceptible and resistant snails (Table No. 1.8.1). There are 22 infected susceptible ( $n = 22$ ) and 10 resistant snails ( $n = 10$ ). Chi-square test shows highly significant differences between the number of infected tentacles of the susceptible and resistant snails ( $\Sigma X^2_{(1)} = 6.62, P < 0.01$ ) (Table No. 1.8.1). Four kinds of the MS were recorded, such as single, multiple, mature and migratory types in the susceptible and in the resistant snails only single and multiple MS were found. In the susceptible snail these were 21, 77, 6 and 1 respectively of the various types of the MS total ( $n = 105$ ) and in the resistant snails single 10 and multiple 3 MS ( $n = 15$ ) were observed. Chi-square test shows highly significant differences between the number of the various types of the MS found in the tentacles of the susceptible and resistant snails ( $\Sigma X^2_{(3)} = 17.31, P < 0.01$ ) (Table No. 1.8.2).

Table No.1.8 Number of *Schistosoma mansoni* infected animals and various types of MS in the tentacles of the susceptible and resistant snails of *Biomphalaria glabrata*.

DPE	No of infected snails	No. of MS in the susceptible			No of infected snails	No. of MS in the resistant			
		Single	Multiple	MatureMigratory		Single	Multiple	MatureMigratory	
1	3	4	-	-	1	1	-	-	
2	1	4	-	-	2	3	-	-	
3	3	1	5	-	1	1	-	-	
4	3	1	11	-	1	2	-	-	
5	2	1	12	-	2	3	-	-	
6	4	6	24	2	-	-	-	-	
7	1	-	5	-	2	2	-	-	
8	3	4	13	2	1	-	-	-	
9	1	-	3	1	-	3	-	-	
10	1	-	4	1	-	-	-	-	
Total	22	21	77	6	1	10	12	3	-



Table No. 1.8.1 Chi-square test based on tentacles of the infected susceptible and resistant snails.

Animals	Infected	Uninfected	Total
Susceptible	22 (16)	28 (34)	50
Resistant	10 (16)	40 (34)	50
Total	32	68	100

$= \Sigma X^2_{(1)} 6.62 (P < 0.001)$

Table No. 1.8.2 Chi-square test applied on total number of the various types of the MS found in the tentacles of the susceptible and resistant snails from 1-10 DPE.

Animals	No. of the MS				Total
	Single	Multiple	Mature	Migratory	
Susceptible	21 (28.8)	77 (70)	6 (5.25)	1 (0.88)	105
Resistant	12 (4.12)	3 (10)	- (0.75)	- (0.12)	15
Total	33	80	6	1	120

$= \Sigma X^2_{(3)} 17.31 (P < 0.001)$

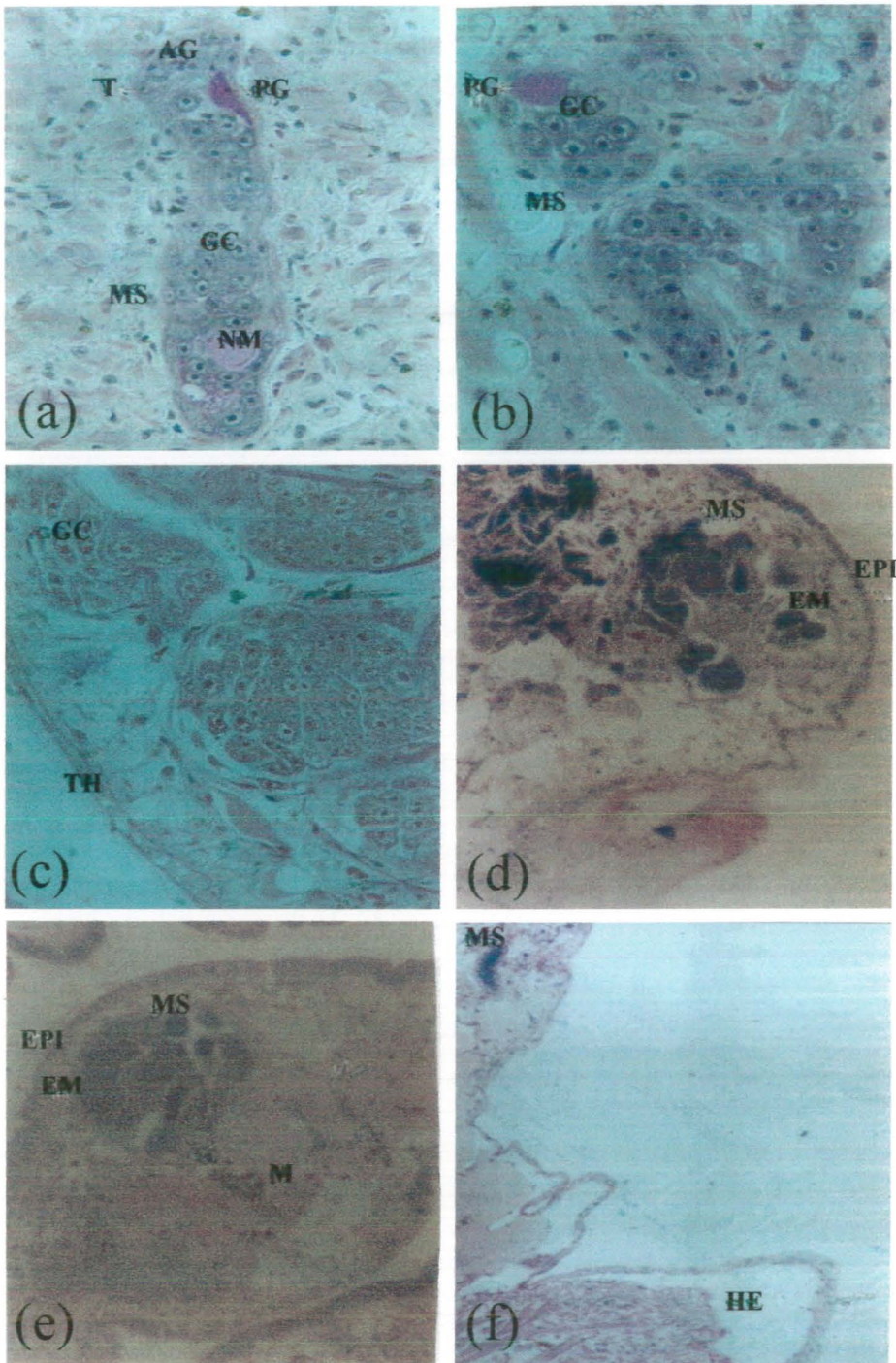
#### 1.4.4.1 Histology of MS in the tentacles of the snails.

##### a) Susceptible snails

The MS developed in the apex, body and base of the tentacles of susceptible snails from 1-10 DPE. Few MS were multiple, mature in the tentacles of the snails from 3, 6 DPE and increasing number of MS were present from day 5 onwards. The body of normal longitudinal (LS) MS is characterized by the outer light thick tegument with cells, vacant spaces, muscles, anteriorly strongly stained penetration gland, neural mass in the bottom containing PAS positive material, some germinal cells are scattered through out the body. Germinal cells possessed nuclei with prominent dark nucleoli and little cytoplasm at 1 DPE (Fig. 4a). At 4 DPE single MS is found close to the retina of eye and multiple MS are also present below the epithelium of the tentacle. The structure of single and multiple MS are described earlier organs. The mean ( $\pm$  SEM) number of the germinal cells of MS present in the tentacle is  $30.6 \pm 6$  from 1-5 DPE. The mean ( $\pm$  SEM) number of germinal cells in the embryos of DS within the body of mature MS is  $8 \pm 0.33$  at 6 DPE.

##### b) Resistant snails

Some single and very few multiple MS were found in the body and base of the tentacles of resistant snails from 1-5, 7, and 9 DPE respectively. At 4 DPE flat MS is characterized by thin tegument, strongly stained penetration gland, vacant spaces and few germinal cells. Germinal cell nuclei were distinct with nucleolus and cytoplasm was lightly stained (Fig.5c).



**Fig.4. Various developmental stages of the *Schistosoma mansoni* mother sporocysts in the susceptible snails of the *Biomphalaria glabrata*.**

**a)** At 1 DPE single mother sporocyst (MS) was visible in the tentacle (416 X).

**b and c)** Multiple mother sporocysts were found in the anus and foot after 3 and 6 DPE (416 X).

**d and e)** After 8 DPE mature mother sporocysts found in the head and lip (228 X).

**f)** Migratory sporocysts seen in the region of the heart at 9 DPE (228 X).

#### 1.4.4.2 Diameter of the MS in the tentacles of the susceptible and resistant snails

The mean diameter ( $\pm$  SEM) of the body of the MS developed in the tentacles of susceptible and resistant snails are presented in Table No. 1.9. The range means diameter of MS in the susceptible snails  $37.16 \pm 4.04 \mu\text{m}$  to  $75.24 \pm 9.61 \mu\text{m}$  at 2 and 9 DPE. Similarly, in the resistant snails the range mean diameter of the MS was  $34.22 \pm 3.28 \mu\text{m}$  to  $57.05 \pm 5.88 \mu\text{m}$  at 2 and 9 DPE. However, the range of the mean diameter of the MS noted in the tentacles of the resistant snails was  $34.22 \pm 3.28 \mu\text{m}$  to  $57.05 \pm 5.88 \mu\text{m}$  at 2 and 9 DPE. The mean diameter ( $\pm$  SEM) of the body of the mature MS, number and diameter of the embryos of DS developed in the tentacles of susceptible snails are presented in Table No. 1.9.1. The maximum mean diameter ( $139.36 \pm 15.54 \mu\text{m}$ ) of mature MS in susceptible snails was observed at 8 DPE. The number (11) of embryos of DS and maximum mean diameter was  $40.75 \pm 2.15 \mu\text{m}$  in the tentacles of susceptible snails was observed at 9 and 10 DPE respectively.



Table No.1.9 Mean diameter( $\pm$  SEM) of the mother sporocysts developed in the tentacles of susceptible and resistant snails.

DPE	MS diameter ( $\mu\text{m}$ )	
	Susceptible	Resistant
1	45.96 $\pm$ 7.22	35.04 $\pm$ 5.34
2	37.16 $\pm$ 4.04	34.22 $\pm$ 3.28
3	54.32 $\pm$ 8.79	39.93 $\pm$ 3.26
4	48.89 $\pm$ 5.07	53.29 $\pm$ 3.40
5	54.27 $\pm$ 4.66	39.60 $\pm$ 3.31
6	55.74 $\pm$ 4.19	-
7	54.76 $\pm$ 3.67	56.23 $\pm$ 1.41
8	53.78 $\pm$ 5.98	-
9	75.24 $\pm$ 9.61	57.05 $\pm$ 5.88
10	56.94 $\pm$ 12.93	-

Table No.1.9.1 Mean diameter ( $\pm$  SEM) of the mature mother sporocysts, number and diameter of the embryos of daughter sporocyst developed in the tentacles of susceptible snails.

DPE	Mature MS diameter ( $\mu\text{m}$ )	Embryos of DS	
		number	diameter ( $\mu\text{m}$ )
6	63.56 $\pm$ 4.23	3	36.67 $\pm$ 1.41
7	-	-	-
8	139.36 $\pm$ 15.54	8	39.12 $\pm$ 2.82
9	125.50 $\pm$ 8.28	11	30.15 $\pm$ 2.15
10	51.34 $\pm$ 1.41	8	40.75 $\pm$ 2.15



#### 1.4.5 Distribution of the MS in the mantle of susceptible and resistant snails.

The distribution of the single, multiple, mature and migratory MS in the mantle of the susceptible and resistant snails are presented in Table No. 1.10. Out of 20 susceptible snails, 7 animals had various types of MS in the mantle, whereas, in the resistant snails 3 animals had only single type of the MS from 3-10 DPE. The range of the MS present in the mantle of the infected susceptible snails was 1-3 during the infection (3-10 DPE). The distribution of the MS were noted in the anterior (close to the epithelium) and posterior surfaces (connective and muscular tissues) of the mantle of the susceptible and resistant snails. The range of the multiple MS (2-44) was recorded in the mantle of the susceptible snails up to 10 DPE. Increasing number of multiple MS were observed on 5 and 6 DPE, which were 44 and 27 respectively. The maximum number (44) of multiple MS were recognized in the mantle of these snails at 5 DPE. Whereas, up to 10 DPE in the mantle of the resistant snails only 3 single type of the MS was recognized. Further the number of infected snails and MS were counted in the mantle of the susceptible and resistant snails (Table No. 1.10.1). There were 7 infected susceptible ( $n = 7$ ) and 3 resistant snails ( $n = 3$ ). Chi-square test shows non-significant differences between the number of infected mantle of the susceptible and resistant snails ( $\Sigma X^2_{(1)} = 3.4$ ,  $P > 0.05$ ) (Table No. 1.10.1). Two types of the MS were recorded, such as multiple and mature MS in the susceptible and only single MS was found in the resistant snail. In the susceptible snail these were 76 and 1 respectively of these types of the MS ( $n = 77$ ) and in the resistant snail only 4 single type of MS were observed. Chi-square test shows highly significant differences between the number of the various types of the MS found in the mantle of the susceptible and resistant snails ( $\Sigma X^2_{(1)} = 72.39$ ,  $P < 0.01$ ) (Table No. 1.10.2).

Table No.1.10 Number of *Schistosoma mansoni* infected animals and various types of MS in the mantle of the susceptible and resistant snails of *Biomphalaria glabrata*.

DPE	No of infected snails	No. of MS in the susceptible				No of infected snails	No. of MS in the resistant			
		Single	Multiple	Mature	Migratory		Single	Multiple	Mature	Migratory
3	1	-	2	-	-	-	-	-	-	-
5	3	-	44	-	-	-	-	-	-	-
6	1	-	27	1	-	1	1	-	-	-
9	-	-	-	-	-	1	1	-	-	-
10	2	-	3	-	-	1	2	-	-	-
Total	7	-	76	1	-	3	4	-	-	-

Table No. 1.10.1 Chi-square test based on mantle of the infected susceptible and resistant snails.

Animals	Infected	Uninfected	Total
Susceptible	7 (5)	43 (45)	50
Resistant	3 (5)	47 (45)	50
Total	10	90	100

$= \Sigma X^2_{(1)} 3.4 (P > 0.05)$

Table No. 1.10.2 Chi-square test applied on total number of the various types of the MS found in the mantle of the susceptible and resistant snails from 3-10 DPE.

Animals	No. of the MS				Total
	Single	Multiple	Mature	Migratory	
Susceptible	- (3.80)	76 (72.25)	1 (0.95)	-	77
Resistant	4 (0.20)	- (3.75)	- (0.05)	-	4
Total	4	76	1	-	81

$= \Sigma X^2_{(1)} 72.39 (P < 0.001)$

#### 1.4.5.1 Histology of MS in mantle of the snails

##### a) Susceptible snails

Few multiple MS were observed in the mantle of the susceptible snails on 3 DPE. The characteristics of single, multiple, and mature MS are similar as mentioned in the foot of the snails. The mean ( $\pm$  SEM) number of germinal cells in the embryos of DS within the body of mature MS is  $38 \pm 0.8$  at 6 DPE.

##### b) Resistant snails

In resistant snail at 10 DPE single elongated MS is characterized by thin tegument, few dark nuclei of germinal cells and vacant spaces in the body.

#### 1.4.5.2 Diameter of the MS in the tentacles of the susceptible and resistant snails

The mean diameter ( $\pm$  SEM) of the body of the MS developed in the mantle of the susceptible and resistant snails is presented in Table No. 1.11. The highest mean diameter of MS in the susceptible snails was  $88.01 \pm 9.93 \mu\text{m}$  at 8 DPE and in the resistant snails was  $54.60 \pm 2.94 \mu\text{m}$  at 10 DPE. The mean diameter of mature MS in the mantle of the susceptible snails was  $96.98 \pm 6.67 \mu\text{m}$  at 6 DPE. In the mantle of susceptible snails at 6 DPE 4 embryos of DS were observed and their mean diameter was  $39.93 \pm 3.55 \mu\text{m}$ .

Table No.1.11 Mean diameter ( $\pm$  SEM) of the mother sporocysts developed in the mantle of susceptible and resistant snails.

DPE	MS diameter ( $\mu\text{m}$ )	
	Susceptible	Resistant
3	$63.56 \pm 18.35$	-
5	$37.16 \pm 5.26$	-
6	$56.72 \pm 5.75$	-
7	$65.03 \pm 8.20$	-
8	$88.01 \pm 9.93$	-
9	-	$39.11 \pm 3.09$
10	$46.45 \pm 2.44$	$54.60 \pm 2.94$

**1) Distribution of MS in various organs of snails.**

The distribution, and total number of the single, multiple, and mature MS found in the various organs of the susceptible and resistant snails are presented in Table No. 1.12. From 3 to 10 DPE MS were visible in the anus, buccal mass and neck of the susceptible and resistant snails. MS were also visible in the kidney, esophagus, heart and lung of the susceptible snails. In the columellar muscles of the resistant snails MS were also visible at 9 DPE.

Table No.1.12 Number of *Schistosoma mansoni* infected animals and various types of MS in the various organs of the susceptible and resistant snails of *Biomphalaria glabrata*.

DPE	No of infected snails	Susceptible organs				No.of infected snails	Resistant organs				
		Single	Multiple	Mature	Migratory		Single	Multiple	Mature	Migratory	
3	1	Anus	-	2	-	-	-	-	-	-	-
4	-	-	-	-	-	1	Anus	1	-	-	-
6	1	-	8	-	-	-	-	-	-	-	-
9	1	1	2	-	-	-	-	-	-	-	-
Total	3		1	12	-	-	1	1	-	-	-
3	-	Neck	-	-	-	1	Neck	1	-	-	-
5	1	-	20	-	-	-	-	-	-	-	-
6	1	-	2	-	-	-	-	-	-	-	-
7	1	-	8	-	-	1	1	-	-	-	-
8	1	-	4	-	-	-	-	-	-	-	-
10	1	1	8	-	-	-	-	-	-	-	-
Total	5		1	42	-	-	2	2	-	-	-

Cont.

4	1	Buccal mass	1	-	-	-	-	-	-	-	-
5	-		-	-	-	-	1	Buccal mass	1	-	-
6	1		-	5	-	-	-		-	-	-
7	-		-	-	-	-	1		1	-	-
8	1		-	8	-	-	-		-	-	-
9	1		-	3	-	-	-		-	-	-
10	1		1	-	-	-	-		-	-	-

Total	5		2	16	-	-	2		2	-	-
-------	---	--	---	----	---	---	---	--	---	---	---

5	1	Kidney-		7	-	-	-		-	-	-
6	1		-	-	1	-	-		-	-	-
10	2		2	-	-	-	-		-	-	-

Total	4		2	7	1	-	-		-	-	-
-------	---	--	---	---	---	---	---	--	---	---	---

8	1	Esophagus-		-	1	-	-		-	-	-
9	1	Heart	1	-	-	-	-		-	-	-
		Columellar muscles	-	-	-	-	1		-	8	-
10	1	Lung	3	-	-	-	-		-	-	-



In the anus there are 3 infected susceptible and 1 resistant snail. Chi-square test shows non significant differences between the number of infected anus of the susceptible and resistant snails ( $\chi^2_{(1)} = 1.4, P > 0.20$ ) (Table No. 1.12.1). Two types single and multiple MS were present in the snails. The total number of the single and multiple MS found in the anus of the susceptible snails were 1 and 12 respectively. Whereas, only one single MS was found in the anus of the resistant snails. Chi-square test shows highly significant differences between the number of the various types of the MS found in the anus of the susceptible and resistant snails ( $\chi^2_{(1)} = 15.75, P < 0.001$ ) (Table No. 1.12.2).

Table No. 1.12.1 Chi-square test based on anus of the infected susceptible and resistant snails.

Animals	Infected	Uninfected	Total
Susceptible	3 (2)	47 (48)	50
Resistant	1 (2)	49 (48)	50
Total	4	96	100

=  $\Sigma X^2_{(1)}$  1.4 (P > 0.20)

Table No. 1.12.2 Chi-square test applied on total number of the various types of the MS found in the anus of the susceptible and resistant snails from 3-10 DPE.

Animals	No. of the MS		Total
	Single	Multiple	
Susceptible	1 (1.86)	12 (11.14)	13
Resistant	1 (0.14)	- (0.86)	1
Total	2	12	14

=  $\Sigma X^2_{(1)}$  5.75 (P < 0.001)

The number of infected snails and MS were counted in the buccal mass of the susceptible and resistant snails. There are 5 infected susceptible ( $n = 5$ ) and 2 resistant snails ( $n = 2$ ). Chi-square test shows non-significant differences between the number of infected buccal mass of the susceptible and resistant snails ( $\chi^2_{(1)} = 1.38, P > 0.20$ ) (Table No. 1.12.3). Two single and 16 multiple MS ( $n = 18$ ) were visible in the buccal mass of the susceptible snails from 4-10 DPE. Whereas, only 2 single MS were found in the same organ of the resistant snails on 5 and 7 DPE. Chi-square test shows highly significant differences between the number of the various types of the MS found in the buccal mass of the susceptible and resistant snails ( $\chi^2_{(1)} = 7.29, P < 0.01$ ) (Table No. 1.12.4).

Table No. 1.12.3 Chi-square test based on buccal mass of the infected susceptible and resistant snails.

Animals	Infected	Uninfected	Total
Susceptible	5 (3.5)	45 (46.5)	50
Resistant	2 (3.5)	48 (46.5)	50
Total	7	93	100

$= \Sigma X^2_{(1)} 1.38 (P > 0.20)$

Table No. 1.12.4 Chi-square test applied on total number of the various types of the MS found in the buccal mass of the susceptible and resistant snails from 4-10 DPE.

Animals	No. of the MS		Total
	Single	Multiple	
Susceptible	2 (3.6)	16 (14.4)	18
Resistant	2 (0.4)	- (1.6)	2
Total	4	16	20

$= \Sigma X^2_{(1)} 7.29 (P < 0.001)$

The number of infected snails and MS were counted in the neck of the susceptible and resistant snails. There are 5 infected susceptible ( $n = 5$ ) and 2 resistant snails. Chi-square test shows non-significant differences between the number of infected neck of the susceptible and resistant snails ( $\Sigma X^2_{(1)} = 1.38, P > 0.20$ ) (Table No. 1.12.5). Two types single and multiple MS were visible in the snails. One single and 42 multiple MS ( $n = 43$ ) were found in the neck of the susceptible snails from 5-10 DPE. However, in the neck of the resistant snails 2 single MS was recognized at 3 and 6 DPE. Chi-square test shows highly significant differences between the number of the various types of the MS found in the neck of the susceptible and resistant snails ( $\Sigma X^2_{(1)} = 28.21, P < 0.01$ ) (Table No. 1.12.6).

Table No. 1.12.5 Chi-square test based on neck of the infected susceptible and resistant snails.

Animals	Infected	Uninfected	Total
Susceptible	5 (3.5)	45 (46.5)	50
Resistant	2 (3.5)	48 (46.5)	50
Total	7	93	100

$= \Sigma X^2_{(1)} 1.38 (P > 0.20)$

Table No. 1.12.6 Chi-square test applied on total number of the various types of the MS found in the neck of the susceptible and resistant snails from 5-10 DPE.

Animals	No. of the MS		Total
	Single	Multiple	
Susceptible	1 (2.87)	42 (40.13)	43
Resistant	2 (0.13)	- (1.87)	2
Total	3	42	45

$= \Sigma X^2_{(1)} 28.21 (P < 0.001)$

Two single, 7 multiple, and 2 mature MS were also visible in the kidney of the susceptible snails at 5, 6, and 10 DPE. One single MS was found in the heart and 3 in the lung and 1 mature MS was present in the esophagus (1) of the susceptible snails at 8-10 DPE. Whereas, 8 multiple MS were recognized in the columellar muscles of the resistant snails at 9 DPE (Table No. 1.12).

## **II) Histology of the MS in the various organs of snails**

### **1.4.6 Anus of the susceptible and resistant snails**

Single and multiple MS are found in the muscular layers of the anus of susceptible snails at 3, 6, and 9 DPE. In the susceptible snails at 3 DPE irregular normal MS exhibits thick tegumental layer, penetration gland, few vacant spaces and increasing number of the germinal cells. The germinal cells had round or oval nuclei with dark prominent nucleoli and light cytoplasm (Fig. 4b). In the resistant snail at 4 DPE single MS is observed in the muscles of the anus. The single MS is showing thin tegument, few vacant spaces and some dark nuclei of the germinal cells. In the muscles of the anus towards the anterior chaetogaster is visible at 4 DPE.

### **1.4.7 Buccal mass of the susceptible and resistant snails**

Single and multiple MS are found in the muscular layer of the buccal mass of the susceptible snails at 4, 6, and 8-10 DPE. In the resistant snail only single type of the MS was found at 5 and 7 DPE. At 6 DPE MS structure is similar as described in the anus of the susceptible snail.

### **1.4.8 Neck of the susceptible and resistant snails**

Single and multiple MS are found in the muscular layer of the neck of the susceptible and resistant snails. Two types of the single and multiple MS were recorded in the susceptible and in resistant snail only single type of the MS was found at 3 and 7 DPE. The histological structure of the MS is similar as described in the anus of the snail. However, due to the presence of some MS outer layer of the epithelium was thin in the susceptible snails at 7 DPE. In the resistant snail at 7 DPE small flat MS is characterized by thin tegument, few nuclei of germinal cells and less stained penetration gland. The epithelium and muscles of the neck is normal.

### **1.4.9 Esophagus of the susceptible and resistant snails**

Mature MS is found in the muscles of the esophagus of snail at 8 DPE. Which exhibits thin tegument, very little vacant space and dark nuclei of the germinal cells of the embryos of DS. No any MS was found in the above organ of the resistant snails from 1-10 DPE.

### **1.4.10 Kidney of the susceptible and resistant snails**

Single, multiple and mature MS are found in the blood space of the saccular portion of the kidney of the susceptible snails on 5, 6, and 10 DPE. At 5 DPE few multiple normal MS displayed thick tegument with cells, vacant spaces and germinal cells. The germinal cells had nuclei with variable size of nucleoli and light cytoplasm.



The wall of the kidney had epithelial cells, crystalline concretion in vacuoles, blood space and lumen visible normal. The mean ( $\pm$  SEM) number of germinal cells in the embryos of DS was  $25 \pm 6.44$  at 6 DPE. No any MS was found in the above organ of the resistant snails during infection.

#### **1.4.11 Heart of the susceptible and resistant snails**

At 9 DPE single elongated migratory MS is present in the pericardial region of the heart. The MS has prominent irregular shaped dark nuclei of germinal cells, PAS positive granules, vacant spaces, and light thick tegument. The tegument possesses dark thin nuclei of cells and tiny spines. The heart muscles are stained light in the bottom of the figure (Fig. 4f). No any MS was found in the above organ of the resistant snail from 1-10 DPE.

#### **1.4.12 Columellar muscles of the susceptible and resistant snails**

From 1-10 DPE no any MS was found in the above organ of the resistant snail from 1-10 DPE. In the columellar muscles of the resistant snail multiple MS were present at 9 DPE. They are characterized by thin tegument, dark body and vacuolated penetration gland. The MS are surrounded by few hemocytes reaction and damaged muscles are visible (Fig. 5d).

#### **1.4.13 Lung of the susceptible and resistant snails.**

Multiple MS were found in the respiratory epithelium of the lung of the susceptible snails at 10 DPE. No any MS was found in the above organ of the resistant snail from 1-10 DPE.

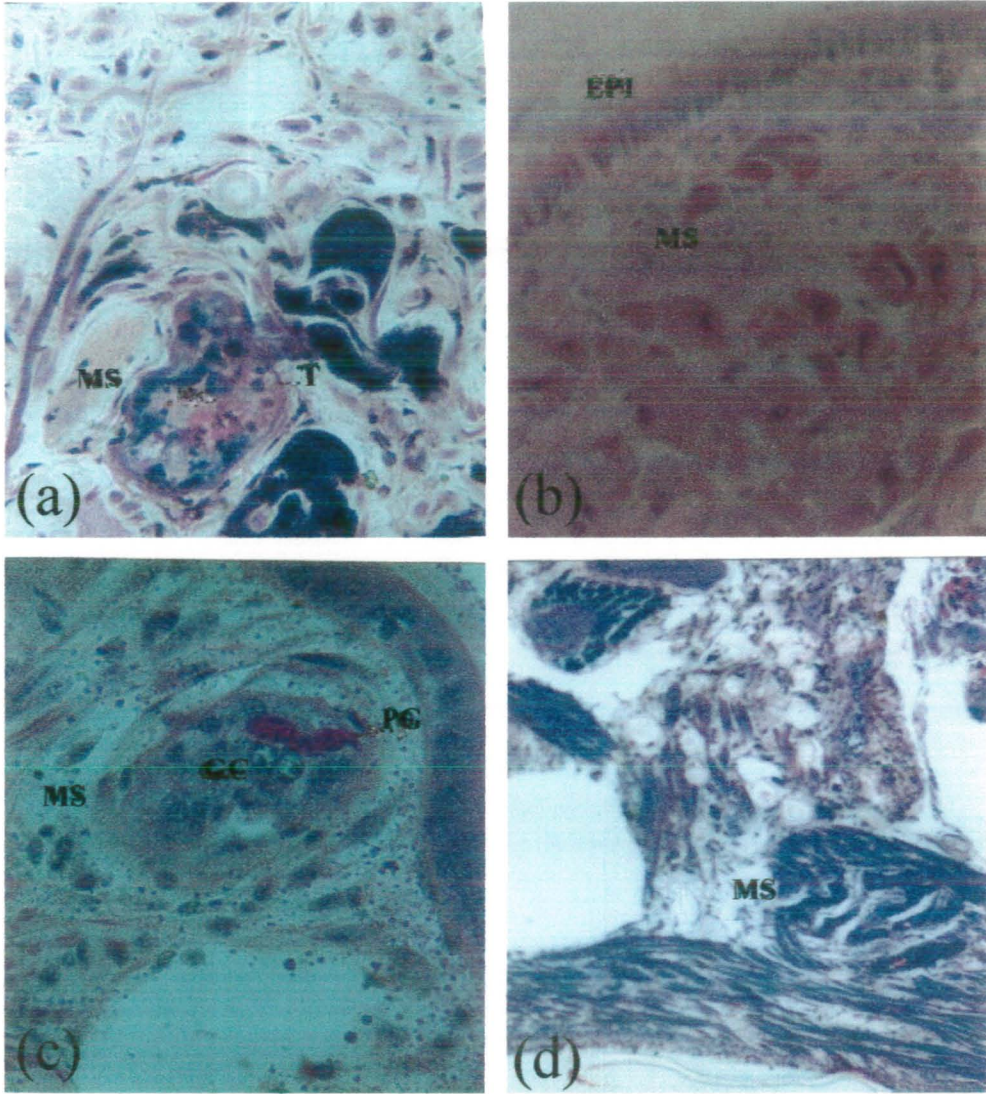


Fig. 5 *Schistosoma mansoni* mother sporocysts found in the resistant snails.

**a, b** and **c**) Single type of the mother sporocysts (MS) were found in the head, foot and tentacle after 1 and 4 DPE (330 X).

**d**) At 9 DPE few multiple mother sporocysts were visible in the columellar muscles (228 X). EM, Embryos; EPI, Epithelium; M, Migratory; T, Tegument; TH, thin.

### III) Diameter of the MS in the various organs of the susceptible and resistant snails.

The mean diameter ( $\pm$  SEM) of the body of the single MS in some of the various organs of susceptible and resistant snails is presented in Table No. 1.13. The highest mean diameter of the MS found in anus of the susceptible snails was  $61 \pm 8.27 \mu\text{m}$  at 8 DPE. Whereas, in the anus of the resistant snails the mean diameter of the MS was  $59.50 \pm 5.88 \mu\text{m}$  at 4 DPE. In the buccal mass of the susceptible snails the highest mean diameter of the MS was  $88.01 \pm 7.53 \mu\text{m}$  at 9 DPE. Whereas, in the buccal mass of the resistant snails the mean diameter of the MS was  $52.16 \pm 5.71 \mu\text{m}$  at 7 DPE. At 8 DPE the maximum mean diameter of the MS found in the neck of the susceptible snails was  $74.81 \pm 7.10 \mu\text{m}$  and in the resistant snails was  $55.41 \pm 2.93 \mu\text{m}$  at 7 DPE. The highest mean diameter of the single MS seen in the kidney of the susceptible snails was  $62.10 \pm 8.24 \mu\text{m}$  at 6 DPE. In the kidney of the susceptible snails the mean diameter ( $80.68 \pm 7.87 \mu\text{m}$ ) of mature MS and embryos of DS was  $54.60 \pm 4.96 \mu\text{m}$  at 6 DPE. No any single, multiple and mature MS found in the kidney of the resistant snails from 1-10 DPE. At 8 DPE the mean diameter of the mature MS found in the esophagus of the susceptible snail was  $124.69 \pm 12.22 \mu\text{m}$ . In the esophagus of the resistant snails no any such type of the MS was visible during infection. The mean diameter of the single type MS found in the region of the heart was  $47.67 \pm 13.44 \mu\text{m}$  at 9 DPE and no any MS was visible in the heart of the resistant snail. In the columellar muscles of the resistant snails the mean diameter of the MS was  $34.22 \pm 2.44 \mu\text{m}$  at 9 DPE but no such parasite was seen in the susceptible snails. At 10 DPE the mean diameter of the MS found in the respiratory epithelium of the lung of the susceptible snail was  $10.75 \pm 1.25 \mu\text{m}$  and MS was not found in the lung of the resistant snails.

Table No. 1.13 Mean diameter ( $\pm$  SEM) of the mother sporocysts developed in the various organs of susceptible and resistant snails.

DPE	Organ	MS diameter ( $\mu\text{m}$ )	
		Susceptible	Resistant
3	Anus	58.67 $\pm$ 6.51	-
4		-	59.50 $\pm$ 5.88
6		47.92 $\pm$ 5.39	-
8		61.61 $\pm$ 8.27	-
4	Buccal mass	86.38 $\pm$ 3.55	-
6		52.81 $\pm$ 4.54	-
7		-	52.16 $\pm$ 5.71
8		48.40 $\pm$ 6.62	-
9		88.01 $\pm$ 7.53	-
10		30.15 $\pm$ 2.93	-
3	Neck	-	26.89 $\pm$ 2.44
5		45.98 $\pm$ 3.05	-
6		50.85 $\pm$ 6.34	-
7		70.41 $\pm$ 5.14	55.41 $\pm$ 2.93
8		74.81 $\pm$ 7.10	-
10		24.45 $\pm$ 4.16	-
5	Kidney	52.15 $\pm$ 3.55	-
6		62.10 $\pm$ 8.24	-
10		30.31 $\pm$ 7.94	-
8	Esophagus	124.69 $\pm$ 12.22	-
9	Heart	47.67 $\pm$ 13.44	-
	Columellar muscles	-	34.22 $\pm$ 2.44
10	Lung	10.75 $\pm$ 1.25	-

#### **Giant snails: MS at 30 DPE**


The snails were selected for gigantism and they had white patches on the regions of the ventral surface of the foot. After 30 DPE few multiple and mature MS are characterized by darkly stained germinal cells, vacant spaces and thin tegument. MS were surrounded by hemocytes reaction and an empty blood vessel is visible. The mean diameter of the mature MS in the foot of snail was  $26.8 \pm 6.58 \mu\text{m}$ . Within the body of mature MS were present a maximum of 8 embryos of DS and mean diameter of each embryo was  $11 \pm 1.50 \mu\text{m}$ .

#### **Resistant snails: MS at 40 DPE.**

Out of five three snails were positive (60%) for the development of the infection. The variable number of the MS were found in the tentacle (1), radula (1), mantle cavity (1), hemocyte producing organ (1), neck (2), head (4), buccal mass (5), shell epithelium (11), albumin gland (13), and salivary.gland (15) in single snail. In two resistant snails higher number of the MS was found in the foot (18), anus (19), columellar muscles (19), mantle (26), and kidney (31). In the respiratory epithelium of the lung of all 3 positive snails 59 MS were observed. Single type of MS was found in the muscular layers of the buccal mass and neck of snail. The histological structure of the MS is same as mentioned earlier in the neck of the resistant snail. Some of the MS are surrounded by mild type of hemocytes reaction. Single, and multiple MS were present in the radula, anus, mantle rim, mantle collar, mantle cavity, salivary glands, respiratory epithelium of the lung, shell epithelium, kidney, hemocytes producing organ and albumin glands of the snails. In the mantle collar few multiple and mature MS are characterized by thick tegument, dark germinal cells, light muscles, vacant spaces and few embryos of DS. On the outer periphery of MS blue stained mucous cells were also observed. Some mature MS were found in the anus, mantle, saccular and tubular portions of the kidney, respiratory epithelium of the lung, shell epithelium, and albumin glands. In the kidney mature MS containing 5 embryos of DS. The structure of MS is similar as described in the earlier organs of the susceptible snails. In the foot and tentacle of the resistant snails the mean diameter ( $\pm$  SEM) of the single MS was  $45.23 \pm 1.22 \mu\text{m}$  and  $64.79 \pm 3.66 \mu\text{m}$  respectively. The mean diameter of the single MS present in the head was  $68.46 \pm 4.89 \mu\text{m}$ . The mean diameter of the single MS was  $54.60 \pm 10.01 \mu\text{m}$ . Single, multiple and mature MS are present in the columellar muscles of the snails. The mean diameter of the mature MS was  $55.62 \pm 10.95 \mu\text{m}$  and containing 6 embryos of the DS.

## 1.5 Discussion

Histological studies have been done on the development of the *S. mansoni* MS in the various organs of susceptible, resistant and giant snails of *B. glabrata*. Snails have been categorized either as suitable or unsuitable for trematode infections (Lie et al., 1987). Susceptible snails are those which allow successful schistosome development (Lie et al., 1977). The present study reveals that susceptible snails are suitable while resistant snails are unsuitable for *S. mansoni* infections. During day 1 and 3 single and multiple MS are present and 6 DPE and onwards mature and migratory MS are visible in the various organs of the susceptible snails. Since the presence of the mature and migratory MS shows that susceptible snails are more suitable for the development of the MS. In contrast to these in the resistant snails only single and multiple MS are present in few organs. No mature or migratory MS is visible indicating that they are not suitable for the development of the parasite. MI of *S. mansoni* penetrate different snail species, but the development of normal sporocyst takes place only in certain species of Biomphalaria (Basch, 1976). In the present study normal developmental stages of the MS are found in the susceptible *B. glabrata* snail. The MI normally penetrates the mantle or head-foot areas of the *B. glabrata* snails and transforms near the site of penetration into MS (Prah and James, 1977). In this study after penetration of MI of *S. mansoni* MS were visible in the foot, head, in addition to lip and tentacle of susceptible snails. No MS was present in the mantle of the susceptible or resistant snail at 1 DPE. MS were found in tentacles, mantle collar, pseudobranch and cerebral ganglia of the *A. glabratus* snails at 1, 2, 4 and 8 DPE (Pan, 1963). In this study various types of the MS are distributed in the tentacles of the susceptible from 1-10 DPE and in the resistant snails on 1-5, 7 and 9 DPE. MS were found in the tentacle and mantle collar of the resistant snails at 40 DPE. In this study no MS was detected in the pseudobranch and cerebral ganglia of the susceptible or resistant snails. Pan, (1963) has reported that more than 90% of the MS are distributed in the different organs and none was found posterior to the saccular portion of the kidney of the snails. Present study revealed that from 1-10 DPE in various organs of the susceptible snails 82% and in the resistant snails 72% of infection was determined. Few various types of the MS were visible in the kidney of the susceptible snails at 5, 6 and 10 DPE. Pan (1963) has reported increasing number of the MS in the head-foot and tentacle, which was 146 and 44 respectively. In the present study at 6 DPE the maximum number of multiple MS recognized in foot, head and tentacles of the susceptible snails was 67, 31, and 26 respectively. In the respiratory epithelium of the lung of resistant snails 59



MS were found at 40 DPE.

The majority of the *S. mansoni* MS develop near the penetration point, normally in the subepithelial conjunctive of the cephalopedal zone with a preference for the lateral edges of the anterior third of foot (Jourdane, 1982). In this study MS were visible in the anterior or below the epithelium and posterior surfaces (connective and muscular tissues) of the foot of the susceptible and resistant snails. Crews et al., (1989) noted MS in the sinusoid of the head, mantle epithelium and antennae of infected snails of *B. glabrata* through 14 DPE. In the present study MS were found in these regions of the head of the susceptible snails from 1-10 DPE and in the mantle at 3 DPE onwards. The MS survive longest in the foot, head, tentacles, pseudobranch and mantle collar of the *A. glabratus* snails (Pan, 1965). In the present study from 1-10 DPE MS also survived longest in the foot, head, tentacles and lip of the susceptible snails of *B. glabrata*. From day 3 onwards MS remained in anus, mantle, on days 4, 5 they were visible in the buccal mass, kidney and at 9 DPE they were present in the heart of the susceptible snails. Whereas, MS reached in the neck, anus, buccal mass and columellar muscles of the resistant snails at 3, 4, 5 and 9 DPE. McMullen, 1951; Lewis et al., (1993) have reported that in long standing infections, foot sporocysts are usually found close to the epidermal layer and sometimes in "blisters" near the surface of the foot. Only 20% of the cases of the foot sporocyst appeared as early as 30 DPE. In this study single and multiple MS are found in the anterior and posterior surfaces of the foot of giant and resistant snails at 30 and 40 DPE respectively.

The multiplication of MS has been reported by Gordon et al., (1934) only in the tentacles of the *P. pfeifferi* snails at 3 DPE. But in the present work MS multiplication was also found in other organs such as foot, head, lip, mantle and anus of the susceptible snails on 3 DPE onwards. The multiplication of MS was also found in the tentacle and columellar muscles of the resistant snails at 9 DPE. Only a small proportion of the *S. mansoni* MI that enter the *A. glabratus* snail host and usually develop to mature MS in the foot (Pan, 1965). In the present after penetration of *S. mansoni* MI, single, multiple and mature MS were found in the foot, head, tentacles, mantle and kidney of the susceptible snails from 6 DPE onwards. In the *A. glabratus* snails mature MS contain embryos of daughter sporocyst (DS) in increasing numbers. One single MS produce hundred of the DS (Wajdi, 1966). However, in the foot of the susceptible snails of *B. glabrata* mature MS contained fewer number (14) of the embryos of the DS at 8 DPE. On day 8 onwards in the foot, head, lip and tentacles of susceptible snail few embryos

ruptured the tegumental layer of MS and reached in the pericardial cavity of heart of the susceptible snails on 9 DPE. Jourdane, (1982) has reported that the MS migrated towards deeper organs where it will develop into the next generation. In the present study at 9 and 10 DPE few MS remained in the heart and respiratory epithelium of the lung and DS were migrated in the gut, digestive gland and ovotestis of the susceptible snails at 9 DPE.

During the early stages of transformation from MI to sporocyst, the cytons shows greatly increased cellular activity with the appearance of membrane-bound bodies. These vesicles appears to store the membrane which is utilized in the formation of the tegument of the MS (Pan, 1980). Which interact with the host hemolymph (Bayne and Hull, 1988). The tegument of *S. mansoni* MS serves as important interface for molecular communication between the parasite and intermediate host, *B. glabrata* (Johnston and Yoshino, 1996). In the present study outer tegumental layer of the MS is variable in appearance, which is thin, and thick muscular with cells.

Some of the youngest MS were round or oval sac and contained four germinal cells, while other had large numbers of germinal cells and showed increase in size in the *P. parkeri* snails (Cort et al., 1952). MS become elongated at 48 hrs. At 3 DPE MS with transverse constrictions and proliferation of germinal tissue (Pan, 1965). MS was amoebal-like up to 4 DPE, gradually takes on the shape of a long sac, more or less folded and rolled back on itself and closely bound to the *Praomys natalensis* snail tissues (Schutte, 1974 b). In the present study irregular and longitudinal MS containing some germinal cells scattered throughout the body and few vacant spaces were found in the lip and tentacles of susceptible snails at 1 DPE. In the foot of resistant snail's irregular MS is characterized by few germinal cells with darkly stained black pyknotic nuclei at 1 DPE. At 4 DPE germinal cells are smaller in size as compared to susceptible snails. They posses lesser amount of cytoplasm and nuclei are with prominent nucleolus. Pan, (1965) reported that degenerating MS contain uniformly stained germinal cells without clearly visible nucleoli. Further in the present study at 3 DPE few multiple MS consist of germinal cells with visible or inconspicuous nuclei in the susceptible snails. Inconspicuous nuclei of germinal cells are perhaps due to the hemocytes reaction surrounded by the MS. Other broad shaped multiple MS exhibits presence of scattered larger sizes of germinal cells, forming clusters and masses of embryos of DS from 5 and 6 DPE in the susceptible snails. At 6-8 DPE some of the mature MS containing germinal cells which possess increase amount of cytoplasm, round or oval nucleus with prominent nucleolus. Multiple and mature MS found in the foot of the giant snails exhibits darkly



stained dark germinal cells at 30 DPE.

After 24 hrs penetration glands and neural mass may still be present in most of MS found in the foot of the *A. glabratus* snails (Pan, 1963). In this study penetration glands and neural mass were also visible in the MS found in the foot and head of the susceptible snails at 1 DPE. In these organs the penetration glands were visible in the single and multiple MS up to 7 DPE. At 1 DPE MS found in the lip and tentacle of the susceptible snails containing, strongly stained spread penetration gland and neural mass containing PAS positive material. In addition to these in the tentacles of the resistant snails penetration glands and neural mass were visible until 7 and 8 DPE respectively.

The length and width of 24 hrs MS of Echinostomatidae is 90 X 40  $\mu\text{m}$  (Ataev et al., 1997). In the present study the mean diameter of the 1 DPE MS of *S. mansoni* developed in the lip of susceptible snail was  $47.27 \pm 4.31 \mu\text{m}$ , which is lesser than above. Pan (1965) has reported the length and width of 48, 72 hrs and 8 DPE MS of *S. mansoni* was 90 X 25  $\mu\text{m}$ , 58 X 44  $\mu\text{m}$  and 165 X 195  $\mu\text{m}$ . In the present study mean diameter of 2, 3 and 8 DPE MS of *S. mansoni* found in the head, mantle and esophagus of the susceptible snail was  $38.62 \pm 2.61 \mu\text{m}$ ,  $63.56 \pm 18.35 \mu\text{m}$  and  $124.69 \pm 12.22 \mu\text{m}$  respectively. The measurements recorded at 48 hrs and 8 DPE were higher than present study. However, in this study increasing mean diameter of the MS was recorded higher than above measurements at 72 hrs. Lo and Lee, (1995) have reported the mean diameter of the 3 and 10 DPE MS of *S. japonicum* was  $45.6 \pm 16.8 \mu\text{m}$  and  $70.2 \pm 40.8 \mu\text{m}$ . In the present study higher mean diameter of 3 and 10 DPE MS found in the anus and foot of the susceptible snails was  $58.67 \pm 6.51 \mu\text{m}$  and  $84.35 \pm 8.95 \mu\text{m}$  respectively. Which was higher diameter than reported by previous workers. Meglitsch, (1967) has reported the dimensions of saccular or migratory tubular sporocyst is roughly 100 X 15  $\mu\text{m}$ . In the present work at 8 DPE higher mean diameter was  $90.95 \pm 19.52 \mu\text{m}$  of migratory MS found in the lip of susceptible snail was recorded.

*CHAPTER NO. 2*

**Histopathological studies of the snails of *Biomphalaria glabrata* due to the mother sporocysts of *Schistosoma mansoni*.**

**Abstract**

Histopathological studies susceptible, resistant and giant snails have been done for the host responses associated during the development of the MS. After penetration of the MI, histological examination of the serial sections of various organs shows infiltration of hemocytes, encapsulations and cysts are developed in the some organs susceptible snails. Whereas, in addition to these host responses early tissue reaction was also visible in the resistant snails from 1-10 DPE. These responses were found in the foot, head, lip, tentacles, mantle, gut, mantle cavity and kidney of the susceptible snails. However, in the resistant snails these responses were also noticed in the first six organs mentioned earlier in the susceptible snails, pharynx, mantle rim, anus and respiratory epithelium of the lung during infection period. The number of the infected organs of the snails was counted. Chi-square test result shows highly significant difference between the infected organs of the susceptible and resistant snails ( $\Sigma X^2_{(1)} 33.47, P < 0.001$ ). In addition to above host responses, at 5 DPE multiple MS were surrounded by hemocytes reaction in the foot of the snails. At 6 and 8 DPE in few occasions due to the presence of multiple and mature MS in the foot, head, lip and tentacles of the snails thin outer epithelial layer and inflammation of these organs was also visible.

Early tissue reaction was observed in the foot, head, and pharynx of the resistant snails at 1-6, and 8 DPE. This reaction was not observed in any organ of the susceptible snails. An infiltration of hemocytes was found in foot and tentacle of the susceptible snails after 2 DPE. An infiltration of hemocytes was visible in the above organs, head, mantle, mantle rim, and anus of the resistant snails at 2-6, 8, and 10 DPE. An encapsulation of the MS was observed in the head, tentacles, mantle and kidney of the susceptible snails on 1, 2, 4 and 9 DPE. Whereas, in the resistant snails an encapsulation was visible in the first three organs mentioned earlier, foot, anus and lung during infection period. A cyst formation appeared in the head, lip, mantle, gut, anus, and mantle cavity of the susceptible snails on 1-6 and 10 DPE. The cyst was also visible in the above mentioned first four organs, foot, tentacle, and mantle rim of the resistant snails. The total number of the infiltration of hemocytes, encapsulation of the MS and cysts formation in the various organs of the susceptible and resistant snails was counted. The total number of the infiltration of hemocytes observed in the resistant and

susceptible snails was 14 and 2. The total number of the encapsulations observed in the resistant and susceptible snails was 28 and 7. The total number of the cyst formation observed in the resistant and susceptible snails was 34 and 12. Chi-square results shows non-significant difference between the various responses in the susceptible and resistant snails ( $\Sigma X^2_{(3)} 3.90, P > 0.20$ ).

The histopathological studies of an infiltration of hemocytes exhibited accumulation of the several layers of the cells in the various organs of the snails. Similarly, an encapsulation of the MS was also surrounded by few to several layers of the hemocytes in the resistant snails. The MS had tegument damage, reduce size, number of the germinal cells, spread penetration gland and increase vacant spaces in the body. In case of the susceptible snails an encapsulation exhibited complete destruction of the multiple MS. The cyst was also surrounded by thin layers of hemocytes and characterised by complete destruction of the MS, few remains of the nuclei of the germinal cells, and increase vacuolated necrotic spaces.

The highest mean diameter ( $163.25 \pm 11.13 \mu\text{m}$ ) of infiltration of hemocytes was recorded in the tentacle of the susceptible snail at 2 DPE. The highest mean diameter of an encapsulation of the MS was  $92.09 \pm 11.85 \mu\text{m}$  recorded in the foot of the resistant snails at 1 DPE. The highest mean diameter of cyst was  $110.83 \pm 2.93 \mu\text{m}$  recorded in the lip of the resistant snails at 1 DPE.

After 30 DPE in the posterior surface of the foot of the giant snails few multiple MS were surrounded by strong hemocytes reaction. An infiltration of the hemocytes was observed in the foot and tentacle of these snails. An encapsulation of the MS and granulomas were also visible in the foot of the giant snails. In later infection after 40 DPE an infiltration of the hemocytes was visible in the respiratory epithelium of lung, kidney, gut, and heart of resistant snails. Inflammation and thin outer layer of respiratory epithelium of lung of resistant snail was also observed. An encapsulation of the MS was visible in the mantle, mantle cavity, and respiratory epithelium of lung of these snails. A cyst formation was also seen in the foot, head, tentacle, mantle, mantle cavity, mantle collar, buccal mass columellar muscles, lung, kidney, and gut of the resistant snails.

## 2.1) Introduction

Schistosomes require a molluscan intermediate host and cause histopathological alterations (Cheng and Bier, 1972). Unsuitable snails are those in which the parasite does not grow because of an unsuitable intramolluscan environment, making them insusceptible. In susceptible snails, the susceptibility to the infection may vary from high to none, depending on the degree of natural resistance (Lo and Lee, 1995). In highly resistant specimens, penetrating MI are quickly recognised and destroyed by means of amebocytes (Borges et al., 1998). On the other hands a greater number of MI that penetrates the snail, they become encapsulated in *S. mansoni* infection (Schutte, 1974 b).

In a normally balanced relationship metamorphosis provoke no host response unless the MS dies in which case the degenerating parasite may be walled-off by concentric layers of fibroblasts with a few hemocytes. *S. mansoni* MS are usually localised in the head-foot of the *A. glabrata* snails and only rarely provoke 'non-specific minimal focal proliferative tissue reaction'. These reactions usually occur within the first 48 h after infection (Pan, 1965). After 11 DPE all sporocysts are encapsulated. The capsules are usually thin, consisting of several layers of flattened cells (Lie et al., 1983). Destroyed sporocysts are defined as disintegrated in structure, being phagocytosed and those that had been completely resorbed, with only an amebocytic accumulation making their former location (Sullivan and Richards, 1981). Congestion of visceral blood sinuses causes an oedematous condition of the head-foot region, which probably assists the subsequent escape of cercariae. The congested arteries also contain slightly hypertrophic amebocytes and there is considerably activity of lymphoid tissue (Pan, 1958). Absence of a cellular reaction around foot sporocysts of *S. mansoni* was reported by Maldonado and Acosta-Matienzo., (1947); Lie et al., (1987); Lewis et al., (1993). There are many differences in the descriptions regarding the appearance of the host responses due to the MS reported by previous workers. The main objective of the present investigation is to compare these aspects, plus various anatomical locations, and development of the host responses by detailed histomorphology. Scanty information is available on the host responses during the progress of infection developed in the various organs of the susceptible, resistant and giant snails of *B. glabrata*, intermediate host of *S. mansoni*.

## 2.2) Aims and objectives of present work

To determine the host responses in various organs, and percentage of the infected susceptible and resistant snails.

To investigate the distribution and number of the host responses in the various organs of the infected susceptible and resistant snails.

To study the histopathology of the host responses in the various organs of the infected susceptible and resistant snails.

To determine the mean diameter of the host responses in the various organs of the infected susceptible and resistant snails.

## 2.3) Materials and methods

The source of material and methods of processing of the animals are the same as mentioned in chapter 1.

## 2.4) Results

After penetration by MI, host responses developed in the various organs of the 9 susceptible and 28 resistant snails after 1-10 DPE (Table No. 2.1). The percentage and organ involvement was also low in the susceptible and high in the resistant snails throughout infection period. After detailed histological examination of the various organs early tissue reaction, infiltration of hemocytes, encapsulations and cyst formation was observed in these snails. The number of the over all infected organs due to the host responses in the susceptible and resistant snails was counted. They were 14 in the susceptible and 40 in the resistant snails. Chi-square test shows highly significant differences on over all infected organs of the susceptible and resistant snails ( $\Sigma X^2_{(1)} 33.47$ ,  $P < 0.001$ ) (Table No. 2.1.1). In the foot and tentacle of the giant snails an infiltration of hemocytes was observed after 30 DPE. In addition to these an encapsulation and two granulomas were also visible in the foot of the giant snails. In later infection at 40 DPE infiltration of hemocytes was noticed in lung, heart and wall of intestine of resistant snails. Few encapsulations were noticed in the mantle, mantle cavity and respiratory epithelium of the lung of the resistant snails. Single cyst was noticed in the foot, head and buccal mass of these snails. There are two cysts visible in the mantle and mantle collar of the resistant snails. Three, six, seven and twelve cysts are found in the columellar muscles, kidney, lung, and intestines of the resistant snails.

Table No. 2.1 Distribution of the host responses in the infected organs among susceptible and resistant snails of *Biomphalaria glabrata* over a period of 10 DPE.

DPE	Snails	Experimental snails	Positive	Percentage (%)	Host responses in the organs												Total	
					Foot	Head	Pharynx	Lip	Tentacle	Mantle	M.rim	M.cavity	Anus	Gut	Lung	Kidney		
1	S	5	1	20	-	+	-	-	-	-	-	-	-	-	-	-	-	1
	R	5	4	80	+	-	+	+	-	+	+	-	-	-	-	-	-	5
2	S	5	2	40	+	-	-	-	+	+	-	-	-	-	-	-	-	3
	R	5	3	60	+	+	-	-	+	+	+	-	-	-	-	+	-	6
3	S	5	1	20	-	-	-	-	-	+	-	-	-	+	-	-	-	2
	R	5	3	60	+	+	-	-	+	+	-	-	-	-	-	-	-	4
4	S	5	1	20	-	+	-	-	+	-	-	-	-	-	-	-	-	2
	R	5	2	40	+	+	-	-	-	-	-	-	-	-	-	-	-	2
5	S	5	1	20	-	-	-	+	-	-	-	-	-	-	-	-	-	1
	R	5	3	60	+	+	-	-	+	-	+	-	-	-	-	-	-	4
6	S	5	1	20	-	-	-	-	-	+	-	-	+	+	-	-	-	3
	R	5	3	60	+	-	-	-	+	+	+	-	-	-	-	-	-	4
7	S	5	-	-	-	-	-	-	-	-	-	-	-	-	-	-	-	-
	R	5	2	40	+	-	-	+	-	+	-	-	+	-	+	-	-	5
8	S	5	-	-	-	-	-	-	-	-	-	-	-	-	-	-	-	-
	R	5	4	80	+	+	-	-	-	+	-	-	+	-	-	-	-	4
9	S	5	1	20	-	-	-	-	-	-	-	+	-	-	-	-	+	2
	R	5	1	20	-	-	-	-	-	+	-	-	-	-	-	-	-	1
10	S	5	1	20	-	-	-	-	-	-	-	-	-	+	-	-	-	1
	R	5	3	60	+	-	-	-	-	+	-	-	+	+	-	-	-	3
Total	S	50	9		1	2	-	1	2	3	-	1	-	3	-	1		=14
	R	50	28		9	5	1	2	4	8	4	-	4	1	2	-		=40

Table No. 2.1.1 Chi-square test based on over all infected organs due to the host responses among the susceptible and resistant snails.

Animals	Infected	Uninfected	Total
Susceptible	14 (27)	106 (98)	120
<b>Resistant</b>	40 (27)	80 (98)	120
Total	54	196	240

$\Sigma X^2_{(1)} 33.47 (P < 0.001)$



#### 2.4.1 Distribution of the host responses in the susceptible and resistant snails.

There are four types of the host responses visible in the various organs of the susceptible and resistant snails from 1-10 DPE. They are early tissue reaction, infiltration of hemocytes, encapsulation and cyst formation. While host responses observed in the different organs are explained separately in the later part of this chapter. Chi-square test was applied for the comparison of the MS (chapter 1) and the host response visible in the each organ of the susceptible and resistant snails. The description of the responses is given below.,

##### A) Early tissue reaction:-

The number of the early tissue reaction appeared in the anterior and posterior surfaces of the foot (Table No. 2.2), head (Table No. 2.3) and pharynx (Table No. 2.9) of the resistant snails. In the foot of these snails maximum number (6) of early tissue reactions were observed from 2-8 DPE.

##### B) Infiltration of hemocytes:-

A number of the infiltration of hemocytes appeared in the foot (Table No. 2.2), head (Table No. 2.3), tentacles (Table No. 2.5), mantle (Table No. 2.6), anus (Table No. 2.7) and mantle rim (Table No. 2.9) of the susceptible and resistant snails. Only a single infiltration of hemocytes was observed in the foot of the susceptible snail at 2 DPE. In the foot of the resistant snails the total number of the infiltration of hemocytes were 5 after 2-6 DPE. In the head (Table No. 2.3) and mantle (Table No. 2.6) of these snails the total number of the infiltration of hemocytes were 3.

##### C) Encapsulation:-

A number of the encapsulations appeared in the foot (Table No. 2.2), head (Table No. 2.3), tentacle (Table No. 2.5), mantle (Table No. 2.6), anus, lung, and kidney (Table No. 2.9) of the susceptible and resistant snails. The total number of the encapsulations in the foot (8), mantle (6), anus (4) and lung (4) of the resistant snails. The maximum number of the encapsulations was noticed in the foot of the resistant snails (Table No. 2.2).

##### D) Cyst formation:-

The number of the cysts appeared in the foot (Table No. 2.2), head (Table No. 2.3), lip (Table No. 2.4), tentacle (Table No. 2.5), mantle (Table No. 2.6), mantle rim, mantle cavity, and anus (Table No. 2.9) of the susceptible and resistant snails. The total

number of the cyst formation was observed in the foot (8), mantle (8), tentacle (6), and head (5) of the resistant snails. Finally, in the foot, head, lip, tentacles, mantle, and anus of the susceptible and resistant snails number of the infected animals and various host responses were recorded.

#### 2.4.1.1 Foot of the susceptible and resistant snails

The host responses appeared in the foot of the resistant snails were 6 early tissue reaction, 5 infiltration of hemocytes, 8 encapsulations and 8 cysts from 1-10 DPE. However, only one infiltration of the hemocytes was present in the susceptible snails at 2 DPE (Table No. 2.2). The number of the MS and host responses appeared in the infected foot of the susceptible and resistant snails were also counted. In the foot of the total infected due to the MS and various host responses in the susceptible (n = 240) and resistant snails (n = 38). was observed. Chi-square test shows highly significant differences due to the mother sporocysts and host responses appeared in the foot of the susceptible and resistant snails ( $\Sigma X^2_{(1)} = 167.77$ ,  $P < 0.001$ ) (Table No. 2.2.1).

Table No. 2.2 Number of the various host responses in the foot of infected susceptible and resistant snails of *Biomphalaria glabrata* mass exposed with miracidia of *Schistosoma mansoni*.

DPE	Susceptible snails				Resistant snails			
	Early tissue reaction	Infiltration of cells	Encapsulation	Cyst	Early tissue reaction	Infiltration of cells	Encapsulation	Cyst
1	-	-	-	-	-	-	1	1
2	-	1	-	-	1	1	-	-
3	-	-	-	-	1	1	1	1
4	-	-	-	-	1	1	-	2
5	-	-	-	-	1	1	-	-
6	-	-	-	-	1	1	-	-
7	-	-	-	-	-	-	4	-
8	-	-	-	-	1	-	1	-
9	-	-	-	-	-	-	-	-
10	-	-	-	-	-	-	1	4
Total	-	1	-	-	6	5	8	8

Table No. 2.2.1 Chi-square test based on the total numbers of the mother sporocysts and host responses in the foot of the susceptible and resistant snails.

Snails	No. of the		Total
	Mother sporocysts	Host responses	
Susceptible	239 (215.83)	1 (24.17)	240
Resistant	11 (34.17)	27 (3.83)	38
Total	250	28	278

$= \sum X^2_{(1)} 167.70 (P < 0.001)$

#### 2.4.1.2 Head of the susceptible and resistant snails

The host responses appeared in the head of the resistant snails were 2 early tissue reaction, 3 infiltration of hemocytes, 3 encapsulations and 5 cysts at 2-5 and 8 DPE. However, only one encapsulation and two cysts were present in the head of the susceptible snails at 1 and 4 DPE (Table No. 2.3). The number of the MS and host responses appeared in the head of the susceptible and resistant snails were counted. The total number of the MS and host responses in the head of the susceptible ( $n = 128$ ) and in the resistant snail ( $n = 19$ ) was observed. Chi-square test shows highly significant differences due to the mother sporocysts and host responses appeared in the head of the susceptible and resistant snails ( $\Sigma X^2_{(1)} 74.37, P < 0.001$ ) (Table No. 2.3.1).

Table No. 2.3 Number of the various host responses in the head of infected susceptible and resistant snails of *Biomphalaria glabrata* mass exposed with miracidia of *Schistosoma mansoni*.

DPE	Susceptible snails				Resistant snails			
	Early tissue reaction	Infiltration of cells	Encapsulation	Cyst	Early tissue reaction	Infiltration of cells	Encapsulation	Cyst
1	-	-	1	1	-	-	-	-
2	-	-	-	-	-	-	1	-
3	-	-	-	-	-	-	1	-
4	-	-	-	1	1	2	-	-
5	-	-	-	-	-	-	-	1
6	-	-	-	-	-	-	-	-
7	-	-	-	-	-	-	-	-
8	-	-	-	-	1	1	1	4
9	-	-	-	-	-	-	-	-
10	-	-	-	-	-	-	-	-
Total	-	-	1	2	2	3	3	5

Table No. 2.3.1 Chi-square test based on the total numbers of the mother sporocysts and host responses in the head of the susceptible and resistant snails.

Snails	No. of the		Total
	Mother sporocysts	Host responses	
Susceptible	125 (114.07)	3 (13.93)	128
Resistant	6 (16.93)	13 (2.07)	19
Total	131	16	147

$$= \sum X^2_{(1)} 74.37 (P < 0.001)$$

#### 2.4.1.3 Lip of the susceptible and resistant snails

The cysts appeared in the lip of the resistant and susceptible snails were 2 and 1 respectively at 5, 5 and 7 DPE (Table No. 2.4). The number of the MS and cysts was counted in these snails. The total number of the MS and host responses in the lip of susceptible (n = 62) and resistant snails (n = 3) was recorded. Chi-square test shows highly significant differences due to the mother sporocysts and host responses appeared in the lip of the susceptible and resistant snails ( $\chi^2_{(1)} = 27.17$ ,  $P < 0.001$ ) (Table No. 2.4.1).



Table No. 2.4 Number of the host responses in the lip of infected susceptible and resistant snails of *Biomphalaria glabrata* mass exposed with miracidia of *Schistosoma mansoni*.

DPE	Susceptible snails				Resistant snails			
	Early tissue reaction	Infiltration of cells	Encapsulation	Cyst	Early tissue reaction	Infiltration of cells	Encapsulation	Cyst
1	-	-	-	-	-	-	-	1
2	-	-	-	-	-	-	-	-
3	-	-	-	-	-	-	-	-
4	-	-	-	-	-	-	-	-
5	-	-	-	1	-	-	-	-
6	-	-	-	-	-	-	-	-
7	-	-	-	-	-	-	-	1
8	-	-	-	-	-	-	-	-
9	-	-	-	-	-	-	-	-
10	-	-	-	-	-	-	-	-
Total	-	-	-	1	-	-	-	2

Table No. 2.4.1 Chi-square test based on the total numbers of the mother sporocysts and host responses in the lip of the susceptible and resistant snails.

Snails	No. of the		Total
	Mother sporocysts	Host responses	
Susceptible	61 (59.14)	1 (2.86)	62
Resistant	1 (1.86)	2 (0.14)	3
Total	62	3	65

$$= \sum X^2_{(1)} 27.17 (P < 0.001)$$

#### 2.4.1.4 Tentacles of the susceptible and resistant snails

The host responses appeared in the tentacles of the resistant snails were 2 infiltration of hemocytes, 2 encapsulations and 6 cysts at 2, 3, 5, 6, and 7 DPE. One infiltration of hemocytes and 2 encapsulations were present in the susceptible snails at 2 and 4 DPE (Table No. 2.5). The number of the MS and host responses appeared in the tentacles of the susceptible and resistant snails were counted. The total number of the MS and host responses in the tentacles of the susceptible ( $n = 108$ ) and in the resistant snail ( $n = 25$ ) was observed. Chi-square test shows highly significant differences due to the mother sporocysts and host responses in the tentacles of the susceptible and resistant snails ( $\Sigma X^2_{(1)} = 84.54, P < 0.001$ ) (Table No. 2.5.1).

Table No. 2.5 Number of the various host responses in the tentacles of susceptible and resistant snails of *Biomphalaria glabrata* mass exposed with miracidia of *Schistosoma mansoni*.

DPE	Susceptible snails				Resistant snails			
	Early tissue reaction	Infiltration of cells	Encapsulation	Cyst	Early tissue reaction	Infiltration of cells	Encapsulation	Cyst
1	-	-	-	-	-	-	-	-
2	-	1	1	-	-	1	-	-
3	-	-	-	-	-	-	-	1
4	-	-	1	-	-	-	-	-
5	-	-	-	-	-	-	1	2
6	-	-	-	-	-	1	1	2
7	-	-	-	-	-	-	-	1
8	-	-	-	-	-	-	-	-
9	-	-	-	-	-	-	-	-
10	-	-	-	-	-	-	-	-
Total	-	1	2	-	-	2	2	6

Table No. 2.5.1 Chi-square test based on the total numbers of the mother sporocysts and host responses in the tentacles of the susceptible and resistant snails.

Snails	No. of the		Total
	Mother sporocysts	Host responses	
Susceptible	105 (55.62)	3 (2.86)	108
Resistant	15 (64.38)	10 (6.97)	25
Total	120	13	133

$$= \Sigma X^2_{(1)} 84.54 (P < 0.001)$$

#### 2.4.1.5 Mantle of the susceptible and resistant snails

The host responses appeared in the mantle of the resistant snails were 2 infiltration of hemocytes, 2 encapsulations and 6 cysts at 2-3, 5-6 and 7 DPE. One infiltration of hemocytes and 2 encapsulations were present in the susceptible snails at 2 and 4 DPE (Table No. 2.6 ). The number of the MS and host responses appeared in the mantle of the susceptible and resistant snails were counted. The total number of the MS and host responses in the mantle of the susceptible (n = 81) and in the resistant snail (n = 22) was observed. Chi-square test shows highly significant differences due to the mother sporocysts and host responses appeared in the mantle of the susceptible and resistant snails ( $\Sigma X^2_{(1)} = 57.86, P < 0.001$ ) (Table Nos. 2.6.1).

Table No. 2.6 Number of the various host responses in the mantle of susceptible and resistant snails of *Biomphalaria glabrata* mass exposed with miracidia of *Schistosoma mansoni*.

DPE	Susceptible snails				Resistant snails			
	Early tissue reaction	Infiltration of cells	Encapsulation	Cyst	Early tissue reaction	Infiltration of cells	Encapsulation	Cyst
1	-	-	-	-	-	-	-	2
2	-	-	1	1	-	-	1	-
3	-	-	-	1	-	1	1	1
4	-	-	-	-	-	-	-	-
5	-	-	-	-	-	-	-	-
6	-	-	-	1	-	1	-	-
7	-	-	-	-	-	-	3	2
8	-	-	-	-	-	-	1	1
9	-	-	-	-	-	-	-	1
10	-	-	-	-	-	1	-	2
Total	-	-	1	3	-	3	6	9

Table No. 2.6.1 Chi-square test based on the total numbers of the mother sporocysts and host responses in the mantle of the susceptible and resistant snails.

Snails	No. of the		Total
	Mother sporocysts	Host responses	
Susceptible	77 (63,70)	4 (17.30)	81
Resistant	4 (17.30)	18 (4.70)	22
Total	81	22	103

$$= \Sigma X^2_{(1)} 57.86 (P < 0.001)$$



#### 2.4.1.6 Anus of the susceptible and resistant snails

The host responses appeared in the anus of the resistant snails were 1 infiltration of hemocytes, 4 encapsulations and 1 cyst was found in the resistant snails at 7, 8, and 10 DPE. One cyst was present in the anus of the susceptible snail at 6 DPE (Table No. 2.7 ). The number of the MS and host responses appeared in the anus of the susceptible and resistant snails were counted. The total number of the MS and host responses in the anus of the susceptible (n = 14) and in the resistant snail (n = 7) was observed. Chi-square test shows highly significant differences due to the mother sporocysts and host responses appeared in the anus of the susceptible and resistant snails ( $\Sigma X^2_{(1)} = 12.98, P < 0.001$ ) (Table No. 2.7.1).

Table No. 2.7 Number of the various host responses in the anus of susceptible and resistant snails of *Biomphalaria glabrata* mass exposed with miracidia of *Schistosoma mansoni*.

DPE	Susceptible snails				Resistant snails			
	Early tissue reaction	Infiltration of cells	Encapsulation	Cyst	Early tissue reaction	Infiltration of cells	Encapsulation	Cyst
1	-	-	-	-	-	-	-	-
2	-	-	-	-	-	-	-	-
3	-	-	-	-	-	-	-	-
4	-	-	-	-	-	-	-	-
5	-	-	-	-	-	-	-	-
6	-	-	-	1	-	-	-	-
7	-	-	-	-	-	-	1	-
8	-	-	-	-	-	1	1	-
9	-	-	-	-	-	-	-	-
10	-	-	-	-	-	-	2	-
Total	-	-	-	1	-	1	4	1

Table No. 2.7.1 Chi-square test based on the total numbers of the mother sporocysts and host responses in the anus of the susceptible and resistant snails.

Snails	No. of the		Total
	Mother sporocysts	Host responses	
Susceptible	13 (9.33)	1 (4.67)	14
Resistant	1 (4.67)	6 (2.33)	7
Total	14	7	21

$= \sum X^2_{(1)} 12.98 (P < 0.001)$

#### **2.4.1.7 Host responses in other organs of the susceptible and resistant snails**

The distribution of the host responses in the other organs of the susceptible and resistant snails is presented in Table No. 2.8. In the pharynx, mantle rim and lung of the resistant snail early tissue reaction, an infiltration of hemocytes, encapsulations and cysts were noticed from 1-8 DPE. No such reactions were visible in these organs of the susceptible snails. However, at 9 DPE encapsulations and a cyst was observed in the kidney and mantle of the susceptible snails.

Table No. 2.8 Number of the various host responses in other organs of the susceptible and resistant snails of *Biomphalaria glabrata* mass exposed with miracidia of *Schistosoma mansoni*.

DPE	Organs	Susceptible snails				Organs	Resistant snails			
		Early tissue reaction	Infiltration of cells	Encapsulation	Cyst		Early tissue reaction	Infiltration of cells	Encapsulation	Cyst
1	-	-	-	-	-	Pharynx	1	-	-	-
	-	-	-	-	-	Mantle rim	-	-	-	1
2	-	-	-	-	-	Mantle rim	-	-	-	1
	-	-	-	-	-	Lung	-	-	2	-
3	-	-	-	-	-		-	-	-	-
4	-	-	-	-	-		-	-	-	-
5	-	-	-	-	-	Mantle rim	-	-	-	1
6	-	-	-	-	-	Mantle rim	-	1	-	-
7	-	-	-	-	-	Lung	-	-	2	-
8	-	-	-	-	-		-	-	-	-
9	Mantle cavity-		-	-	1		-	-	-	-
	Kidney-		-	3	-		-	-	-	-
10	-	-	-	-	-		-	-	-	-

#### 2.4.2 Over all distribution of the host responses in the susceptible and resistant snails

The overall distribution of the host responses in the various organs of the susceptible and resistant snails is presented in Table No. 2.9. No any early tissue reaction observed in any organ of the susceptible snails. In the foot, head and pharynx of the resistant snails this reaction was visible. In the foot and tentacle of the susceptible snail an infiltration of hemocytes was noticed. Whereas, this reaction was visible in addition to these organs, head, mantle and mantle rim of the resistant snails. Encapsulations were recognised in the head, tentacles, mantle and kidney of the susceptible snails. In addition to the first three organs of the susceptible snails, this response was also observed in the foot, mantle cavity and lung of the resistant snails. In the head, lip, mantle, mantle cavity, anus, and gut of the susceptible snails cyst formation was seen. Whereas, this response was found in the addition to first three organs, in foot, tentacles, mantle rim and gut of the resistant snails. The total number of host responses developed in the various organs of the susceptible and resistant snails through *Schistosoma mansoni* infection period is shown in Table No. 2.9.1. Chi-square test shows non-significant difference in between the various host responses observed in the susceptible and resistant snails ( $\Sigma X^2_{(3)} 3.90$ ,  $P > 0.20$ ) (Table No. 2.9.1).

Table No. 2.9 Number of overall host responses in the susceptible and resistant snails of *Biomphalaria glabrata* from 1-10 DPE.

Organs	Susceptible				Resistant			
	Early reaction	Infiltration of hemocytes	Encapsulation	Cyst	Early reaction	Infiltration of hemocytes	Encapsulation	Cyst
Foot	-	1	-	-	6	5	8	8
Head	-	-	1	2	2	3	3	5
Lip	-	-	-	1	-	-	-	2
Tentacle	-	1	2	-	-	2	3	6
Pharynx	-	-	-	-	1	-	-	-
Mantle	-	-	1	2	-	3	6	9
Mantle rim	-	-	-	-	-	1	-	3
Mantle cavity	-	-	-	1	-	-	-	-
Anus	-	-	-	1	-	-	4	-
Intestine	-	-	-	5	-	-	-	1
Kidney	-	-	3	-	-	-	-	-
Lung	-	-	-	-	-	-	4	-

Table No. 2.9.1 Chi-square test applied on total number of the host responses in the susceptible and resistant snails through *Schistosoma mansoni* infection period.

Snails	Host responses				Total
	Early reaction	Infiltration of hemocytes	Encapsulation	Cyst	
Susceptible	- (1.78)	2 (3.17)	7 (6.93)	12 (9-12)	21
Resistant	9 (7.22)	14 (12.83)	28 (28.07)	34 (36.89)	85
Total	9	16	35	46	106

( $\Sigma X^2$  @ 3.90, P > 0.20)





### **Giant snails: Host responses after 30 DPE**

These snails were selected for gigantism and had white patches on the various regions of the ventral surface of the foot. In the anterior surface of the foot, one infiltration of the hemocytes, one encapsulation and two granulomas were recognised. The mean diameter ( $\pm$  SEM) of the infiltration of the hemocytes was  $158.13 \pm 15.12 \mu\text{m}$ , and encapsulation was  $137.25 \pm 2.70 \mu\text{m}$ . An infiltration of hemocytes was also visible in the body of the tentacle of these snails and the mean diameter was  $152.55 \pm 10.80 \mu\text{m}$ .

### **Resistant snails: Host responses after 40 DPE**

Few infiltration of hemocytes are visible in the respiratory epithelium of the lung (1), kidney (1), intestine (1) and heart (1) of the resistant snails. Few encapsulations are found in the mantle (1), mantle cavity (2) and lung (2) of the resistant snails. There are some cysts in the foot (1), head (4), tentacle (1), mantle (4), mantle cavity (1), mantle collar (1), buccal mass (1), columellar muscles (3), lung (7), kidney (6) and intestine (12) in the resistant snails. A single infiltration of hemocytes, encapsulations, and seven cysts are found in the respiratory epithelium of the lung of the snails. In the mantle cavity of the resistant snails a cyst exhibits some hemocytes with nuclei and few necrotic spaces. Six cysts were also found in the saccular and tubular portions of the kidney of the resistant snails and structure of the cyst is same as observed in the mantle cavity of the snails (Fig. 6i).

#### 2.4.2 Histopathology of the host responses in the snails.

The histopathological findings are more or less similar in the various organs of the snails, however following main host responses were recorded with the association of the MS. The mean diameter ( $\pm$  SEM) of the host responses such as infiltration of hemocytes, encapsulations and cysts found in the various organs of the susceptible and resistant snails is presented in Table No. 2.10 to 2.12.

A) **Early tissue reaction:-** Early tissue reaction is defined as minimal focal in nature and few scattered hemocytes. Early tissue reaction is visible in the areas of the foot, head and pharynx of the resistant snails. At 1 DPE the mean diameter of the early tissue reaction was  $63.56 \pm 13.90 \mu\text{m}$  recorded in the pharynx of the resistant snail.

B) **Infiltration of hemocytes:-** Infiltration of the hemocytes is exhibited by accumulation of the several hemocytes in the various organs of the susceptible and resistant snails. MI entered in the body of the tentacle of the resistant snail caused mild infiltration of the hemocytes and their accumulation was in circular form at 2 DPE (Fig. 6a).

#### **Diameter of the infiltration of hemocytes in the susceptible and resistant snails.**

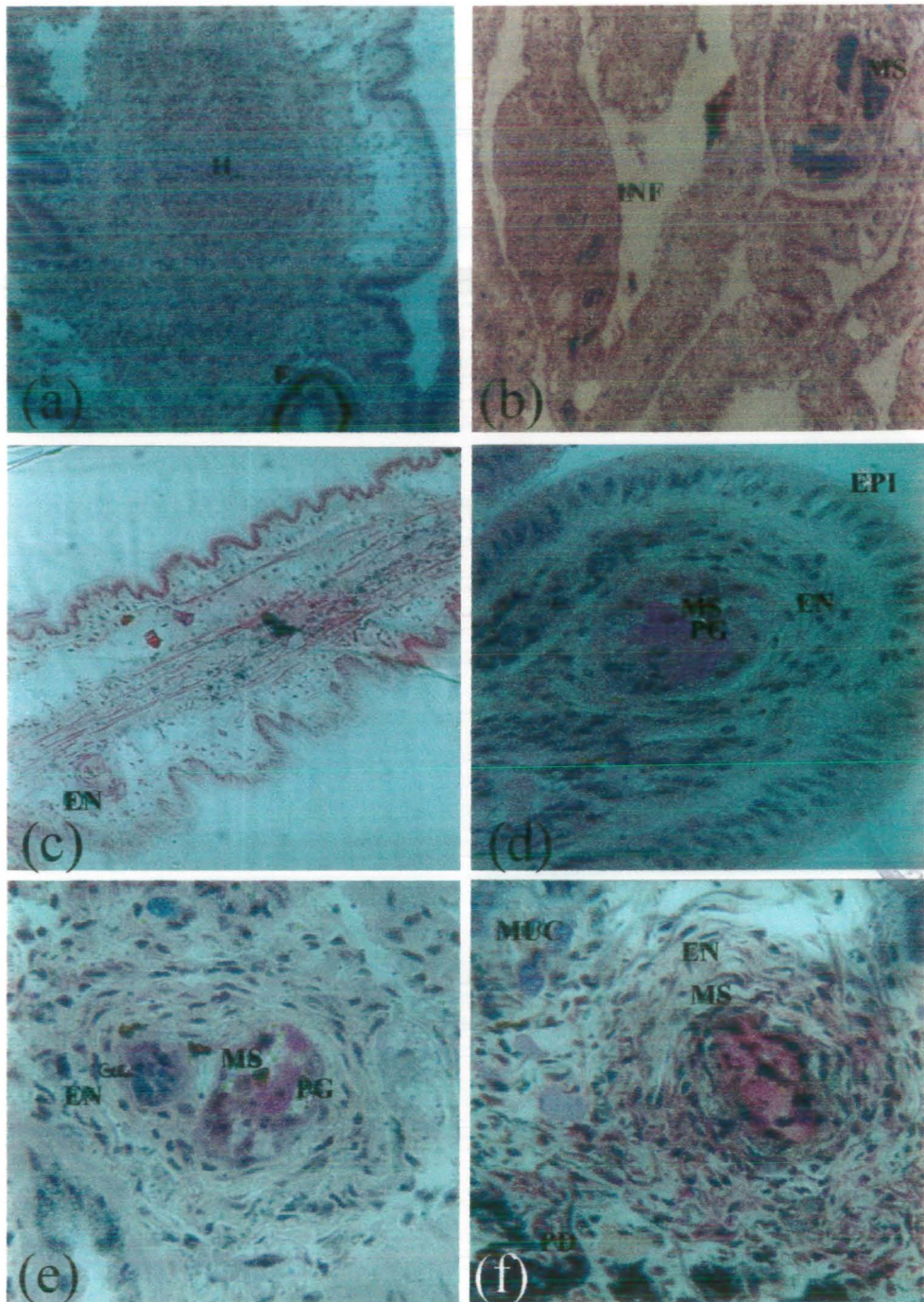
The mean diameter ( $\pm$  SEM) of the infiltration of hemocytes found in the various organs of the susceptible and resistant snails is presented in Table No. 2.10. In the susceptible snails the mean diameter of infiltration of hemocytes in the tentacle and foot was  $163.25 \pm 11.13 \mu\text{m}$  and  $119.80 \pm 7.85 \mu\text{m}$  respectively. In case of the resistant snails maximum mean diameter of the infiltration of hemocytes was observed in the foot, which was  $112.47 \pm 9.98 \mu\text{m}$  at 2 DPE.

Table No. 2.10 Mean diameter ( $\pm$  SEM) of the infiltration of the hemocytes in various organs of the susceptible and resistant snails.

DPE	Foot ( $\mu\text{m}$ )		Head ( $\mu\text{m}$ )		Tentacle ( $\mu\text{m}$ )	Mantle ( $\mu\text{m}$ )
	Susceptible	Resistant	Resistant	Susceptible	Resistant	Resistant
1	-	-	-	-	-	-
2	119.80 $\pm$ 7.85	112.47 $\pm$ 9.98	-	163.25 $\pm$ 11.13	101.87 $\pm$ 3.26	-
3	-	83.12 $\pm$ 7.05	-	-	-	-
4	-	-	90.46 $\pm$ 4.23	-	-	-
5	-	45.63 $\pm$ 2.93	-	-	-	-
6	-	-	-	-	-	47.26 $\pm$ 2.93

**B.1) Inflammation:-** In the head, lip and tentacles of the few susceptible snails due to the development of the mature MS the outer walls of the organs were swollen. In later infection at 40 DPE due to the presence of the multiple MS inflammation, extensive infiltration of hemocytes, and very thin outer layers of the respiratory epithelium of the lung of the resistant snail was visible (Fig. 6b).

**C) Encapsulation:-** Very early encapsulation of the MS is surrounded by the few fibres, hemocytes, muscles and is located below the epithelium of the tentacle of the resistant snail at 6 DPE. MS had thin tegument, germinal cells with red nuclei and vacant spaces (Fig. 6c). At 2 DPE an encapsulation of double MS is surrounded by mild hemocyte reactions. The hemocytes contained spindle shaped nuclei and light cytoplasm. Some spherical germinal cells contain distinct nuclei with nucleolus, few of them are irregular and elongated in shape. The penetration gland fills most of inner part of body of MS and comparatively larger vacuolated areas are visible in the peripheral region. The outer epithelial layer with cilia of the head of the resistant snail is normal (Fig. 6d). In the lung of the resistant snail an encapsulated double MS had germinal cells with dark nuclei of germinal cells, vacant spaces, scattered penetration gland, thin tegumental layer and surrounded by few layers of hemocytes in the respiratory epithelium of the lung at 2 DPE (Fig. 6e). In the foot of resistant snail an encapsulation is characterised by several hemocytes containing dark nuclei surrounded by the centrally placed parasite (MS) and is observed at 1 DPE. Within the MS, most of the part of the body is filled with brightly stained pink penetration gland, and in between few germinal cells with dark nuclei are present. A few vacant spaces are also visible. In the anterior region of the foot of the host bluish stained mucous cells and dark pedal glands are also observed (Fig. 6f). At 9 DPE encapsulations of the multiple MS is noted in the saccular portion of the kidney of the susceptible snail; which exhibits destruction of the parasite at 9 DPE. It has dark remains in the centre and surrounded by fibrous layers (Fig. 6g).



**Fig. 6 Host responses due to the *Schistosoma mansoni* mother sporocysts (MS) in the susceptible and resistant snails.**

**a and c)** Infiltration of hemocytes (H) and early encapsulation (EN) of the parasite was seen in the tentacles at 2 and 6 DPE (228 X).

**b and e)** At 40 DPE inflammation (INF) and degenerating mother sporocysts and encapsulation was seen in the respiratory epithelium of the lung at 2 DPE (228 X and 416 X).

**d and f)** Moderate and severe encapsulations of the sporocysts were visible in the foot and head at 1 and 4 DPE (416 X).

**Diameter of the encapsulation of the MS in the susceptible and resistant snails.**

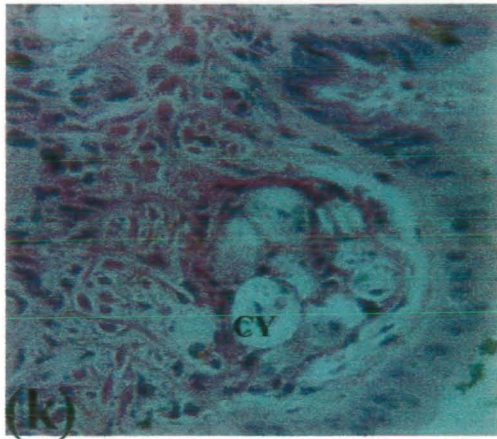
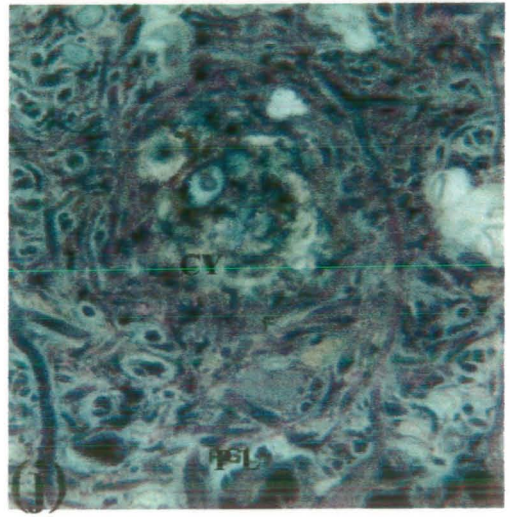
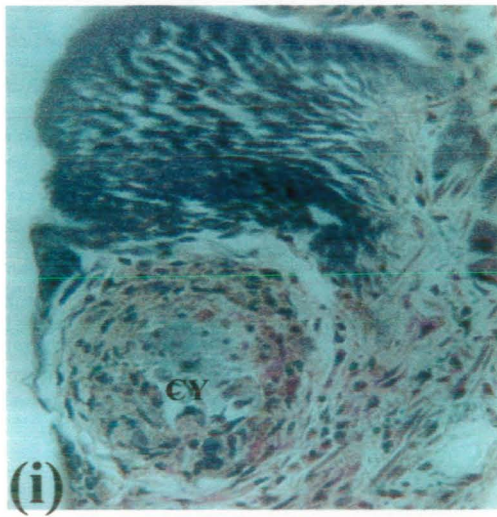
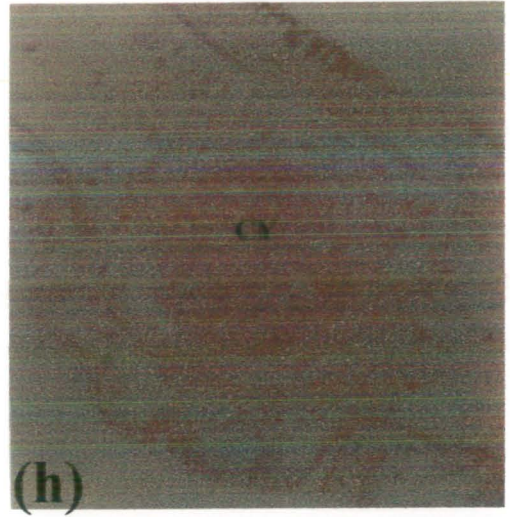
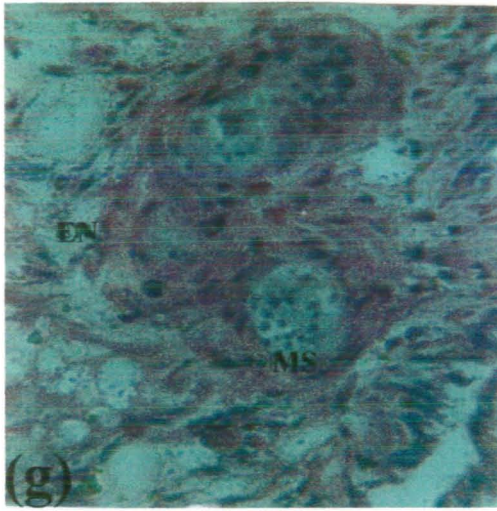
The mean diameter ( $\pm$  SEM) of the encapsulations of the MS found in the various organs of the susceptible and resistant snails is presented in Table No. 2.11. In the foot and mantle of the resistant snails the highest mean diameter for an encapsulation was  $92.09 \pm 11.85 \mu\text{m}$  and  $55.41 \pm 12.17 \mu\text{m}$  at 1 and 3 DPE. In case of the head of the susceptible snails the mean diameter was  $35.20 \pm 4.13 \mu\text{m}$  at 1 DPE.

Table No. 2.11 Mean diameter ( $\pm$  SEM) of the encapsulations of the MS in various organs of the susceptible and resistant snails.

DPE	Foot ( $\mu\text{m}$ )	Head ( $\mu\text{m}$ )	Tentacle ( $\mu\text{m}$ )	Mantle ( $\mu\text{m}$ )	Lung ( $\mu\text{m}$ )	Anus ( $\mu\text{m}$ )
	Resistant	Susceptible	Resistant	Resistant	Resistant	Resistant
1	92.09 $\pm$ 11.85	35.20 $\pm$ 4.13	-	-	-	-
2	56.23 $\pm$ 4.89	-	-	39.11 $\pm$ 1.41	37.89 $\pm$ 6.11	-
3	35.85 $\pm$ 4.53	-	-	55.41 $\pm$ 12.17	-	-
4	-	-	-	-	-	-
5	-	-	68.45 $\pm$ 3.73	-	-	-
6	-	-	-	-	-	-
7	59.9 $\pm$ 15.89	-	-	48.9 $\pm$ 14.67	40.34 $\pm$ 6.11	58.67 $\pm$ 3.73
8	62.34 $\pm$ 3.66	-	-	-	-	-

D) **Cyst:-** At 9 DPE small circular cyst appeared in the middle region of the mantle cavity of susceptible snails. The cyst is surrounded by some hemocytes nuclei and filled with vacuolated necrotic areas. In the cross section of the organ the outer shell epithelial layer is darkly stained and inner epithelium of the mantle cavity is swollen (Fig. 6h). At 1 DPE large circular cyst is found in the mantle rim of the resistant snail. The cyst is characterised by completely destruction of the MS, which appears dark in colour in the middle, few remains of nuclei of germinal cells, penetration glands, several layers of hemocytes, and thin outer layer of epithelium of the mantle rim was damaged (Fig. 6i). A large cyst was visible on 1 DPE, which exhibits a complete destruction of the parasite, dark contents, necrotic areas that are surrounded by fibres and muscles of the foot of the resistant snail (Fig. 6j). In the head of susceptible snail a small cyst has filled larger necrotic spaces, few darkly stained cells, and surrounded by thin layer of elongated fibres at 4 DPE (Fig. 6k).





**g)** An encapsulation (EN) of the multiple sporocysts was found in the kidney of the susceptible snails at 9 DPE (416 X).

**h and k)** Various stages of the cysts (CY) were seen in the mantle cavity of the susceptible on 9 DPE and in head of the resistant snails at 4 DPE (228 X and 416 X).

**i and j)** In the mantle rim and foot of resistant snails developed cysts were seen at 1 DPE (416 X). MUC, Mucous cells; PL, Pedal gland.

**Diameter of the cysts in the susceptible and resistant snails.**

The mean diameter ( $\pm$  SEM) of the cyst formed in various organs of the susceptible and resistant snails is presented in Table No. 2.12. In the lip of the resistant snail the highest mean diameter of the cyst was  $110.83 \pm 2.93 \mu\text{m}$  at 1 DPE. In the tentacles and foot of the resistant snails the maximum mean diameter was  $81.90 \pm 8.55 \mu\text{m}$ ,  $79.86 \pm 9.61 \mu\text{m}$  at 5 and 10 DPE respectively. In the mantle of the susceptible snails at 6 DPE the highest mean diameter was  $89.82 \pm 10.74 \mu\text{m}$ . Whereas, in the mantle of the resistant snails the highest mean diameter was  $57.45 \pm 1.22 \mu\text{m}$  at 8 DPE.

Table No. 2.12 Mean diameter ( $\pm$  SEM) of the cyst formations in various organs of the susceptible and resistant snails.

DPE	Foot ( $\mu\text{m}$ )		Head ( $\mu\text{m}$ )		Tentacle ( $\mu\text{m}$ )		Mantle ( $\mu\text{m}$ )		Lip ( $\mu\text{m}$ )		Intestine ( $\mu\text{m}$ )
	Resistant	Susceptible	Resistant	Susceptible	Resistant	Susceptible	Resistant	Susceptible	Resistant	Susceptible	Susceptible
1	-	36.67 $\pm$ 4.89	-	-	-	-	-	-	-	110.83 $\pm$ 2.93	-
2	-	-	-	-	57.86 $\pm$ 7.77	41.56 $\pm$ 2.44	-	-	-	-	-
3	69.27 $\pm$ 2.93	-	-	-	59.9 $\pm$ 1.22	65.19 $\pm$ 2.93	51.34 $\pm$ 4.89	-	-	-	-
5	-	-	-	-	79.86 $\pm$ 9.61	-	-	-	33.63 $\pm$ 9.18	-	-
6	-	-	-	-	68.46 $\pm$ 5.64	89.82 $\pm$ 10.74	-	-	-	-	156.47 $\pm$ 17.11
7	-	-	-	-	72.12 $\pm$ 6.11	-	-	-	-	62.75 $\pm$ 3.55	-
8	-	-	-	64.79 $\pm$ 8.56	-	-	57.45 $\pm$ 1.22	-	-	-	-
9	-	-	-	-	-	63.19 $\pm$ 16.04	-	-	-	-	-
10	81.90 $\pm$ 8.55	-	-	-	-	-	37.89 $\pm$ 6.11	-	-	-	-

## 2.5) Discussion

A histopathological study has been done after penetration by the MI of *S. mansoni* in the various organs of the susceptible, resistant and giant snails of *B. glabrata* at 1-10, 30 and 40 DPE. In the present study MI penetrated into the foot, lip, pharynx, mantle, and mantle rim of the resistant snails and only in the head of the susceptible snail at 1 DPE. Similar results are reported by Newton, (1952); Kassim and Richards, (1979). They also reported that MI of *S. mansoni* penetrated in to the foot, head, tentacle and anterior mantle of the susceptible and resistant strains *B. glabrata*. Pan, (1963) has reported rarely non-specific minimal focal proliferative tissue reaction within the 48 h after infection in the head-foot of the *A. glabrata* snails. In the present study early tissue reaction was noticed in the foot, and pharynx at 1 DPE. Lewis et al., (1993) has reported that most of the foot sporocysts elicit some degree of host reaction. He further stated that a lack of phagocytosis, especially of sporocysts in the foot, presents a much different picture than the intense host reaction typically seen in the resistant snails used in the parental crosses. In the present study MS present in foot of the resistant snail was surrounded by mild type hemocytes reaction at 1 DPE. Whereas, after 5 DPE in the foot of the susceptible snails few multiple MS were surrounded by some hemocytes reaction. Pan, (1963) further mentioned that in compact tissues the MS may bring about localised degenerative changes due to the pressure and this may provoke a slight infiltration of non-hypertrophic fibroblasts. It is probably for this reason that MI enter the more compact, muscular tissues of the foot are less successful in establishing an infection than those which get into the open spaces of the head region and the mantle of the *A. glabrata* snails. In this study due to the presence of the MS in the connective and muscular tissues of the foot and tentacle of the susceptible snails a infiltration of the hemocytes was noticed at 2 DPE. However, in the foot, head, mantle, and mantle rim of the resistant snail some degenerative changes in the MS were observed at 1 and 4 DPE. Pan, (1965) has reported a cellular reaction of one to several layers of flattened hemocytes surrounding the MS at 3 DPE. These results are in agreement with the present study. However, above author has not mentioned the name of the organs of the snails and type of the MS surrounded by the hemocytes layers. In this study single, and double MS visible in the tentacle, foot, and head of the resistant snails are surrounded by one to several layers of the hemocytes after 1-2 and 6 DPE. Whereas, after 9 DPE in the kidney of the susceptible snail multiple MS

are also surrounded by one to few layers of the hemocytes. Richards, (1975 c); Kassim and Richards, (1979) have reported that the sporocysts of *S. mansoni* usually do not elicit cellular response in the susceptible *B. glabrata* snails unless the numbers are excessive, e.g., beyond 4-5 or 6-8 per snail. In present study in the foot and tentacle of the susceptible snails of the *B. glabrata* at 2 DPE mild and moderate types of the infiltration of hemocytes was found.

An excess effect has been observed in the susceptible snails exposed to 25 MI per snails in which only four or five MS developed normally whereas the rest were encapsulated after 24 h (Richards, 1975a). In contrast to these no such effect was observed in the various organs of the susceptible snails used in this study at 1 DPE. It is possible that the encapsulation of excess MI is influenced by the genetics of snails and parasite, with perhaps snail genotypes having characteristics "thresholds" for specific strains of schistosomes (Sullivan and Richards, 1981). In the present study various stages of the encapsulation of the MS were seen in the head, tentacle, mantle and kidney of the susceptible snails. However, in the resistant snails encapsulations were noticed in addition to first three organs reported earlier, foot, anus, and in the lung indicating that *B. glabrata* might be genetically influence by genetics of the snails and MS.

After 24 hrs most MS observed lacked tegumental cytoplasm, germinal cells and other internal structures showed extensive pathological changes (Locker et al., 1982). These results are agreement with the present study. But in addition to above findings at 1 DPE dark nuclei of germinal cells and spread of penetration gland of the MS found in the foot of the resistant snail at 1 DPE.

Lie et al., (1983) observed host responses in the juvenile-susceptible host snails strain of *B. glabrata* infected with the MI of *S. mansoni*. Tissue sections of 21 snails exposes only to irradiated MI showed that development of the MS was arrested and most remaining small. Encapsulation of the MS begins 2 DPE and after 7 DPE about 20% of the MS were encapsulated (Lie et al., 1983). In the present study adult susceptible snails of *B. glabrata* mass exposed with MI of *S. mansoni*. Encapsulation of the MS was seen in the foot and head of the resistant snails at 1 and 2 DPE. However, at 7 DPE similar percentage of MS encapsulation was observed in the foot of resistant snails.

When *S. mansoni* MI penetrate resistant individuals of snail *B. glabrata*, the MS is encapsulated by the hemocytes (Bayne et al., 1980 a). These results are in agreement

with this study. An encapsulation and subsequent destruction of helminths by molluscan hemocytes is well known (Cheng and Rifkin, 1970; Loker and Bayne, 1986). Host encapsulation reaction varies in intensity but the contents of the encapsulated sporocysts generally appear viable (Lewis et al., 1993). In the present study host encapsulation reaction was also varies in the various organs of the resistant and susceptible snails. The structure of the encapsulated MS remained viable in the resistant snails. But in case of the kidney of the susceptible snail the structure of the MS was disappears. Pan, (1965) has reported that due to the development of the MS in the tentacles swelling and deformities were observed. He further reported that during the course of normal infection the first obvious signs are seen about 5 DPE when the MS have grown and caused local occlusion of blood sinuses resulting superficial swelling and, in deeper-seated individuals, translucent patches due to the accumulation of the blood. Similar results were observed during the appearance of the multiple and mature MS in the foot, head, lip and neck of the susceptible snails. Due to appearance of these MS at 5 DPE and onwards thin outer epithelial layer and inflammation was observed in the foot, head and lip of the susceptible snails. MS occupied much spaces in the organs, close to these increase vacant spaces and no translucent patches due to the accumulation of the blood was observed in the present study. Whereas, after 30 DPE in the foot of the giant snails close to the multiple MS an empty blood vessel was found. In later infection after 40 DPE thin respiratory epithelium of the lung and inflammation was noticed in the resistant snails.

The pathological events occurring within the first week of infection were relatively few and changes occurring at progressively longer intervals post-exposure (Bayne, 1983). In the present study from 1-10 DPE extensive pathological changes occurs such as, early tissue reaction, an infiltration of hemocytes, encapsulation, and cyst formed in the susceptible and resistant snails. Total number of early tissue reaction in the resistant snails was 9 and no any such reaction of the tissue was visible in the susceptible snails. Total number of an infiltration of hemocytes in the susceptible snails was 2 and in the resistant snails was 14. Similarly, total number of an encapsulations in the susceptible snails was 7 and in the resistant snails was 28. Total number of cysts formed in the susceptible snails was 21 and in the resistant snails was 85.

When *S. mansoni* MI penetrate resistant individuals of snail *B. glabrata*, the MS is killed (Bayne et al., 1980 a). These results are in agreement with the present study.

However, complete destruction of the MS was observed in the foot, head, lip, tentacles, mantle, mantle rim and gut of the of resistant snails.

The data regarding the mean diameter of the various host responses is scanty and has not been mentioned in the literature. In the present study detail account of the mean diameter ( $\pm$  SEM) of the various host responses appeared in the certain organs of the susceptible and resistant snails during the infection period was recorded.

*CHAPTER NO.3*



**Histopathological studies of the snails of *Biomphalaria glabrata* due to the daughter sporocysts and cercariae of *Schistosoma mansoni*.**

**Abstract**

Susceptible, resistant, and giant snails have been studied for the development of the daughter sporocysts (DS) and cercariae (C) plus host responses in the various organs. At 9 and 10 DPE few DS were observed in the posterior viscera which include gut or pre-intestine, digestive gland, and ovotestis or gonad of the susceptible snails. No such development was seen in the resistant snails. The highest level of the infection was observed at 15, 20 and 30 DPE in these snails, which was 100 percent. The DS increased in number, multiplied and migrated in the deeper tissues of above organs at 15 DPE. In the digestive glands greater number of the DS (240 and 210) were observed on 30 and 40 DPE respectively. In the susceptible snails the range of the number of the DS found in the gut was 1-28, in digestive gland 1-240 and in ovotestis it was 1-125. Whereas, in resistant snails sections were made only on 9, 10 and 40 DPE. No DS was observed on 9 and 10 DPE, however, in later infection at 40 DPE the number of the DS visible in the gut were 55 and in the digestive glands of the resistant snail they were 9. The total number of the infected susceptible and resistant snails and DS found in the various organs were counted. Chi-square test results shows highly significant difference between the infected susceptible and resistant snails and DS found in the gut, digestive glands and ovotestis of the snails ( $\Sigma X^2_{(3)} 511.9, P < 0.001$ ).

The convoluted, longitudinal and broad shaped DS exhibits thick red tegument with spines at 9 DPE. Initially germinal cells were smaller then they increased in size, contained round or oval nucleus with prominent dark nucleoli in the center. At 20 DPE mature DS found in the former two organs of these snails contained several germballs of the cercaria, tegument with prominent nuclei of cells, increase vacant spaces and in few early developments of the cercaria was observed. The oval or irregular shape of germballs showed thin tegument, filled with several germinal cells containing little cytoplasm and nucleus. The head region, pre and post-acetabular and penetration glands and short tail region of the cercariae were also visible within the body of the DS. This stage further developed in digestive gland and ovotestis, matured and free cercariae were visible in the susceptible snails at 30 and 40 DPE respectively. During these developments few areas of an infiltration of hemocytes was visible in these organs. In the digestive glands thin walls and overgrowth was also prominent. Atrophy of the acini of



the ovotestis was observed in these snails. At 30 DPE in the anterior surface of the foot of giant snails few mature DS containing few germballs and some encapsulations of the cercariae were visible. Infiltration of hemocytes was also visible in the tentacle of the snails. Few cysts were also observed in the foot of the snails. Enormous numbers of the DS and normal cercariae were observed in the digestive glands and ovotestis of these snails. Whereas, in the gut of the resistant snails at 40 DPE some mature DS contained several germballs of the cercaria. These germballs of variable sizes and shapes and in few early cercariae were found. The mean diameter ( $\pm$  SEM) of the DS, germballs, head and body regions of the cercaria and host responses found in the various organs of the susceptible, resistant and giant snails was also recorded. The range mean diameter of the DS found in the gut, digestive gland and ovotestis of the susceptible snails was  $33.01 \pm 4.41 \mu\text{m}$  to  $238.79 \pm 19.08 \mu\text{m}$ . The range mean diameter of the germballs of the cercaria found in the digestive gland and ovotestis of the susceptible snails was  $48.95 \pm 8.05 \mu\text{m}$  to  $69 \pm 8.85 \mu\text{m}$ .

### 3.1) Introduction

In the *S. mansoni*-*B. glabrata* combination, the production of new generations by the DS occurs as a normal mode of larval multiplication of the schistosome during its intramolluscan development (Jourdan et al., 1980). DS differentiating from MS, migrate to the digestive gland on or about 12 DPE (Cheng, 1973). On or about the 15<sup>th</sup> day after infection the DS begins to leave the MS (Wajdi, 1966). Histological examination of many sectioned Lac stock snails of *B. glabrata* revealed that DS could easily be found in the digestive glands and ovotestis from 17-20 DPE (Lewis et al., 1993). *A. glabratus* mass exposed on a single occasion to MI of *S. mansoni* 18 DPE, DS began to leave the surviving MS, and during the next 2-3 weeks, the latter degenerated (Pan, 1965). At 19 DPE DS had become established in small numbers in the digestive gland, at the digestive gland/gonadal interface and to a limited extent, in the gonadal itself. Groups of parasites were also found at the posterior most portion of the gonad at 23 DPE. At 40 DPE parasites were located among the tubules of the both digestive gland and gonad; no parasite were found inside either type of the tubules (Crews et al., 1989). Susceptible snails are those which allow successful schistosome development and emergence of cercariae (Lie et al., 1977). The susceptibility of mollusc to trematode infection has been shown to be affected by the sexual condition (Wright, 1971) and age of the snails (Lo, 1972; Richards, 1984).

The DS looks like a thin walled bag, made up of collagen-like fibers and packed tightly between the epithelia of the adjacent tubules of the digestive gland (Kinoti et al., 1971). Most of the DS are vermiform motile sacs, make their way rapidly through the tissues of the host in the direction of their final site of location, the digestive glands. They settle in the interfollicular connective tissues and many may move into the ovotestis where they will also develop (Wajdi, 1966; Schutte, 1974b).

Morphoanatomic changes occur in the development of the *S. mansoni* DS by a sectorization of the larval stage. Three sectors can be distinguished: an anterior zone with well differentiated birth pore; dilated zone containing the developing cercariae, and constricted zone without cercarial embryos. The electron microscopic studies showed variations in the tegumental structures of these sectors (Theron, 1985). The anterior third of the DS is cone shaped and is particularly heavily invested with musculature and spines. The nature of these structures strongly suggests that they are devices enabling the active migration of the DS through tissues (Pan, 1963). The DS has the typical syntical trematode tegument connected to the nucleated subtegumental cells. The younger DS

probably have a thicker tegument with numerous microvilli and extensive muscular system. The outer longitudinal and inner circular muscular layers are found in the excretory system of flame cells (Rifkin, 1970).

Migrating DS are usually filled with germinal cells held in matrix formed by their processes. The sporocyst do not develop further during transit, except that an occasional organism may develop vacuoles containing several germballs (Pan, 1963). Mature DS and cercariae normally occupied much space of gonadal acini (Crews et al., 1989). The largest DS within the body of the MS are about the size of migrating DS  $57 \times 21 \mu\text{m}$  (Pan, 1963). The vermiform motile DS measuring  $150\text{-}250 \mu\text{m}$  in length (Wajdi, 1966). Unbranched mature DS are  $1.5 \times 0.1 \text{ mm}$  in length (Meglitsch, 1967).

### **Cercaria**

The cercaria is a more advanced larva, containing most of the adult organs, the larval organs disappears during metamorphosis after penetration (Meglitsch, 1967). The cercariae of the human schistosomes possess two suckers, one situated at the anterior end of the body and the other towards the middle of the ventral surface of the body (Gordon et al., 1934). The broad fluke like body of the cercaria ends in a muscular tail variable in form and distinctive in the principal trematode groups. Digestive, nervous and protonephridial systems are well developed. Propagatory cells assemble to form the primordia of the reproductive organs and many unicellular penetration glands are usually present (Meglitsch, 1967). The cercarial spines are thought to assist in penetration through the skin (Robson and Erasmus, 1970; Rifkin, 1971). The oral suckers is deep, funnel shaped, heavily muscular organ, imbedded in the anterior one-third of the cercariae. The small acetabulum may be regarded as a protrusion of the body wall to form a saucer-like sucker, the narrow base (neck) of which is located ventrally on the body wall of the cercaria two-thirds of the way from its oral end (Pan, 1965).

### **Host responses**

Growth of the DS in the interlobular spaces of the digestive glands leads to displacement of the lobes and loss of their branched structure with subsequent degeneration of the epithelium lining the tubules (Wright, 1966a). The DS which mature in the digestive glands apparently provoke a reaction which is intermediate between the focal and generalized type of tissue response; "extensive infiltration of hypertrophic hemocytes around the parasite (Pan, 1965). Localize starvation or autolysis around the

distal ends of the digestive glands tubules where the lumen of the tubule is closed by the external pressure of the DS (James, 1965). A histological study of more compatible host-parasite systems, cercariae emboli have not been observed and extensive tissue reaction appears later in course of infection. At least during the pre-patent stages of infection, such changes are either relatively minor, or affect primarily the non-vital reproductive organs in a compatible host (Schutte, 1975). A high mortality of susceptible snails was noted at some one or two weeks after cercariae begin emergence from the snails. Which produced a marked generalized and proliferative tissue reaction, which was incited by cercariae trapped and dying in the loose vesicular tissue. Infected snails was attributable to mechanical damage caused by migrating cercariae, proliferating connective tissue elements with attendant disruption of normal tissue function, disturbances of blood flow due to emboli consisting of degenerating cercariae and loss of digestive glands function (Pan, 1965).

#### **Aims and objectives of the present work**

To determine the distribution of the DS in the various organs of the susceptible, resistant and giant snails.

To study the development of the DS in the various organs of the susceptible, resistant and giant snails.

To determine the mean diameter of the DS in the various organs of the susceptible, resistant and giant snails.

To study the appearance of the cercaria in the susceptible, resistant and giant snails.

To determine mean diameter of the germballs, head and body regions of the cercariae in the susceptible and resistant snails.

### **3.3) Materials and methods**

#### **3.3.1) Source of materials**

The source and details of the animals are described in earlier chapter No. 1. On each of the following experimental days 10 animal were fixed and a total of 30 susceptible, 15 resistant and 3 giant snails were histologically processed on 9, 10, 15, 20, 30 and 40 DPE. During the experiment the mortality of the 2 susceptible snails each occurred on days 15, 20, and 30 and a mortality of 4 animals was observed after 40 DPE.

#### **3.3.2) Methods**

The infected snails were relaxed, fixed, dehydrated, infiltrated and embedded as mentioned in the chapter 1. The animals were dissected in to anterior and posterior portions, which consists of head-foot region and gut, digestive glands and ovotestis.

### 3.4) Results

#### 3.4.1) Distribution of the DS in the snails

The results for the distribution of *S. mansoni* DS in the various organs of the susceptible and resistant snails is presented in the Table No. 3.1. The range of the percentage of the infection found in the susceptible snails was 40-100%. The highest level of the infection was observed at 15, 20 and 30 DPE in these snails, which was 100 percent. In the digestive glands greater number of the DS (240 and 210) were observed on 30 and 40 DPE respectively. However, in case of the resistant snails at 40 DPE 60% of infection was noted and no infection was seen on 9 and 10 DPE. In the susceptible snails the range of the number of the DS found in the gut was 1-28, in digestive gland 1-240 and in ovotestis was 1-125. Whereas, in resistant snails sections were made only on 9, 10 and 40 DPE. No DS was observed on 9 and 10 DPE, however, in later infection at 40 DPE the number of the DS visible in the gut were 55 and in the digestive glands of the resistant snail they were 9.

Table No.3.1 Distribution of the daughter sporocysts in the various organs of the susceptible and resistant snails of *Biomphalaria glabrata*.

DPE	Snails	Experimental snails	Percentage		No. of DS in infected organs		
			Positive	(%)	Gut	Digestive gland	Ovotestis
9	S	5	2	40	1	2	1
	R	5	-	-	-	-	-
10	S	5	3	60	1	1	1
	R	5	-	-	-	-	-
15	S	5	5	100	28	52	28
20	S	5	5	100	-	56	112
30	S	5	5	100	-	240	125
40	S	5	4	80	-	210	110
	R	5	3	60	55	9	-
Total	S	30	24		30	561	377
	R	15	3		55	9	-

The total number of the infected animals and DS found in the various organs of the snails were counted (Table No. 3.2). There are 24 infected susceptible animals, the number of the DS present in the gut, digestive glands, and ovotestis was 30, 561 and 377 respectively and their total was 992 (n = 992). Whereas, only 3 infected resistant animals, the number of the DS present in the gut, and digestive glands was 55 and 9 respectively (n = 67). Analysis of the data for chi-square test shows highly significant number of the DS present in the gut, digestive glands and gut of the susceptible and resistant snails ( $\Sigma X^2_{(3)} = 511.9, P < 0.001$ ).



Table No. 3.2 Chi-square test based on the number of the infected animals and daughter sporocysts present in the various organs of the susceptible snails.

Snails	No of infected animals	No. of the daughter sporocysts			Total
		Gut	Digestive gland	Ovotestis	
Susceptible	24 (25.29)	30 (79.62)	561 (533.95)	377 (353.15)	992
Resistant	3 (1.71)	55 (5.38)	9 (36.06)	- (23.85)	67
Total	27	85	570	377	1059

$(\Sigma X^2_{(3)} 511.9 (P < 0.001).$

### **3.4.2) Histology of the DS found in the various organs of the snails**

#### **Gut of the susceptible snails**

DS are visible in the gut of susceptible snails at 9, 10 and 15 DPE. The structures of the DS are similar as described in the digestive glands of these animals.

#### **Gut of the resistant snails**

At 40 DPE several mature DS were developed in the outer muscular layers of the gut of snails. The structures of the DS, germballs of variable shapes and sizes is similar as mentioned in figure 8b.

#### **DS and host response in the digestive glands of the susceptible snails**

At 9 DPE single convoluted DS is visible in the blood space between the walls of the digestive glands. The DS exhibits thick red tegument, little space, most of the body is filled with small sized of darkly stained germinal cells. The germinal cells possess round or oval nuclei with dark nucleoli and less cytoplasm. The normal epithelium of the walls of the digestive gland and few connective tissue cells were present close to the parasite (Fig. 7a). Two elongated DS are found in between the digestive gland at 10 DPE. These DS are characterized by thick red tegument with cells, increase vacant spaces and germinal cells in the body. The germinal cells are either single, double or in groups of four. Now the size of germinal cells and cytoplasm has increased and they are darkly stained. Few connective tissues are observed in the vicinity of the parasites (Fig. 7b). At 15 DPE few multiple DS with thick tegument and vacant spaces are found in between walls of the digestive glands. Within the body of the DS formation of oval or flat types of germballs of cercaria has been initiated. The thin or compressed walls of the digestive glands and connective tissues were close to the organisms (Fig. 7c).

#### **DS and host response in the digestive glands of the resistant snails**

No DS is visible in the resistant snails at 9 and 10 DPE. However, at 40 DPE in the digestive glands of these snails single thin elongated DS are found. The structure of the DS is similar as described earlier in the susceptible snail figure 7a. However, some of the overgrowth and thin walls of the digestive gland are observed due to the presence of the DS (Fig. 7d).

#### **Digestive glands of the giant snails**

Mature DS are also visible in the digestive glands of these snails at 30 DPE and their structure is same as described above.

### **Ovotestis of the susceptible snails**

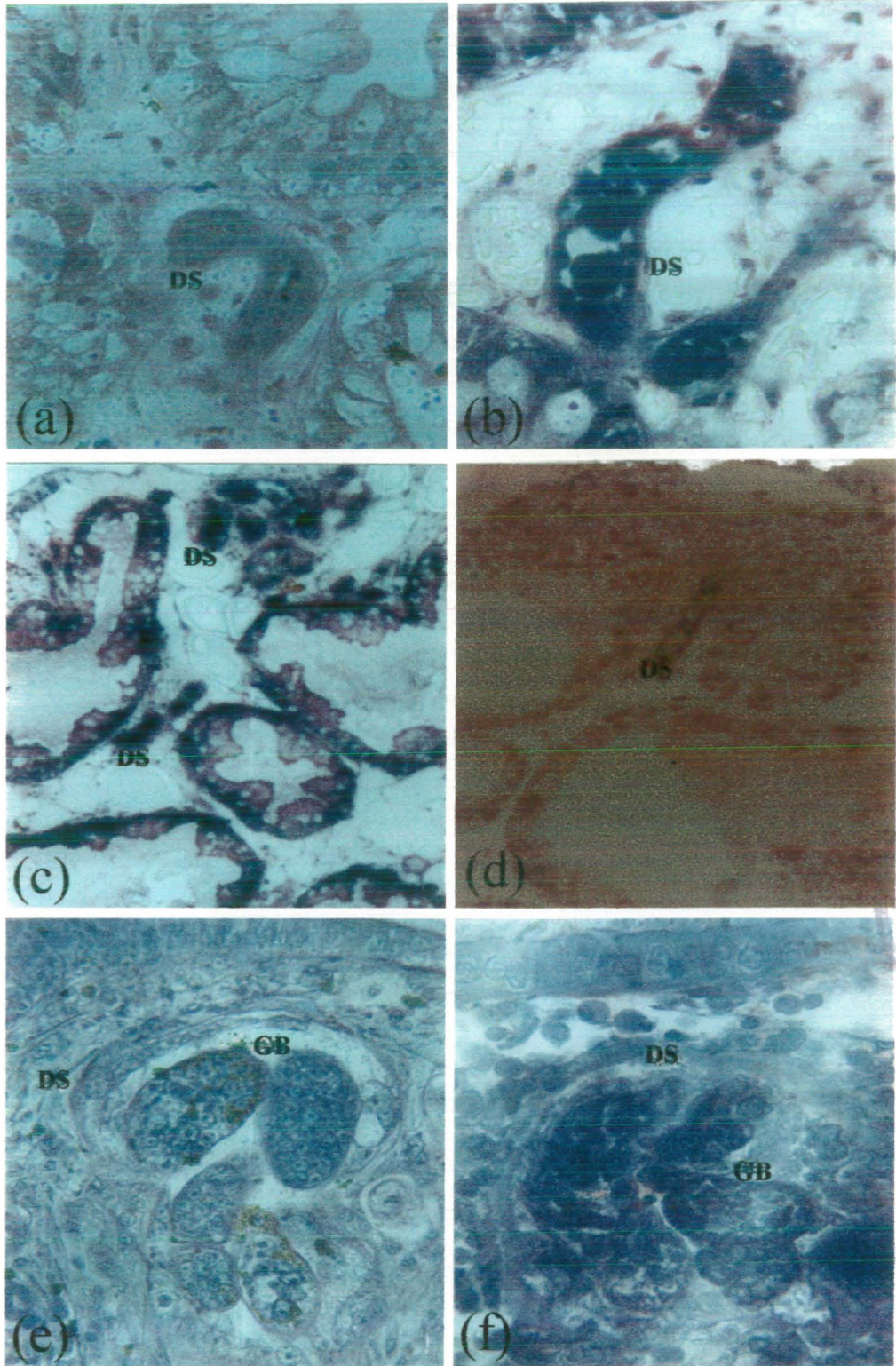
Single thin DS was found in the outer layer of the ovotestis of the snail at 9 DPE. Which exhibits thick tegument, few germinal cells, stained red and connective tissues cells are close to the parasite. At 10 DPE elongated DS had moved further to the middle region of the ovotestis. This DS is characterized by the thick tegument, few darkly stained germinal cells and connective tissues cells are close to the parasite.

### **Foot of the giant snails**

Mature DS are visible in the anterior surface of the foot of above snails at 30 DPE. Few germballs and vacant spaces were visible in the body of these DS. They were characterized by thin tegument and increased size of germinal cells. No cellular reaction were visible around these parasite. The outer epithelial layer of the foot and cilia are normal (Fig. 7e).

### **Other organs of the resistant snails**

After 40 DPE normal mature DS developed in the anterior surface of the foot of snails. The structure of the DS and germballs is same as described earlier and no cellular reaction was visible (Fig. 7f). Mature DS were also observed in the kidney, and albumin glands of these snails. The mean diameter of the DS found in the kidney of the resistant snails was  $37.49 \pm 12.45 \mu\text{m}$ .



**Fig.7 Development of the *Schistosoma mansoni* daughter sporocysts (DS) in the snails.**

**a, b and c** Single, multiple and mature DS were visible in the digestive glands of the susceptible snails after 9, 10 and 15 DPE (416 X and 228 X).

**d** Only single DS was seen in the same organ of the resistant snails at 40 DPE (228 X).

**e and f** In the foot of the giant and resistant snails after 30 and 40 DPE mature DS were visible (416 X). GB = Germ balls.

### 3.4.3) Mean diameter of the DS found in the susceptible and resistant snails.

The results for mean diameter ( $\pm$  SEM) of the DS in the gut, digestive glands, and ovotestis of the snails is presented in Table No. 3.3. The range of the mean diameter of the DS in the gut was  $33.01 \pm 4.41 \mu\text{m}$  and  $75.80 \pm 11.37 \mu\text{m}$ , in digestive gland  $37.49 \pm 2.16 \mu\text{m}$  and  $238.79 \pm 19.08 \mu\text{m}$  and in ovotestis of the susceptible snails was  $48.90 \pm 6.16 \mu\text{m}$  and  $177.67 \pm 20.69 \mu\text{m}$ . The maximum mean diameter of the DS was recorded  $238.79 \pm 19.08 \mu\text{m}$  in the digestive glands of the susceptible snails on 40 DPE. However, in the resistant snails the mean diameter of the DS in the gut was  $90.18 \pm 4.95 \mu\text{m}$  and in digestive glands  $33.74 \pm 3.89 \mu\text{m}$  at 40 DPE. The mean diameter and number of the *S. mansoni* germballs of the cercariae in the mature DS in the various organs of the susceptible snails of *B. glabrata* are presented in Table No. 3.3.1. The mean diameter of the germballs of the cercaria visible in the digestive glands ( $48.95 \pm 8.05 \mu\text{m}$ ) and ovotestis ( $52.29 \pm 5.12 \mu\text{m}$ ) was lesser at 15 DPE, whereas, it was higher mean diameter of germballs in these organs at 20 DPE ( $68.45 \pm 4.25 \mu\text{m}$  and  $69 \pm 8.85 \mu\text{m}$ ).

Table No. 3.3 Mean diameter ( $\pm$  SEM) of the *Schistosoma mansoni* daughter sporocysts in the various organs of the susceptible and resistant snails of *Biomphalaria glabrata*.

DPE	Snails	Gut ( $\mu\text{m}$ )	Digestive gland ( $\mu\text{m}$ )	Ovotestis ( $\mu\text{m}$ )
9	Susceptible	33.01 $\pm$ 4.41	37.49 $\pm$ 2.16	48.90 $\pm$ 6.16
	Resistant	-	-	-
10	Susceptible	47.27 $\pm$ 3.56	47.27 $\pm$ 2.94	57.86 $\pm$ 14.71
	Resistant	-	-	-
15	Susceptible	75.80 $\pm$ 11.37	97.19 $\pm$ 9.06	82.31 $\pm$ 3.26
20	Susceptible	-	105.13 $\pm$ 23.02	106.36 $\pm$ 15.12
30	Susceptible	-	194.99 $\pm$ 21.21	150.98 $\pm$ 12.84
40	Susceptible	-	238.79 $\pm$ 19.08	177.67 $\pm$ 20.69
	Resistant	90.18 $\pm$ 4.95	33.74 $\pm$ 3.89	-

Table No. 3.3.1 Mean diameter ( $\pm$  SEM) and number of the germballs of the cercariae in the mature daughter sporocysts in the various organs of the susceptible snails.

DPE	Digestive gland		Ovotestis	
	Diameter ( $\mu\text{m}$ )	Number	Diameter ( $\mu\text{m}$ )	Number
15	48.95 $\pm$ 8.05	4	52.29 $\pm$ 5.12	4
20	68.45 $\pm$ 4.25	5	69 $\pm$ 8.85	3

### 3.4.4) Histology of the cercariae in the various organs of the snails

#### Development of cercariae and host responses in the snails

Mature DS are characterized by thick tegument with cells, vacant spaces throughout body, prominent anteriorly placed penetration glands, darkly stained and closely packed nuclei of germinal cells of germballs of the cercaria. In the ovotestis of susceptible snails after 20 DPE within the body of the mature DS variable size and shape of germballs and various developing stages of the cercaria are visible. In few DS formation of head, body regions and penetration glands of the cercaria are visible. In addition to these in few cercariae tail formation has also been initiated. The acini of the ovotestis possess spermatogonia with darkly stained nuclei at the periphery. Whereas, the lumen of the acini showed various stages of the spermiogenesis. No any reaction of the hemocytes appeared in this stage of the development (Fig. 8a).

A similar development of the parasites was also noticed in the digestive glands of the susceptible snails at 20 DPE. In the gut of resistant snails at 40 DPE mature DS containing several germballs and few early formation of cercaria are visible. The structure of the parasite in the gut (Fig. 8b) is similar as described earlier in the ovotestis. However, strong hemocytes reaction was observed around the DS. As the development of the cercaria proceeds on 30 DPE in the digestive glands of susceptible snails. In the head and body regions of the cercaria exhibits oral sucker, pre and post-acetabular glands. Muscular bifurcated tail region were also formed during this period of infection. In the head region of the cercaria shows the staining reaction pink penetration glands, light blue color pre and post-acetabular glands. Few germballs, mild hemocytes reactions and atrophy of the digestive gland was prominent close to these developing stages of the parasite (Fig. 8c).

A similar development of the parasites was also noticed in the ovotestis of the susceptible snails at 30 DPE. Whereas, on 40 DPE few germballs and many mature cercariae were found in the ovotestis of the susceptible snails. Mature or free cercaria contained prominent head, body and tail region. Free cercariae are visible adjacent the wall of the ovotestis at 40 DPE. Within the ovotestis mild hemocytes reaction, cyst and atrophied acini are clearly visible (Fig. 8d).

A similar development of the parasites was also noticed in the digestive glands of the susceptible snails at 40 DPE. At 30 DPE the mean diameter of the head and body regions of the mature cercaria found in the digestive glands was  $135.33 \pm 17.5 \mu\text{m}$  and

343.83 ± 30.13 µm respectively. At 40 DPE the mean diameter of the head and body regions of the free cercaria found in the ovotestis of the susceptible snail was 175.83 ± 20.66 µm and 345.83 ± 28.95 µm respectively.

#### **Cercaria and host responses in the giant snails**

Enormous numbers of the mature cercariae were observed in the digestive glands and gonad of these snails after 30 DPE. The head, body of the cercaria, penetration glands, ventral sucker and muscles were visible. No cellular reaction was noticed around the cercariae present in these areas. However, some encapsulations of the cercariae were visible in the anterior surface of the foot of the snails. Few infiltration of hemocytes and granulomas were also visible in the foot of the snails. The mean diameter of the granuloma was 47.25 ± 6.25 µm.

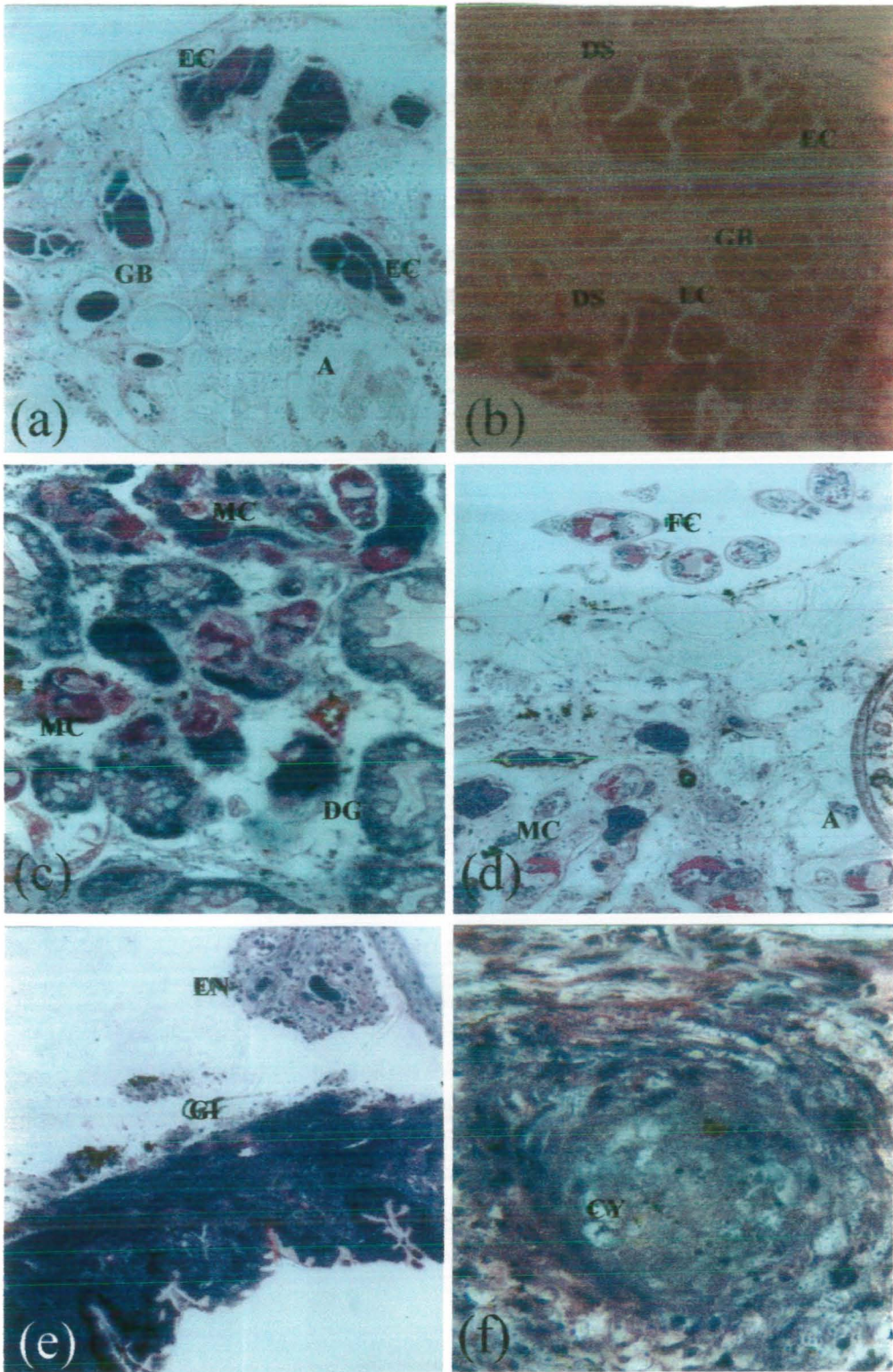
#### **Host responses in the gut and gizzard of the resistant snails**

An infiltration of the hemocytes was visible in the gut of these snails at 40 DPE. An encapsulation of few mature DS was visible close to the muscular wall of the gizzard at 40 DPE. The dark germballs of variable size and shapes were surrounded by strong reactions of the hemocytes (Fig. 8e). Few cysts were also found in the gut of the above snails at 10 and 40 DPE.

#### **Host responses in the gut of the susceptible snails**

At 10 DPE circular cyst was found in the muscular wall of the gut of susceptible snail. The cyst is characterized by complete destruction of the parasite, necrotic spaces and several hemocytes with dark nuclei at the outer periphery (Fig. 8f).





**Fig. 8 Development of the *Schistosoma mansoni* cercaria and host responses in the snails.**

**a and b)** In the ootestis of the susceptible and gut of the resistant snails mature DS have germ balls and early cercariae (EC) at 20 and 40 DPE (228 X).

**c and d)** Mature and free cercariae were seen in the digestive gland and ootestis of the susceptible snails after 30 and 40 DPE (228 X).

### 3.4.5) Discussion

In this study three groups of snails (susceptible, resistant and giant) have been studied for the development of the DS, cercaria and host responses after 9 DPE onwards. Wright, (1966a); Schutte, (1974b) has reported that the DS leave the mother, migrate partly carried along by the blood stream, to the digestive gland and ovotestis area. In the blood lacunae between the lobes of the digestive glands they develop. The result of the present findings regarding the digestive gland and ovotestis area is in agreement with the above research workers. However, DS was also present in the gut of the susceptible snails at 9 DPE. Soomro (1996) has reported that no parasite could be detected in the digestive gland or ovotestis of the *B. glabrata* snails at 11 DPE. In contrast to Soomro's findings in this study DS was detected in the digestive gland and ovotestis of the susceptible snails after 9 DPE. Becker (1968) has reported that the DS of *S. mansoni* first begin to migrate to the molluscan host's digestive gland approximately 12 days after exposure to miracidia. Wajdi (1966) has reported that on or about the 15 DPE the DS begins to leave mother. Pan (1965) has reported that *S. mansoni* DS begins to leave surviving mother in *A. glabratus* snails at 18 DPE. In the present study migration of *S. mansoni* DS was observed in the susceptible snails earlier (at 9 DPE) than previously mentioned researchers. Crews et al., (1989) reported that by day 19 DS had become established in small numbers in the digestive glands, at the digestive gland/gonadal interface and to limited extent, in the gonad itself. Lewis et al., (1993) have reported that from 17-20 DPE secondary sporocysts were detected in the digestive glands and ovotestis of the fully susceptible snails of *B. glabrata*. Pan (1963) has reported small numbers of the DS in transit in the digestive gland in 18 DPE, much larger numbers of DS were present in the digestive gland in 21 days or more post-infections. In the present study few DS was visible at 9 and 10 DPE and increasing numbers of the multiple DS in the gut (28), digestive gland (52) and ovotestis (28) of susceptible snails from 15 DPE onwards.

Wajdi (1966) has reported that most of these vermiform motile sacs make their way rapidly through the tissues of the host in the direction of their final location, the digestive glands of *A. glabratus*. Kinoti et al., (1971) has reported that in section the DS looks like a thin walled bag packed tightly between the epithelia of the adjacent tubules of the snail digestive gland. In the present study thin elongated and irregular or convoluted DS were observed in muscles of the gut, between the walls of the digestive gland and ovotestis area of the susceptible snails of *B. glabrata* at 9 DPE. Pan, (1965)

has reported the largest DS within the MS are about the size of migrating DS. Migrating DS were usually filled with germinal cells held in matrix formed by their processes. In the present study most of the body of the DS was filled with these cells, tiny spaces, and thick tegument and spines.

Dawes, (1946) has reported that germballs developed in the DS in the digestive glands of the snails. Pan, (1965) has reported that after 21 DPE formation of cercarial germballs are associated with the vacuoles in the DS. In the present study within the body of the mature DS variable shapes and sizes of the germballs of the cercariae were seen in the digestive gland and ovotestis of the susceptible snails after 15 DPE and onwards. Additionally, mature DS are also visible in the anterior surface of the foot and digestive glands of the giant snails at 30 DPE. However, in the anterior surface of the foot and gut of resistant snails after 40 DPE normal mature DS containing few germballs of the cercaria. Meglitsch, (1967) has reported that the unbranched mature DS are 1.5 mm X 0.1 mm in length. Schutte, (1974b) has described that the DS looks like vermiform larvae and measuring 150-250  $\mu\text{m}$  in length. In the present study DS is irregular, thin elongated and broad shaped in the gut, digestive gland and ovotestis of the susceptible and resistant snails. At 40 DPE the maximum mean diameter ( $\pm$  SEM) of the DS found in the digestive glands and ovotestis of the susceptible snails is in same range as reported by Schutte, which was  $238.79 \pm 19.08 \mu\text{m}$  and  $177.67 \pm 20.69 \mu\text{m}$  respectively.

Miracidia penetrate in susceptible snails and differentiate into sporocysts. These forms exhibit extensive proliferation, remaining viable and active, producing great number of the *S. mansoni* cercariae (Borges et al., 1998). In the present study also enormous number of mature cercariae were visible in the digestive gland and gonad of the susceptible snails at 30 DPE. Additionally, in the giant snails mature cercariae were also visible in the foot, digestive glands and ovotestis at 30 DPE. Gordon et al., (1934) have reported that range of length and width of the body was 150-180  $\mu\text{m}$  and 59-73  $\mu\text{m}$  of the *S. mansoni* cercariae respectively. In the present study the diameter of the head region of the *S. mansoni* mature and free cercaria was  $135.33 \pm 17.05 \mu\text{m}$  and  $175.83 \pm 20.66 \mu\text{m}$  at 30 and 40 DPE respectively. Pan, (1965) has reported that the tegumental wall of the mature cercaria consists of 3 layers: an outer circular muscle covered with numerous minute spines; a middle circular muscle layer, and an inner longitudinal muscle layer. In the present study similar finding were reported. Pan, (1965) has reported

penetration glands consists of several pairs of large, "retort-shaped" cells clustered in the caudal two-thirds of the cercarail body. Each individual penetration gland acts as a secretory unit. In mature and in occasional immature cercariae, there are four pairs of glandular cells and stain with PAS. In this study such glands are visible in immature, mature and free cercariae after 20 DPE onwards. They also stain strongly for PAS positive material.

Pan, (1963) has reported some hypertrophic fibroblasts surrounded the parasite and congestion of blood sinuses were observed in the digestive glands during the maturation of the DS. In the present study during development of the mature DS and cercaria hemocytes surrounded by the parasites, congestion of the blood vessels and atrophy of the digestive glands of the susceptible snails was visible. Wright, (1966a) has reported that growth of the DS in the interlobular spaces of the digestive gland leads to displacement of the lobes and loss of their branched structure with subsequent degeneration of the epithelium lining the tubules. In the present study due to the appearance of the multiple and mature DS in the susceptible snails thin or compressed walls after 15 onwards and displacement of the digestive glands was noticed in the resistant snail close to the organisms at 40 DPE. Wright (1966a) has reported that increase number of hemocytes are most pronounced in the presence of cercariae and particularly where emboli are formed in the vessels by groups of larvae. In the present study at 30 DPE due to the presence of DS and cercaria also increase number of the hemocytes in the gut, digestive gland and ovotestis of the susceptible snails. Increased number of these cells was also noticed in the gut of the resistant snails after 40 DPE. Scanty information is available regarding the mature and free cercariae particularly present in the ovotestis of the susceptible snails. Mature and free cercariae were found in the gonad of the snails at 40 DPE. Around mature cercaria hemocytes reaction and cyst formation was visible.

*CHAPTER NO.4*

**Histopathological studies of the ovotestis of the susceptible snails of the *Biomphalaria glabrata*, intermediate host of *Schistosoma mansoni*.**

**Abstract**

Histopathology of ovotestis of the unselected susceptible ordinary (Albino) snails of *Biomphalaria glabrata* the intermediate host of *Schistosoma mansoni* were studied after 9, 10, 15, 20, 30 and 40 DPE. The ovotestis was composed of transverse, longitudinal and irregular shapes and sizes of acini in the sectioning material and collecting canal. The number and mean diameter of the various types of the acini was recorded. In *S. mansoni* infection the highest mean diameter of the acini was  $312 \pm 28.76 \mu\text{m}$  at 20 DPE. At 30 and 40 DPE infection of the mature DS and cercariae was progressing in the ovotestis of the snails. The acinus is surrounded by a thin outer layer and wide lumen. The outer layer or sidewall of the acini had very thin nuclei of the cells, and its inner side showing various developing stages of the few female and many male germinal cells. After detailed histological examination four types of female germinal cells were recognized. They are early oogonia, previtellogenic, stage I and II vitellogenic oocytes. Few atretic oogonia were also found during the infections. After 9, 10 and 30 DPE the highest number of the previtellogenic oocytes and stage II oocytes was 37, 29, and 22 and 31, 30 and 19 respectively. Early oogonia are very thin elongated, few in number, mostly located in the sidewall of the acinus, surrounded by dark thin outer membrane and possess scanty cytoplasm at 9 DPE. Atretic oogonia are surrounded by prominent outer membrane, filled with strongly dark cytoplasm with few vacuoles. In this oogonia increased space is observed between plasma membrane and ooplasm. The nucleus of the oogonia is not visible. Normal previtellogenic oocytes are spindle, elongated and oval shaped with darkly stained homogenous cytoplasm and spherical nucleus with one or two nucleolus. The stage I oocytes are mostly quadrilateral and triangular in shape. They are located close or below the stage II vitellogenic oocyte at the dorsal regions and sidewalls of the acini. The stage I vitellogenic oocyte is surrounded by few nurse cells with thin nuclei. These oocytes show prominent plasma membrane, dark vacuolated cytoplasm with yolk deposition and round nucleus. The stage I and II vitellogenic oocytes were surrounded by thin nuclei of the nurse cells and a follicular cavity. Normal stage II vitellogenic oocytes are round, triangular, and oval or irregular in shape. They are many in number, increasing in size and located mostly in the proximal and few in the lumen of the acinus at 9 DPE. They are greater in size as compared to

stage I oocytes. Increase yolk deposition in the cytoplasm of this oocyte is observed as compared to earlier stages types of the oocytes. In early stage of the development oocyte has distinct plasma membrane, dark vacuolated yolky cytoplasm is observed. The oocytes possess the prominent plasma membrane, has increased dark amount of vacuolated yolky cytoplasm. Their nuclei are hook shaped with prominent nucleolus in the centre. The nurse cells on the outer periphery of the stage II oocytes are plumper elongated in shape. Their nuclei possess compact granular chromatin. Between the oocyte and peripheral nurse cells a clear gap is observed. The number of the previtellogenic and stage II vitellogenic oocytes was increased in number at 9 and 10 DPE. The nuclei, chromatin and nucleoli of the both types of these cells were stained darkly. The degeneration of the early and previtellogenic oocytes and severe damage of stage I and II oocytes were noticed in later infections.

In the early infection above types of the female germinal cells plus several spermatogonia, spermatocytes, spermatids and mature sperms were visible in the acini of the ovotestis. The spermatogonia are of variable shapes and sizes, with spherical or oblong nuclei containing one, two or greater number of darkly stained nucleoli. Within the lumen of the acini spermiogenesis was also observed. After completion of meiosis round or oval or cuboidal and elongated shaped spermatids are visible in the acini along the sidewalls. The spermatids contained light cytoplasm with patches and centrally placed nuclei are entirely dark round or oval. With the subsequent development there is elongation of spermatids with the result that the nuclei are visible towards the sidewall and the cytoplasmic portion, which is vacuolated towards the lumen. During the maturation of the sperm exhibit dark curved head and light thin elongated tail with PAS positive material distributed in the tail region. The wall of the acinus possesses very thin cells with spindle shaped nuclei. These bundles of sperms are attached with the Sertoli cells. The nucleus of Sertoli cells is large, very conspicuous, spherical and rich in chromatin material. Its nucleus possesses two nucleoli. The mature sperms have thin straight elongated head with thin neck and long thread like tail. In later infections most of acini were poorly developed, hypertrophied almost empty lumen, abnormal oogonia, previtellogenic, stage I and II vitellogenic oocytes and swollen male germinal cells. In acini occasional spermatogonia, spermatocytes and spermatids disappeared but few bundles mature sperms were observed.

#### 4.1) Introduction

Animal that has both male and female organs in the same individual is called hermaphrodites and the condition is called hermaphroditism. Many invertebrates have reproductive systems as complex as those of the vertebrates, as shown by flatworms, snails, earthworms and others (Hicken, 1970). Pulmonate snails may be identified by the characters of the reproductive system. Few anatomical and histological studies of reproductive organs of *A. glabratus* have been reported previously (Baker, 1945; Hunbendick, 1955; Paraense and Deslandes, 1955; Pan, 1958; 1965). But detailed structure and development of the male and female germ cells is lacking at the light microscopic level. The normal description are essentially similar except later author mentioned the genital system of the *A. glabratus* can be subdivided into a) the common genital organs (hermaphrodite organs), b) male genitalia and c) female genitalia.

##### 4.1.1 General description of reproductive system of the snails of phylum mollusca

The reproductive system surrounds the intestine in the upper part of the foot is the gonad or ovotestis (ovary or testis). The reproductive gland, ovotestis, is located high in the shell surrounded by a coil of the digestive gland. From the ovotestis the hermaphrodite duct connects to the albumin gland, which furnishes albumin to the eggs. The hermaphroditic duct carries both eggs and sperms where the albumin gland joins the duct, two tubes, often imperfectly separated, are given off the vas deferens, which conduct sperm to the penis at the genital opening, and the oviduct, which leads to the vagina and also empties at the common genital opening. To the vagina is connected the duct of the seminal receptacle as well as the oviducal glands, the dartal sac, and the digitiform glands. A slender flagellum by which sperm are formed into spermatophores is connected to the penis (Hicken, 1970). Some previous studies have also reported the structure and functions of the female and male genital organs (spermatheca and albumin glands) of the snails by Rogers and Reeder, (1987) and Cousin et al., (1995). But the former workers have done the histochemistry and ultrastructure (SEM and TEM) of the spermatheca of *B. glabrata*. But the latter workers have reported that LAC-line strain of the snail *B. glabrata* infected by the parasite *S. mansoni* has very low susceptibility and reproductive potential. Upon examination of the reproductive tract of these snail, light and electron microscopy revealed obvious abnormalities in the albumin gland.



#### 4.1.2) Histomorphology of the ovotestis

The ovotestis, (reproductive gland) is the most important common genital organ of hermaphrodite snails. The ovotestis is occupying the innermost whorls or located in the posterior half of the body of the snail. It is peculiar in producing both types of gamete (eggs and sperms) in the same gland, which is therefore, called an ovotestis. It is a whitish lobed structure at the top of the visceral hump. From it leads a short coiled hermaphrodite duct and this passes into a longer common duct, which run forward. It is incompletely divided into male and female channels (Yapp, 1963). Epithelium covering the ovotestis<sup>is</sup> usually protected by the shell. The flat or squamous epithelial cells are characterised by having a dense deposit of brown or black pigment in the cytoplasm, which usually obscures cellular structures. This pigment, named melanin by Simroth in (1903). Many of the loose vascular connective tissue is found characteristically in the ovotestis. These cells are irregular in shape, being round, ovoid, elongate and spindle form. The nuclei are relatively small, quite regular in shape, usually round or oval, and contain few chromatin granules. Binucleated cells are seen frequently. The characteristic homogeneously staining cytoplasm may contain a fibrillar network which stain less intensely the plasma membrane, and reacts strongly with PAS suggesting the presence of carbohydrate material. The PAS positive material may<sup>be</sup> specially important in the connective tissue of ovotestis, where it is probably connected with gametogenesis (Faust, 1920). The wall of the acinus consist of thin connective tissue, two or three cells, with abundant collagenous fibres. This wall is like 'Aneel's layer' containing cells morphologically similar to fibroblasts. Germinal epithelium with a basement membrane in the ovotestis was described by Abdel-Malek (1954 a, b) in *Biomphalaria*. The germinal cells differentiate from the innermost cells of the Aneel's layer by thickening and transformation of the cytoplasm and nucleus. The female germinal cells or ova are usually located at the apices of the acini and male germinal cells are arranged along the sidewalls. The very early stages (spermatogonia) of the male germinal cells are frequently located near the atrium of an acinus. The maturing stages of the male cells generally line the wall of the acinus from the atrium toward the apex and the maturing spermatozoa attaching to the basal or Sertoli cells are close to the area where the ova are developing (Pan, 1958). Sperms are produced during most of the year, and are bound together in packets or spermatophores by the secretion of the flagellum (Yapp, 1963). The ovotestis contains

three types of somatic cells within the testicular portion: flattened myoepithelial cells defining the outer acinal wall; underlying pleomorphic follicle cells containing abundant glycogen deposits, and scattered, amoeboid cells containing lysosomal-like inclusions which are closely associated with developing sperm. The mature sperm possesses an elongated, slightly curved nucleus; a subterminal, concave acrosome with a nipple-like central projection; five spherical mitochondria and two centrioles in the middle piece; and a long flagellum (Eckelbarger et al., 1990).

Aquatic gastropods serve as intermediate hosts to many species of larval digenetic trematodes that are often extremely deleterious to the host snail either by physical destruction of host tissue (McClelland and Bourns, 1969; Crews and Esch, 1986), by releasing chemical that impair a variety of host functions, or by some combination of these effects (Wilson and Denison, 1980; Sluiter, 1981). In addition to tissue loss or damage, the developing trematode stages obtain large amounts of energy directly from the snail, and they may maintain this relationship for a long period, usually until the snail dies. This period of time represents, in terms of nutrient drain, a large cost to the snail (Becker, 1980). Even more significant to the fitness of the snail than an energetic demand is the possibility of complete castration by the parasite. This is frequently reported outcome of trematode infection and is caused when the parasite hormonally alters or physically consumes host gonadal tissue, resulting in inhibition of reproductive activity (Etges and Gresso, 1965; McClelland and Bourns, 1969; Baudoin, 1975; Loker, 1979; Wilson and Denison, 1980; Minchella et al., 1985; Hurd, 1990). The effects of parasitism on the intermediate hosts are often not known (Etges and Gresso, 1965). The susceptibility of mollusc to trematode infection has been shown to be affected by the sexual condition (Wright, 1971) and the age of snails (Lo, 1972; Richards, 1984). Shell diameter of snails infected with larvae of the blood fluke *S. mansoni* were consistently larger than those of controls in the first several weeks of an infection experiment. Later the infected snail showed stunted growth as well as physiological castration due to the infection (Pan, 1963). Infected snails grew faster than the control initially, but with commencement of cercarial shedding, the growth rate of non-infected snails exceeded that of infected ones. Snails virtually ceased to produce egg masses as cercariae were shed (Richards, 1984). Increased growth of the snail, termed gigantism, may also be beneficial to the host by allocating nutrients away from the parasite and increasing host survival (Minchella,



1985). Gigantism is frequently associated with reduced host fecundity. Parasite induced excess growth or gigantism occurs in snails infected with larval stages of schistosomes. So growth was assessed in terms of shell length and dry mass (tissue, shell and parasite). Increased mean length being related to parasite burden and associated with retardation in ovarian maturation and probable partial castration (Pearce, 1976). Inhibition of snail reproductive activity by larval trematodes often results in increased growth of the snail, termed gigantism, during which the snail is hypothesised to allocate excess energy normally used for reproduction to somatic growth (Keas and Esch, 1997). In many gastropod species infection by helminth parasite results in the reduction or complete cessation of egg production. Infection of *B. glabrata* by *S. mansoni* results in a dramatic reduction in the snail's ability to produce eggs (Cooper et al., 1996).

Trematodes, however, usually inhibit the growth of the gonads or even cause castration. Thus, parasitized snails are unable to reproduce. When the snails of *B. glabrata*<sup>are</sup> infected with larvae of the blood fluke *S. mansoni* inhibition of the snail's egg laying occurs during the fourth week of infection, before the onset of cercarial emergence. Limited egg production is resumed well before the loss of infection, about 90 to 100 days after miracidial penetration. The rate of egg production by infected snails is about 10 per cent of normal, but the eggs develop and hatch nearly usually (Etges and Gresso, 1965). The daughter sporocysts of *S. mansoni* are primarily responsible for the inhibition of host reproductive activity, and may be mediating their effects through mechanisms involved in the regulation of gonadal growth (Crews et al., 1989). Most of the snails with foot sporocysts continued to produce eggs (Lewis et al., 1993). The present study describes histopathology of the normal and abnormal changes in the acini, female and male germ cells developed in the ovotestis of the susceptible snails of *B. glabrata*, intermediate host of *S. mansoni*.

#### 4.2) Aims and objective of the present work

Normal histology of the acinus, female and male germinal cells developed in the ovotestis of the susceptible snails of *B. glabrata*, intermediate host of *S. mansoni*.

Histopathology of the acinus, female and male germinal cells developed in the ovotestis of the susceptible snails of *B. glabrata*, intermediate host of *S. mansoni*.

#### 4.3) Materials and methods

The collection, methods of infection and histological techniques used in this study are mentioned in the chapter 1. In this chapter ovotestis of susceptible snails of *B. glabrata* the intermediate host of *S. mansoni* were studied for histopathological changes at 9, 10, 15, 20, 30 and 40 DPE. For each day 12-21 sections on a slide were examined. Most of the random measurements of the various acini, female and male germinal cells were taken from the infected area of the ovotestis.

#### 4.4) Results

Study of cross sections of the infected susceptible snail reveals that the ovotestis contains transverse, longitudinal and irregular type of acini. The number of the acini was counted from the sections of the ovotestis. The number and mean diameter ( $\pm$  SEM) of the acini are presented in Table No. 4.1. Variable numbers of the acini were recorded in the sections of the ovotestis during the course of the infections. The number of the transverse acini was higher at 9 and 30 DPE. The range of numbers of the various acini such as., transverse 1-15, longitudinal 9-16 and irregular was 5-14. The random mean diameter of the various types of the acini was recorded. The range of the mean diameter of the acini was  $187 \pm 24.78 \mu\text{m}$  to  $312 \pm 28.76 \mu\text{m}$  (from 9-40 DPE). In *S. mansoni* infection the highest mean diameter of the acini was  $312 \pm 28.76 \mu\text{m}$  at 20 DPE. At 30 and 40 DPE infection of the mature DS and cercariae was progressing in the ovotestis of the snails. During these days the mean diameter of the acini was reduced.

Table No. 4.1 Number and mean diameter ( $\pm$  SEM) of the *Schistosoma mansoni* infected acini of ovotestis of susceptible snails.

DPE	Number of various acini			Diameter ( $\mu\text{m}$ )
	Transverse	Longitudinal	Irregular	
9	15	9	7	262.6 $\pm$ 6
10	8	9	6	256 $\pm$ 7
15	1	12	5	233 $\pm$ 34.49
20	8	12	10	312 $\pm$ 28.76
30	10	14	13	194 $\pm$ 19
40	2	16	14	187 $\pm$ 24.78

#### 4.4.1) Histopathology of the acini of the ovotestis

At 9 and 10 DPE as reported in chapter No. 3 that DS arrive in the ovotestis of the susceptible snails. The sidewalls of the acinus stained light and composed of few dark thin nuclei of connective tissue and muscle fibres. Various developing stages of the female and many male germinal cells are located inner layer of the sidewalls of the acini. In most of the occasions Sertoli cells and spermiogenesis are visible in the lumen (Figs. 9a-b). After 15 DPE some DS were appeared very close to the acini of the ovotestis. Very close to DS irregular thin sidewalls and little damage of the sidewall of the acinus was observed. The lumen of the acinus was full of spermiogenesis with little empty spaces. Many DS and developing cercariae were appeared close to the acini of the ovotestis after 20 DPE. Irregular sidewalls and within the lumen empty spaces, spermiogenesis, and few developing sperms are present in the dorsal region of the acinus. After 30 DPE increasing number of mature DS, and cercariae irregular sidewalls, connective tissue cells nuclei become very thin, and spermiogenesis was observed in the lumen of acinus. After 40 DPE increasing number of mature and free cercariae were observed in the ovotestis. The irregular, elongated acini were closely attached to each other and lot of hemocytes reactions was present close the cercariae. The connective tissue cells nuclei disappear in sidewalls and some isolated small spermatogonia are visible in inner layer of the acinus. In the infected ovotestis various developing stages of the female and male germinal cells are visible. The results for normal and infected female germinal cells are described below. Whereas, normal and infected male germinal cells are described in later part of this chapter.

#### 4.4.2) Distribution of the female germinal cells

The number of the female germinal cells in the acini of the ovotestis of the susceptible snails infected with *S. mansoni* is presented in Table No. 4.2. Various types of female germinal cells are visible in the ovotestis. Four types are visible in the acini such as., early oogonia, previtellogenic oocyte, stage I vitellogenic oocyte and stage II vitellogenic oocytes. The number of the female germinal cells was recorded from the several sections of the slide. Increased number of the previtellogenic and stage II vitellogenic oocytes were recorded on 9 and 10 DPE and maximum number was observed on 9 DPE. At 20 and 30 DPE these oocytes shows some histopathological changes in the internal morphology. The range of number of the previtellogenic oocytes, stage I vitellogenic, and stage II vitellogenic of the oocytes was 3-37, 3-6, and 4-31 respectively. Whereas, few atretic round shaped oogonia were seen in the acini of the ovotestis at 10 and 20 DPE (Fig. 9c and d).

Table No. 4.2 Distribution of the female germinal cells in the various acini of ovotestis of susceptible snails during *S. mansoni* infection period.

DPE	Early oögonia		Various stages of the oocytes		
		Atretic	Previtellogenic	I vitellogenic	II vitellogenic
9	2	-	37	5	31
10	-	3	29	5	30
15	-	-	3	3	7
20	-	4	16	4	10
30	-	-	22	6	19
40	-	-	5	4	4
Total	2	7	112	27	101

#### 4.4.2.1) Histopathology of the female germinal cells

After detailed histological examinations of the sections following female germinal cells are observed in the *S. mansoni* infected acini of the ovotestis of the susceptible snails.

##### A) Early oogonia

In the infected acini few oogonia are observed at 9, 10 and 20 DPE.

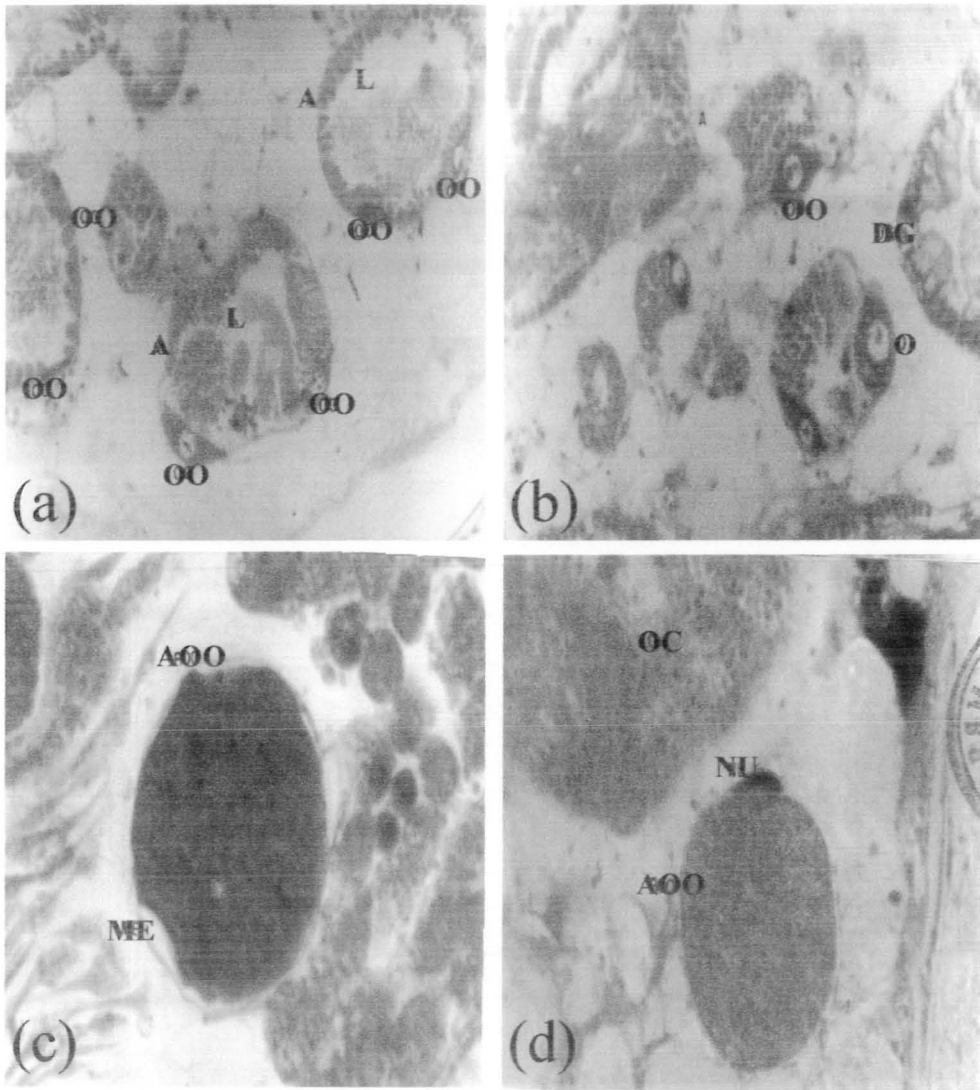
- a) Normal oogonia, and
- b) Atretic round shaped oogonia

a) **Normal oogonia**:- These are very thin elongated, few in number, mostly located in the sidewall of the acinus, surrounded by dark thin outer membrane and cytoplasm at 9 DPE. In one of the acinus very thin elongated early oogonia have dark scanty cytoplasm was visible (Fig. 9a).

##### b) Atretic oogonia

The oogonia are round shaped, few in number, located in the lumen and rarely visible in the dorsal region of the acinus after 10 DPE. These oogonia are surrounded by prominent outer membrane, filled with strongly dark cytoplasm with few vacuoles. In this oogonia increased space is observed between plasma membrane and ooplasm. The nucleus of the oogonia is not visible (Fig. 9c). Similar stage of the oogonia was located near to stage II vitellogenic oocyte after 20 DPE. Most of the structure is same as above but light dark reduced space is present in between the ooplasm membrane and plasma membrane. Additionally, nurse cell nucleus is thin and darkly stained in the outer layer (Fig. 9d).





**Fig. 9 Histopathology of acini, atriotic and previtalogonic oögonia present in the ovotestis of susceptible snails.**

**a-b)** Various size and shapes of the acini (A) have lumen (L) and early (OO) and developing oögonia (OO) at 9 and 10 DPE (228 X).

**c-d)** Atriotic oögonia (AOO) were seen after 10 and 20 DPE (1889 X).

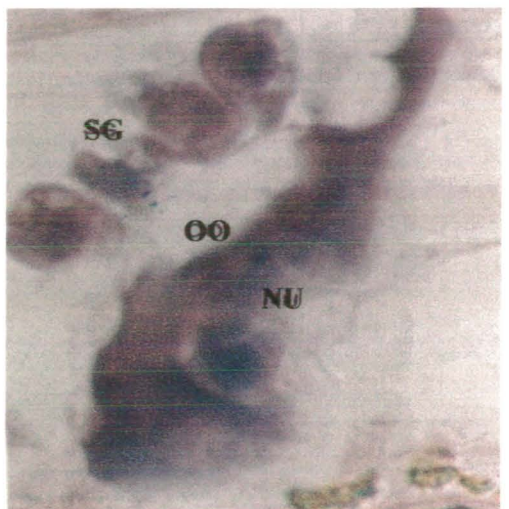
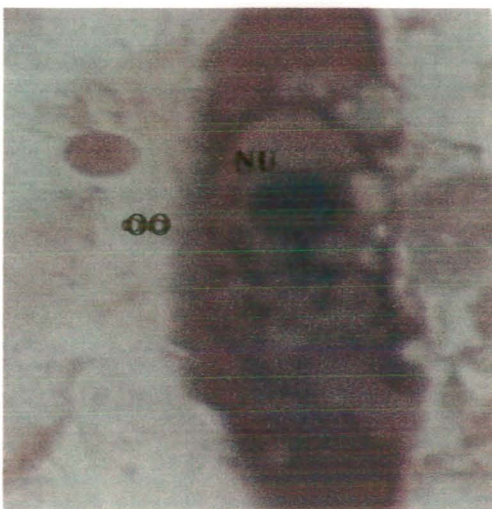
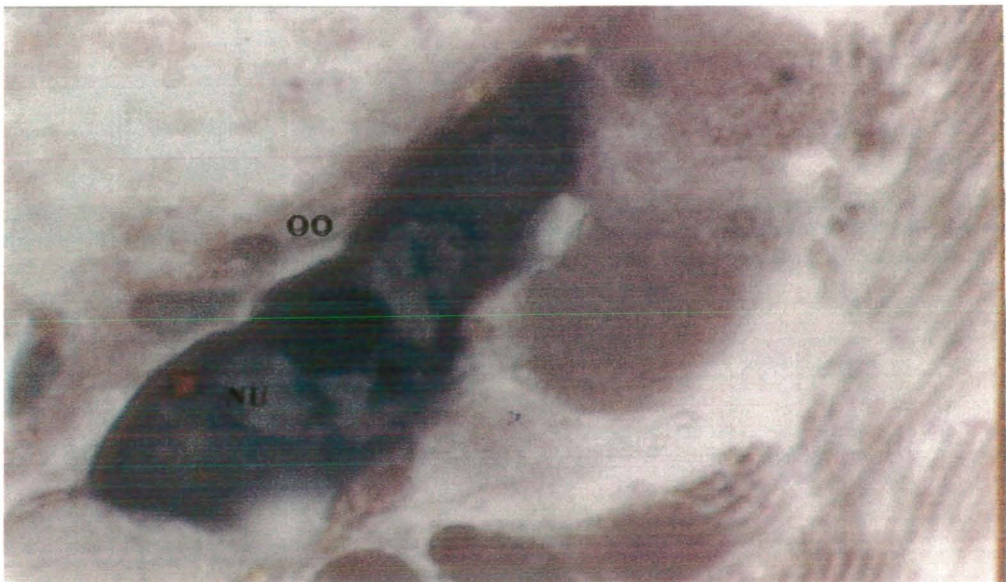
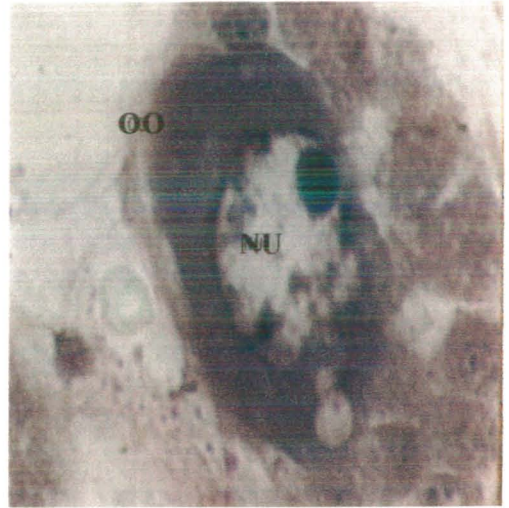
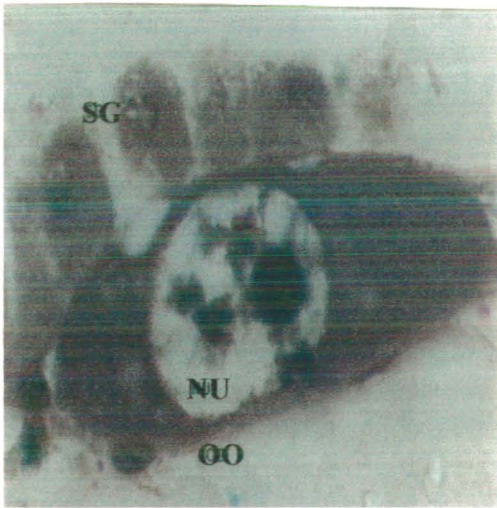
## B) Previtellogenic oocyte

During infections (9, 10 and 30 DPE) greater number of the previtellogenic oocytes were observed in the acini of the ovotestis (Table No. 4.2). At 9 and 10 DPE most of these were normal in structure. The normal previtellogenic oocytes are spindle, elongated and oval shaped with darkly stained homogenous cytoplasm and spherical nucleus with one or two nucleolus. They are mostly located in the sidewalls of acinus and few below the stage II vitellogenic oocytes. A small normal previtellogenic oocyte exhibits darkly stained cytoplasm and empty irregular nucleus. Few previtellogenic or spindle shaped oogonia of variable size displayed some light and dark cytoplasm with little patches or vacuolation, irregular, oval and round nucleus. Within in the nucleus chromatin, single or double dark nucleolus is visible. The light chromatin is attached to the nuclear membrane (Fig. 9a). An other section at 9 DPE the spindle shaped previtellogenic oocytes possess distinct plasma membrane, darkly stained cytoplasm with few vacuolation and spherical or oval shaped nucleus. The nucleus has conspicuous nuclear membrane, lightly stained nucleoplasm, and centrally chromatin placed. The single nucleolus is eccentrically placed. On the outer periphery of the previtellogenic oocyte a few nurse cells are located which possess thin nuclei (Fig. 9e). At 10 DPE few normal spindle shaped various previtellogenic oogonia and an early stage of I vitellogenic oocyte is present at the sidewall of the acinus. Now little increase of the cytoplasm and no any vacuolation observed in the previtellogenic oogonia. Single round or irregular nucleus with little chromatin and increased size of the dark nucleolus is present in the oogonia (Fig. 9b). Another previtellogenic oocyte was also visible at 10 DPE. Which show some reduction in size, and have fatty droplets, vacuolated cytoplasm and round nucleus. The damage of the irregular plasma and nuclear membranes, most of the chromatin and nucleolus is visible at the nuclear membrane (Fig. 9f).

At 15 DPE thin previtellogenic oocyte has irregular shaped plasma membrane, dark cytoplasm with patches and triangular shaped nucleus. The darkly stained nucleus with large dark nucleolus visible at nuclear membrane. The chromatin is spread through out the lightly stained nucleus of these cells (Fig. 9g).

At 30 DPE thin elongated previtellogenic oocyte had fatty droplets in the light cytoplasm and oval nucleus had chromatin and centrally placed dark nucleolus (Fig. 9h).

At 40 DPE thin elongated previtellogenic oocyte exhibits increase vacuolation in the cytoplasm, degeneration of the plasma and nuclear membranes. Darkly stained single nucleolus is visible close to the nuclear membrane (Fig. 9i).



**e and f**) Previtalogonic oogonia are spindle shaped at 9 and 10 DPE (1889 X).  
**g, h and i**) Thin and irregular shaped above oogonia during 15, 30 and 40 DPE (1889 X).

### C) Stage I vitellogenic oocytes

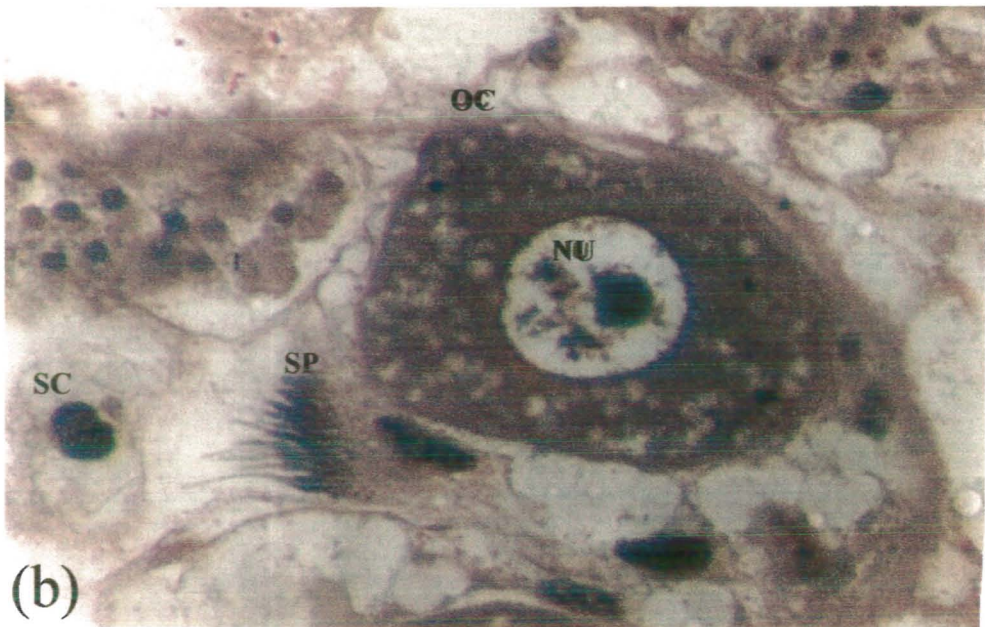
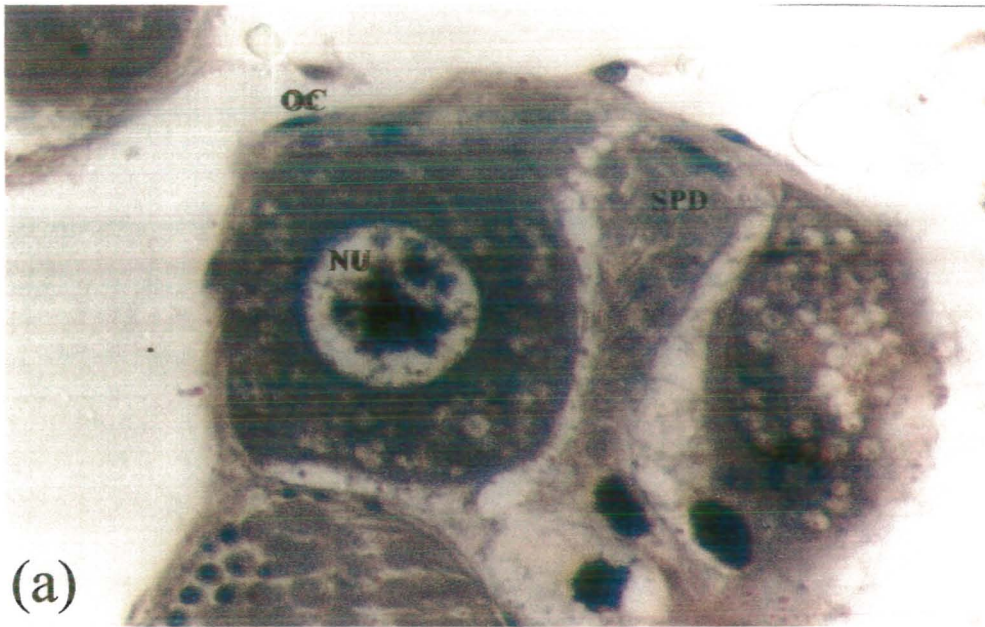
Normal oocytes are mostly quadrilateral and triangular in shape. They are located close or below the stage II vitellogenic oocyte at the dorsal regions and sidewalls of the acini. The stage I vitellogenic oocyte is surrounded by few nurse cells with thin nuclei. These oocytes show prominent plasma membrane, dark vacuolated cytoplasm with yolk deposition and round nucleus. The single large nucleolus is centrally placed, near to it chromatin is in clusters or granules is observed. A few granules of chromatin are seen attached to the inner periphery of the nuclear membrane. The nuclei of the nurse cell are present and II vitellogenic oocyte is also prominent at 9 DPE (Fig. 10a).

At 10 DPE these oocytes are triangular in shape, cytoplasm at this stage of the development is not very dark, vacuolated with reduced yolk deposition and spherical nucleus. The nucleolus is visible near the centre and slightly reduced in size. The chromatin is not in larger clumps as compared to the previously mentioned oocyte. The nurse cells are surrounding the oocyte with thin nuclei (Fig. 10b).

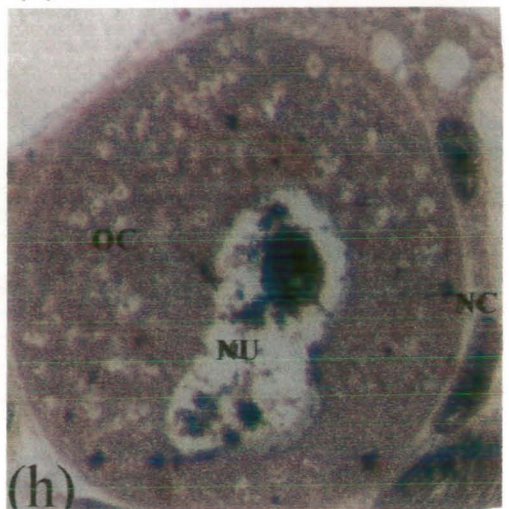
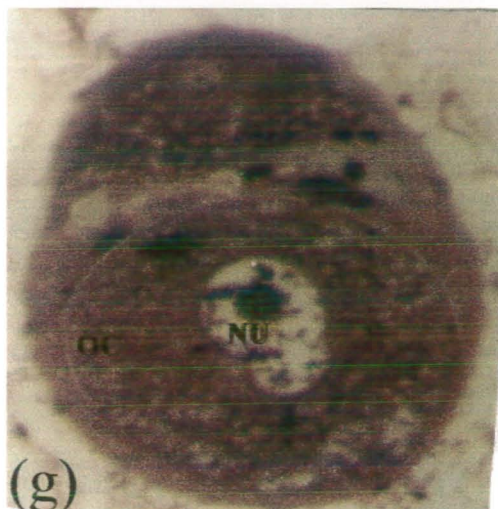
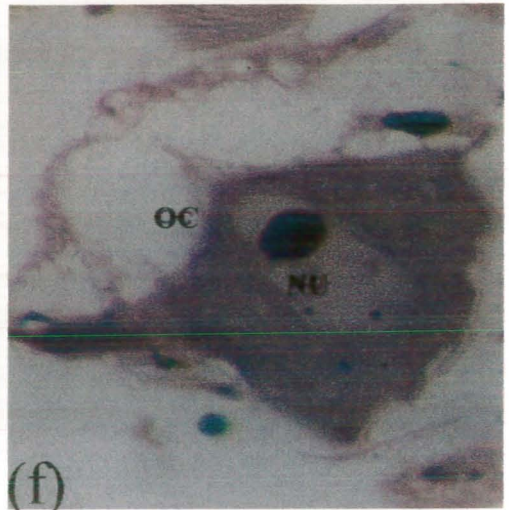
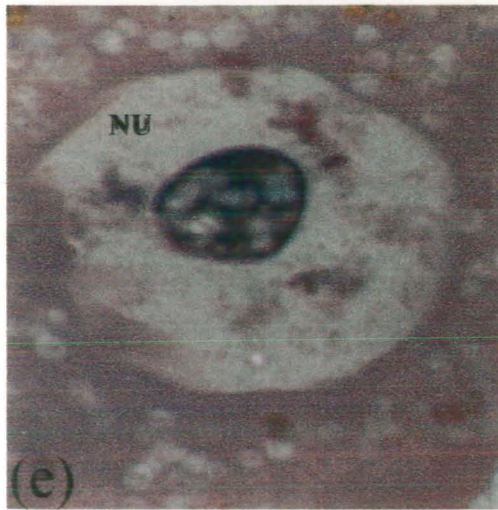
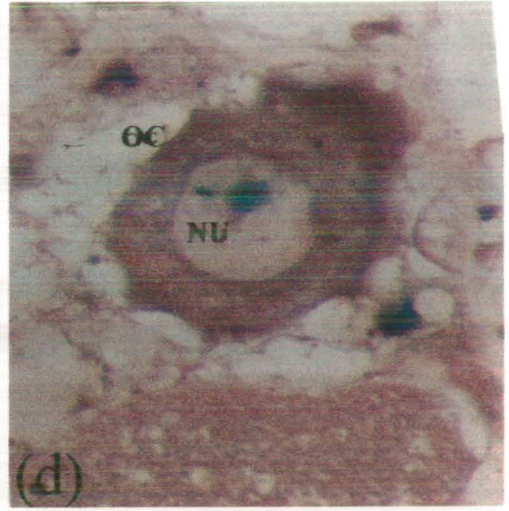
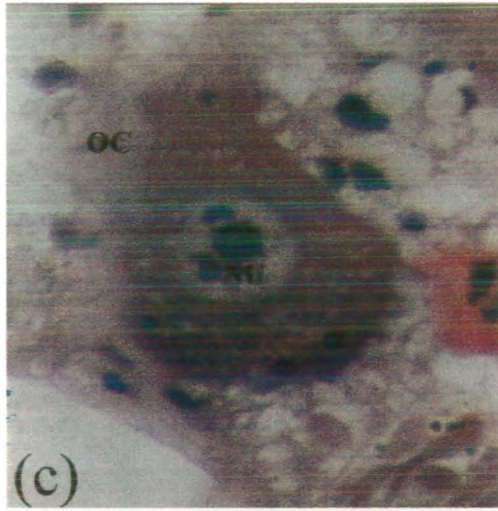
At 15 DPE balloon or triangular shaped stage I vitellogenic oocyte is characterised by irregular cell membrane, dark vacuolated cytoplasm and spherical nucleus. The ooplasm is darkly stained whereas nucleus is lightly stained. The plasma and nuclear membrane are stained lightly. The nucleus has well-developed dark round nucleolus, few clusters and thin granules of the chromatin. On the outer periphery of oocyte irregular shaped nurse cells layer with dark nuclei is also present (Fig. 10c).

At 30 DPE irregular stage I vitellogenic oocyte is characterised by irregular plasma membrane, densely stained vacuolated cytoplasm and larger spherical nucleus as compared to the nucleus on 15 DPE. Light and darkly stained chromatin and dark nucleolus is visible in nucleus. Most of the nurse cells have now disappeared and hence thin nuclei are not visible. The spread of few dark and light chromatin is present in the nucleus (Fig. 10d). At 30 DPE oocytes exhibits light vacuolated cytoplasm, irregular nuclear membrane and hypertrophied nucleus, chromatin, and vacuolated darkly stained enlarged nucleolus is observed (Fig. 10e).

At 40 DPE the oocyte is greatly enlarged, has plasma membrane, darkly stained less vacuolated cytoplasm. Nuclear membrane is not distinct, has less chromatin and dark compact nucleolus. Few dark nurse cells thin nuclei are also present in the outer layer (Fig. 10f).



**Fig. 10 I and II vitalogenic stages of the oocytes found in the acini.**  
**a-b)** A quadrilateral and triangular shaped I vitalogenic oocytes (OC) were visible (1889 X).



**c, d and f)** Irregular shapes of the I vitalogenic oocytes were found at 15, 30 and 40 DPE (416 X).

**e)** Vacuolation was observed in the nucleolus of the above type of the oocytes at 30 DPE (1889 X).

**g-h)** II vitalogenic stage of the oocytes were seen at 9 and 10 DPE (330 X and 416 X).

#### D) Stage II vitellogenic oocytes

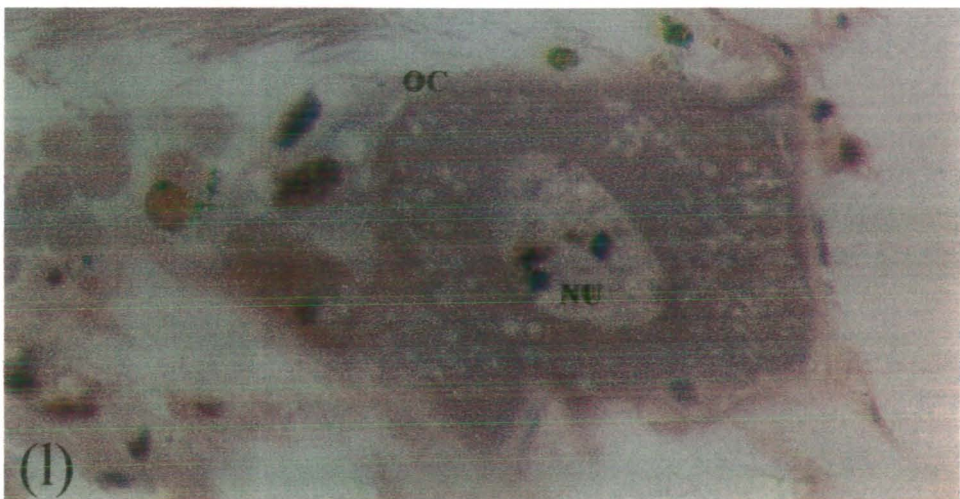
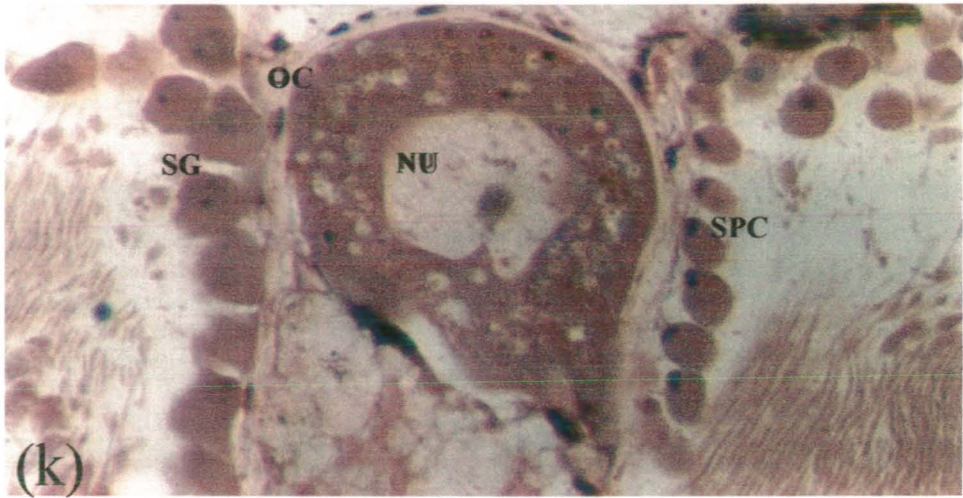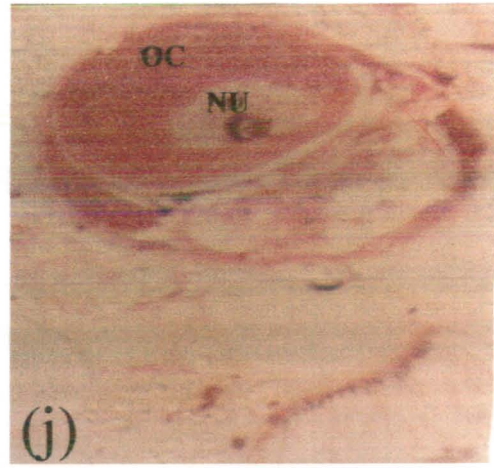
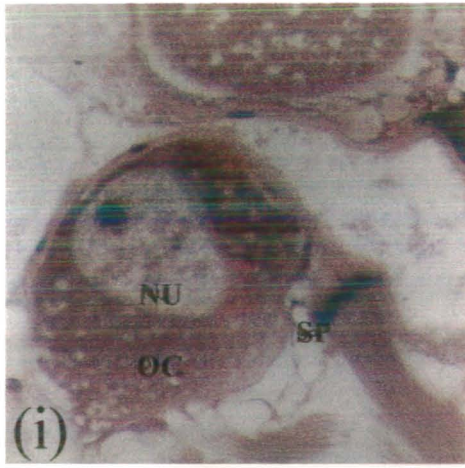
Normal oocytes are round, triangular, and oval or irregular in shape. They are many in number, increasing in size and located mostly in the proximal and few in the lumen of the acinus at 9 DPE. They are greater in size as compared to stage I oocytes. Increase yolk deposition in the cytoplasm of this oocyte is observed as compared to earlier stages types of the oocytes. In early stage of the development oocyte has distinct plasma membrane, dark vacuolated yolky cytoplasm is observed. Few nurse cells with dark nuclei of the nurse cells are visible around the oocytes. The oocytes possess the prominent plasma membrane, has increased dark amount of vacuolated yolky cytoplasm. Their nuclei are hook shaped with prominent nucleolus in the centre. The nurse cells on the outer periphery of the stage II oocytes are plumper elongated in shape. Their nuclei possess compact granular chromatin. Between the oocyte and peripheral nurse cells a clear gap is observed (Fig. 10g).

At 10 DPE stage II vitellogenic oocyte was attached with sidewall of the acinus. Which contains enormous amount of vacuolated yolky lightly stained cytoplasm and spherical nucleus with some clumps and scattered chromatin. Stage II vitellogenic oocytes have distinct plasma membrane, vacuolated yolky lightly stained cytoplasm, irregular centrally located nucleus with dark nucleoli and rich in chromatin. It is surrounded by follicular cavity, in which few nurse cells nuclei are prominent. Which are now more conspicuous large in size with nucleus containing finely granulated compact chromatin and a nucleolus. At this stage the gap between nurse cells and oocytes has become wider (Fig. 10h).

At 15 DPE irregular shaped stage II vitellogenic oocyte show triangular nucleus with dark nucleolus near the nuclear membrane, light and dark vacuolated cytoplasm. The nucleoplasm is lightly stained and chromatin is also light in colour. The nurse cells are very thin with thin nuclei (Fig. 10i).

At 20 DPE oval shaped stage II vitellogenic oocyte exhibits lightly stained plasma membrane and vacuolated cytoplasm. The irregular shaped nucleus had lightly stained chromatin and vacuoles have appeared in the nucleolus. The degeneration of the nurse cells nuclei was observed (Fig. 10j).

At 30 and 40 DPE infected irregular shaped oocytes were observed. In which are oval shaped nuclei, plasma membrane and vacuolated cytoplasm are lightly stained. The oocyte is surrounded by very thin nurse cells with dark nuclei (Figs. 10k-l).



**i, k and l** Irregular shaped of the II vitellogenic oocyte were observed after 15, 30 and 40 DPE (416 X).

**j** Irregular shaped of the II vitellogenic oocyte with vacuole in the nucleolus was observed after 20 DPE (330 X).



#### E) Mean diameter of the female germinal cells and their nuclei

The mean diameter ( $\pm$  SEM) of the various types of the oocytes and their nuclei found in the acini is presented in Table No. 4.3. The highest mean diameter  $48.40 \pm 3.22 \mu\text{m}$  and  $48.40 \pm 5.59 \mu\text{m}$  of the previtellogenic stage of oocyte was recorded at 20 and 40 DPE respectively. The range of the mean diameter  $17.60 \pm 1.42 \mu\text{m}$  to  $21.51 \pm 2.61 \mu\text{m}$  of the nucleus of the previtellogenic stage of oocyte at 9, 10, 15, 20, 30 and 40 DPE. Similarly the highest mean diameter  $57.69 \pm 1.46 \mu\text{m}$  of the stage I vitellogenic stage of oocyte was recorded at 40 DPE. The range of the mean diameter  $21.51 \pm 0.91 \mu\text{m}$  to  $25.53 \pm 2.31 \mu\text{m}$  of the nucleus of the stage I vitellogenic oocyte at 9, 10, 15, 20, 30 and 40 DPE. However, at 9 DPE the highest mean diameter  $106.6 \pm 5.04 \mu\text{m}$  of the IIInd vitellogenic stage of oocyte was recorded. The range of the mean diameter  $25.91 \pm 0.97 \mu\text{m}$  to  $40.58 \pm 1.65 \mu\text{m}$  of the nucleus of the IIInd vitellogenic stage of oocyte at 9, 10, 15, 20, 30 and 40 DPE. Increase mean diameter of the II vitellogenic stage of the oocytes at 9 DPE shows normal infection in the acinus. The reduce size of the various types of the oocytes are due to the level of the infections increase in the acinus of the ovotestis of the susceptible snails.

Table No. 4.3 Mean diameter ( $\pm$  SEM) of the female germinal cells with nucleus of the susceptible snails during *Schistosoma mansoni* infections.

DPE	Early oogonia Nucleus ( $\mu\text{m}$ )		Previtellogenic Nucleus ( $\mu\text{m}$ )		Stage I vitellogenic	Nucleus ( $\mu\text{m}$ )	Stage II vitellogenic	Nucleus ( $\mu\text{m}$ )
9	23.25 $\pm$ 3.54	-	38.62 $\pm$ 2.37	20.04 $\pm$ 1.42	49.87 $\pm$ 3.75	23.47 $\pm$ 2.26	106.6 $\pm$ 5.04	40.58 $\pm$ 1.65
10	-	-	42.05 $\pm$ 3.31	19.55 $\pm$ 2.04	56.72 $\pm$ 2.93	24.43 $\pm$ 1.54	91.92 $\pm$ 3.24	37.65 $\pm$ 2.85
15	-	-	41.07 $\pm$ 6.34	17.60 $\pm$ 1.42	50.85 $\pm$ 4.60	22.97 $\pm$ 2.85	66.01 $\pm$ 4.01	31.78 $\pm$ 2.04
20	-	-	48.40 $\pm$ 3.22	21.05 $\pm$ 2.26	44.89 $\pm$ 6.26	21.51 $\pm$ 0.91	83.61 $\pm$ 3.31	37.16 $\pm$ 2.93
30	-	-	43.52 $\pm$ 7.35	21.51 $\pm$ 2.61	53.78 $\pm$ 3.70	22.79 $\pm$ 1.83	87.52 $\pm$ 5.95	36.18 $\pm$ 1.19
40	-	-	48.40 $\pm$ 5.59	18.58 $\pm$ 1.24	57.69 $\pm$ 1.46	25.53 $\pm$ 2.31	81.16 $\pm$ 7.62	25.91 $\pm$ 0.97

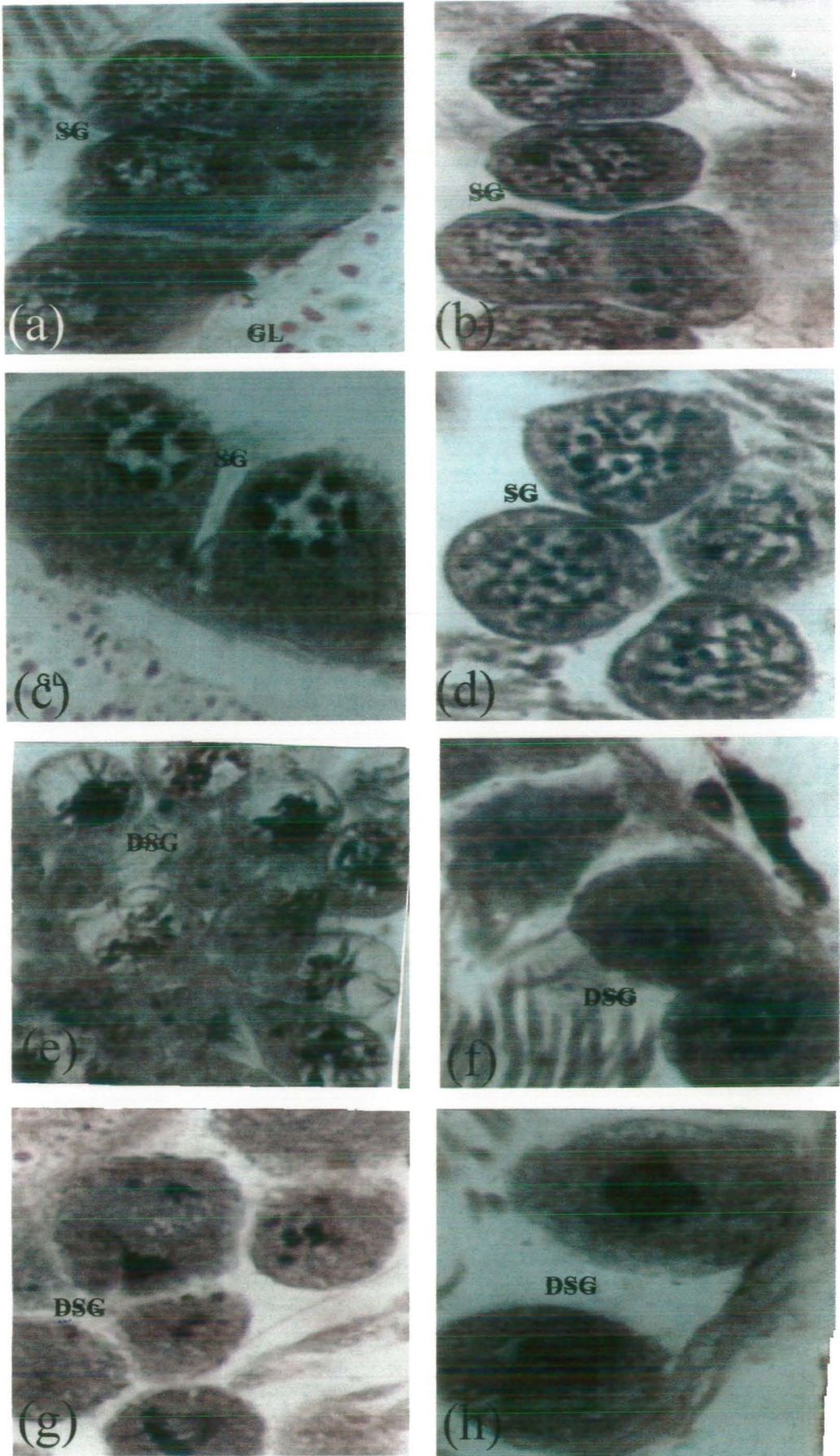
#### 4.4.2.2) Histopathology of the male germinal cells

The male portion of the ovotestis containing several developing stages of the spermatogonia, spermatocytes, spermatids and mature sperms. They were frequently observed in the sidewalls of acini during early days of infections. In addition to these stages active spermiogenesis was also visible in the lumen of the acini.

At 9 and 10 DPE the sidewalls of the few acini contained several dividing spermatogonia (Figs. 11e and g). (Few elongated spermatogonia had round or spherical dark nucleus and light cytoplasm was also found at the dorsal side of the acinus (Fig. 9e)). Few of these cells are also visible at the right side of the figure after 10 DPE (Fig. 9f). Some of the swollen irregular shaped spermatogonia had light cytoplasm and nucleus is less conspicuous after 30 DPE (Fig. 10k). The complete disappearance of nuclei and scanty cytoplasm was visible in the spermatogonia observed after 30 DPE (Fig. 12i). A group of four round or oval and irregular shaped spermatogonia after 40 DPE. The nuclei of these cells become pyknotic and reduced cytoplasm in these cells was found (Fig. 9i).

##### A) Developing stages of spermatogenic cells (Spermatogonia and spermatocytes)

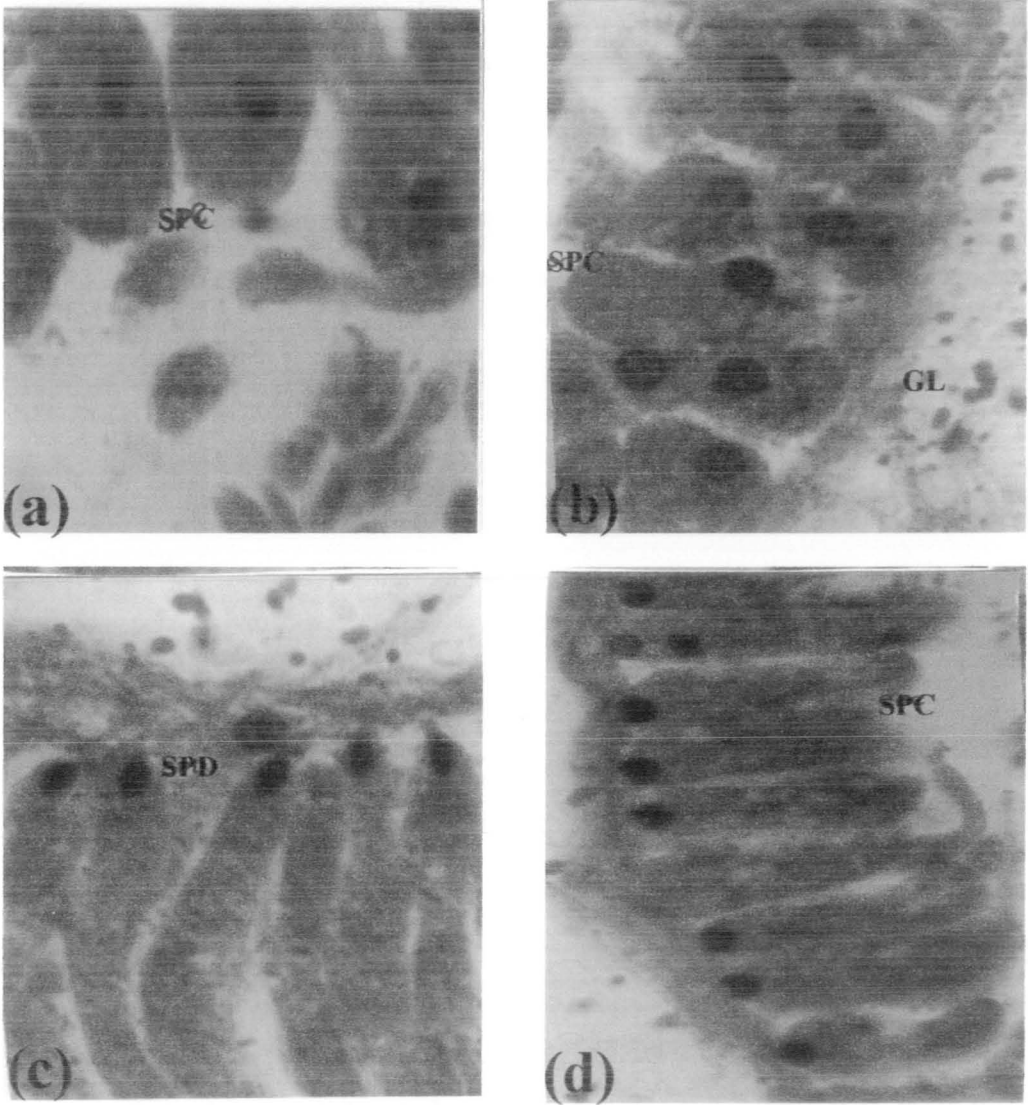
The spermatogonia are of variable shapes and sizes, with spherical or oblong nuclei containing one, two or greater number of darkly stained nucleoli (Figs. 11a-d). These nucleoli have either attached to the inner border of nuclear membrane or near to it (Figs. 11a and b). PAS positive material is visible near and around the spermatogonia. The nuclei of some of the spermatogonia are eccentrically placed just below the plasma membrane. In these spermatogonia the nuclei have 8-9 nucleoli, which are mostly attached to the inner border of the nuclear membrane, while few of them were in the centre (Fig. 11c). In the nuclei of few spermatogonia scattered chromatin is granulated and cytoplasm is scanty (Fig. 11d). The lightly stained cell, nuclear membranes, cytoplasm, chromatin with granules and chromosomes (Figs. 11a-d). The light cytoplasm and dark nuclei of the dividing spermatogenic cells are noticed. Few PAS positive granules are also visible (Figs. 11a and d). During mitosis few spermatogonia are showing condenses dark nuclei with vacuolation and light homogenous cytoplasm. Thin elongated nucleus of the connective tissue of the acinus and few PAS positive granules are also visible (Fig. 11f). Few dividing spermatogonia are showing early and late stages of metaphase cell divisions (Figs. 11g-h). After mitosis several bucket shaped spermatocytes having light stained cell membrane, less cytoplasm, vacuolation and clusters of the dark chromosomes visible in the round shaped nuclei (Fig. 11e). The length and width of 10 different various spermatogonia and its nucleus was recorded (Table No. 4.4).



**Fig 11. Histology of the spermatogenic cells in the acini of the ovotestis.** a-c) single, double and some dark granules of the chromatin visible in the nucleus (NU) of these cells (X 1889). d and e) Cells showing meiosis, chromosomes and vacuolation is visible in the nucleus (X 1889). f-h) Cells showing mitosis in the spermatogonia (DSG) are prominent (X 1889). DSG, Dividing spermatogonia; GL, Glycogen; SG, Spermatogonia.

### **Developing stages of B) spermatids and C) early sperms**

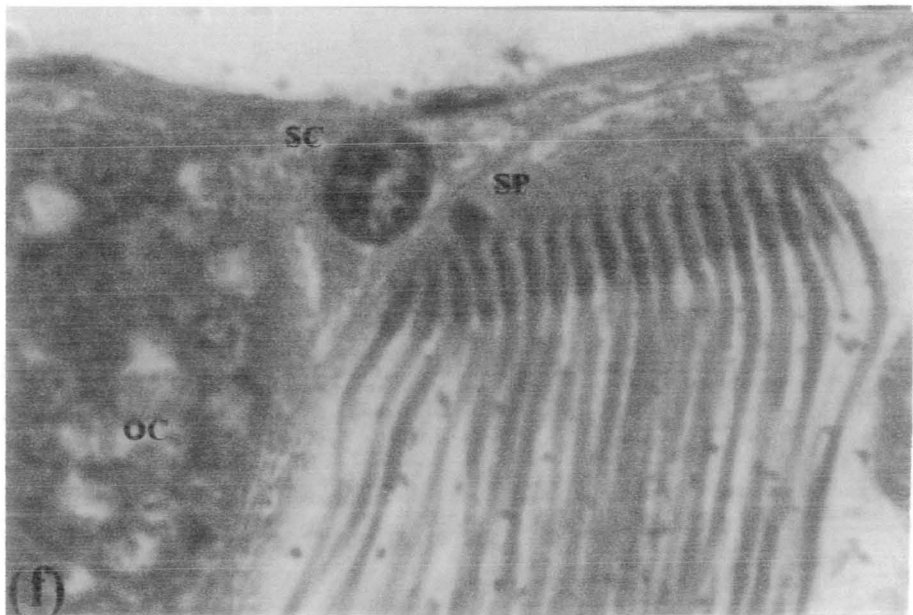
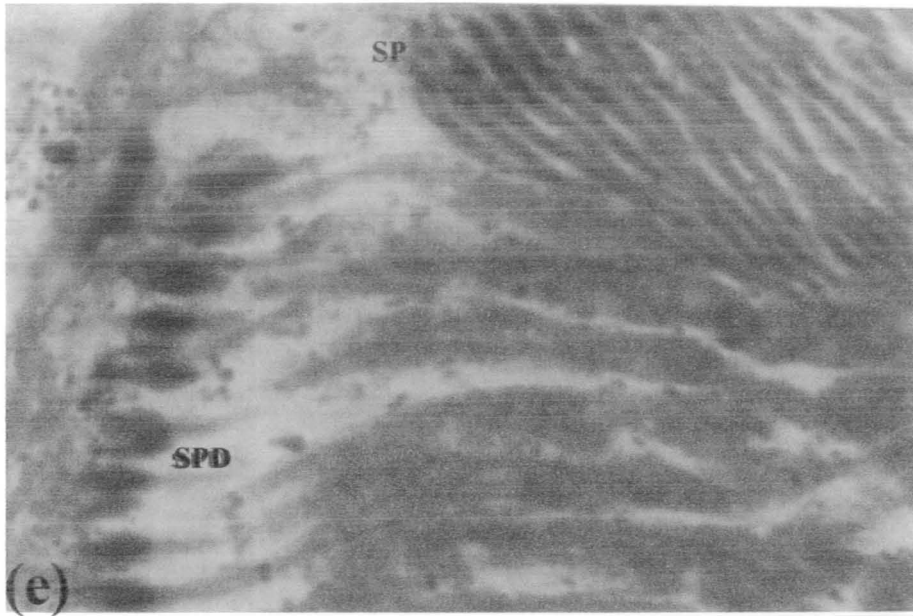
After completion of meiosis round or oval or cuboidal and elongated shaped spermatids are visible in the acini along the sidewalls. The spermatids contained light cytoplasm with patches and centrally placed nuclei are entirely dark round or oval (Fig. 12a). With the subsequent development there is elongation of spermatids with the result that the nuclei are visible towards the sidewall and the cytoplasmic portion, which is vacuolated towards the lumen. PAS positive material is observed around the acinus (Fig. 12b). In the next stage of spermiogenesis the early stage of sperms are observed at the sidewall of the acinus, which have further elongated they are very closely attached to the Sertoli cell and have spherical nucleus (Fig. 12b). In later development the spermatids nuclei are no more round instead they are narrow and pointed towards the side where they are attached to the Sertoli cell. Now the less amount of PAS positive material was visible around the sidewall of the acinus (Fig. 12c). As spermiogenesis proceeds most of spermatocytes were showing further straight elongation of the cytoplasm and pointed anterior region of dark nucleus forming the acrosome. Some of the PAS positive material is also visible (Fig.12d). During the further stage of sperm formation the nucleus has become elongated and pointed. Head of sperm, formation with thin neck region and increased elongation of the cytoplasm is also visible. Some PAS material was visible in the neck regions of the developing sperms. In the same acinus some early developing sperm containing dark curved head and light cytoplasm are also seen (Fig. 12e).



**Fig. 12 Histology of the spermatocytes, spermatids and mature sperms.**  
**a-d)** Cuboidal and thin elongated spermatocytes (SPC) have round and pointed anteriorly nucleus (1889 X).

#### D) Mature sperms

At 9 DPE the sidewalls of the acini contain several bundles of mature sperms along with developing sperms (Fig. 9a). During the maturation of the sperm exhibit dark curved head and light thin elongated tail with PAS positive material distributed in the tail region (Figs. 12e and f). The wall of the acinus possesses very thin cells with spindle shaped nuclei. These bundles of sperms are attached the Sertoli cells. The nucleus of Sertoli cells is large, very conspicuous, spherical and rich in chromatin material. Its nucleus possesses two nucleoli (Fig. 12f). The mature sperms have thin straight elongated head with thin neck and long thread like tail. These mature sperms are always attached to the Sertoli cell. After 10 and 20 DPE acinus has two bundles of almost mature sperms attached to the broad nucleus of the Sertoli cell (Fig. 12g and h). At 30 DPE normal three bundles of mature sperms are visible in the lumen of the acinus (Fig. 12i). In later infection at 40 DPE a set of mature sperms with thin elongated nuclei and tail are visible (Fig. 12j). There was no visible pathological effect in the mature sperm throughout the infection period.

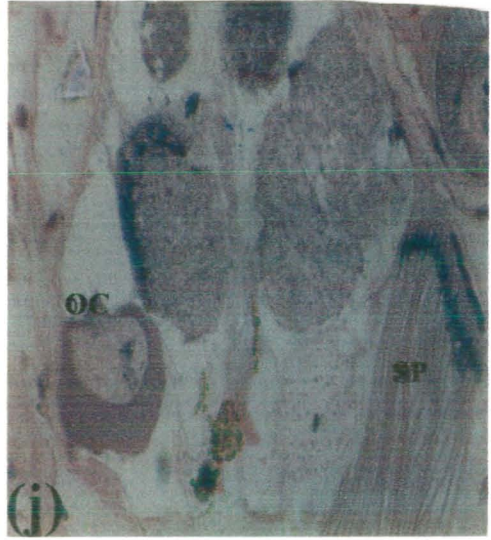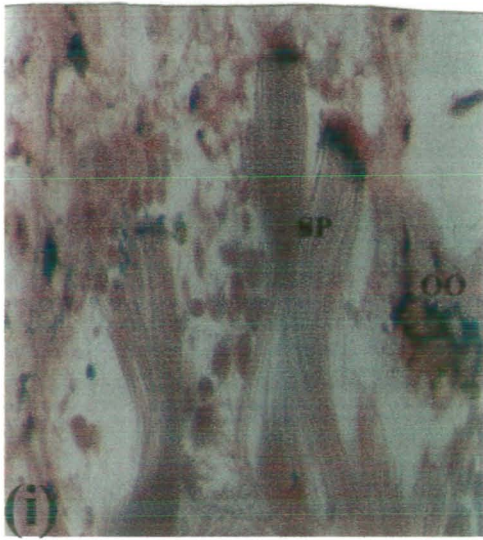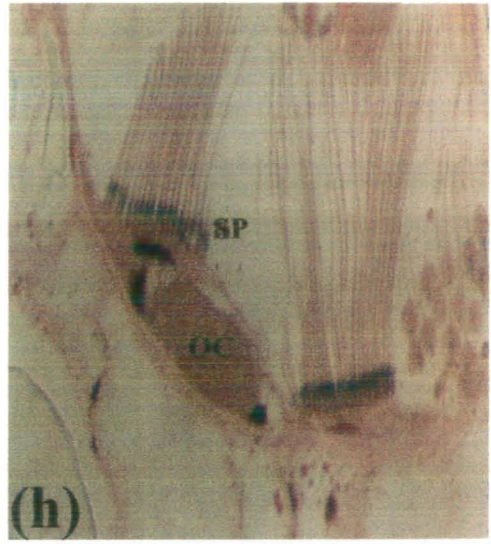
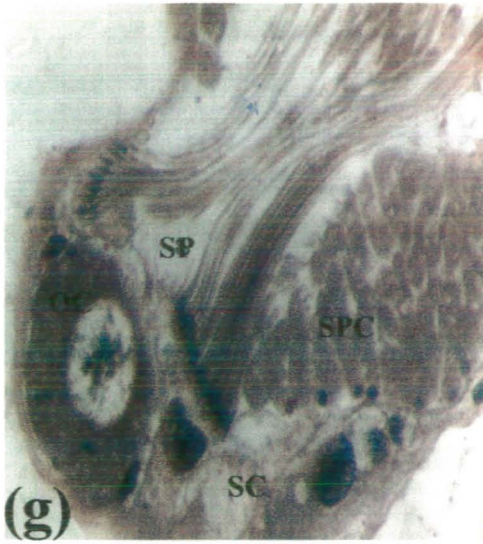


**Spermatids (SPD) and mature sperms (SP) are visible close the sidewall and Sertoli cells (SC).**

**e) The spermatids had dark head, light thin elongated regions and are transforming in to the spermatozoa (1889 X).**

**f) A bundle of the mature sperms with prominent head and thin flagellum are visible (1889 X).**





**g-j)** Mature sperms are close the Sertoli cells, oocytes (OC), spermatids and below spermatocytes (416 X).

### E) Mean diameter of the various male germinal cells

The mean diameter ( $\pm$  SEM) of the spermatogonia, spermatocytes and spermatids were recorded. In addition to this mean length of the mature sperm was also recorded (Table No. 4.4). The highest mean diameter ( $\pm$  SEM) of the spermatids was  $37.25 \pm 1.55$   $\mu\text{m}$ . The highest mean length of the mature sperms was  $77.5 \pm 10.75$   $\mu\text{m}$  at 10 DPE.



Table No. 4.4 Mean diameter ( $\pm$  SEM) and length of the various male germinal cells observed in acini of the ovotestis of the susceptible snails.

S.No	Name of cells Spermatogenic cell type ( $\mu\text{m}$ )	Diameter	DPE	Length of mature sperm ( $\mu\text{m}$ )
1	Spermatogonia	$18.25 \pm 1.01$	9	$108.25 \pm 12.79$
	Nucleus	$1.28 \pm 0.14$	10	$77.5 \pm 10.75$
2	Spermatocyte	$27.5 \pm 0.88$	15	$91.25 \pm 24.59$
3	Spermatid	$37.25 \pm 1.55$	20	$75 \pm 3.95$
			30	$41.25 \pm 6.88$
			40	$63.13 \pm 4.72$

#### 4.5) Discussion

Histopathology of the *S. mansoni* infected ovotestis of the *B. glabrata* susceptible snails has been carried out. Pan, (1958) has reported that the acini of the ovotestis *A. glabratus* snails are histologically and functionally distinct from the collecting canal and the walls of the acini were composed of thin connective tissue, two or three cells thick. In the present study variable shape and size of the acinus of the ovotestis of the susceptible snails of *B. glabrata* is reported. In the wall of the acinus few cells with dark thin nuclei were visible. Pan, (1958) has reported that the female germinal cells or ova were usually located at the apices of acini and the male germinal cells were arranged along the sidewalls. In this study few oogonia at the sidewalls, previtellogenic, stage I and II vitellogenic oocytes are mostly located in the dorsal region of the acinus. Increasing number of various developing stages of the male germinal cells are observed throughout the sidewall and lumen of acinus of the ovotestis of the susceptible snails. Healy, (2001) has reported that the oogonia are derived from germinal cells lining the acinus closest to the ductule and, during subsequent developmental stages, the oocyte move progressively towards the distal region of the acinus. In the present study oogonia were also derived from germinal cell visible in the sidewalls of the acinus. During various developing stages I and II vitellogenic oocytes were observed in the proximal region of the acinus. In gastropods oogenesis is intimately associated with a sheath of follicle cells, which on oocyte maturation release the unfertilised ovum into the acinar lumen (Raven, 1961; Jong-Brink et al., 1976). Griffond and Bolzoni-Sunger, (1988) recognised six oogenic cells stages in *C. aspersus*: 1) oogonial cell; 2) young oocyte; 3) premiotic oocyte; 4) previtellogenic oocyte; 5) first stage vitellogenic oocyte; and 6) second stage vitellogenic oocytes. In the present study early oogonia, atretic oogonia, previtellogenic oocytes, stage I and II vitellogenic oocytes are recognised in the ovotestis of the susceptible snails. The oogonia of *C. aspersus* are recognisable by their oblong nucleus and particularly well developed concentric whorls of rough endoplasmic reticulum (Griffond and Bolzoni-Sunger, 1986). In the present study oogonia are thin elongated, round shaped and spherical nucleus. Generally in previtellogenic oocytes, the plasma membrane shows no surface modification and the cytoplasm contains endoplasmic reticular and Golgi cisternae, lipid-vesicles. The nucleus is ovoid, decondensed and exhibits a large nucleolus (paranucleolus) (Healy, 2001). In the present study previtellogenic oocytes are spindle, elongated, and oval shaped. The darkly stained homogenous, little patches or vacuolation of cytoplasm, distinct plasma membrane and spherical nucleus with one or two nucleolus and chromatin was observed in the above

cells. During the vitellogenic (yolk producing) stages, both the nucleus and cytoplasm increase dramatically in size, reflecting the activity of both the nucleus (and nucleolus) and the cytoplasmic organelles (Healy, 2001). In the present study overall size of the stage I oocyte was also increased. These oocytes show prominent plasma membrane, dark vacuolated cytoplasm with yolk deposition and round nucleus with large nucleolus. In late vitellogenic oocyte (stage 6) the plasma membranes develops microvilli, some of which contact the surrounding follicle cells. Throughout vitellogenesis, a gap between the oocyte and follicle cells becomes increasingly wider, ultimately resulting in bursting of the follicle and release of the mature oocytes (or ovum) (Healy, 2001). In this study plasma membrane of the stage II vitellogenic oocytes around by few thin nuclei of the nurse cells and follicular cells. In addition to these the gap between the oocytes and follicular cells was also become wider. Pan, (1958) has reported the mature ovum measures 98  $\mu\text{m}$  in diameter and contains a round, slightly eccentric nucleus measuring 36  $\mu\text{m}$ . The nucleolus is round, eccentric, and has a basophilic, half moon-shaped paranucleolus along the margin. The cytoplasm stains purple or bluish in haematoxylin-eosin preparations, is coarsely granular, and may also contain a few small vacuoles. Tompa, (1980; 1984) has reported mature stylomatophoran oocyte range in diameter from 50-200  $\mu\text{m}$ . In the present study the mean diameter of the stage II vitellogenic oocyte was  $106.6 \pm 5.04 \mu\text{m}$ , and nucleus  $40.58 \pm 1.65 \mu\text{m}$ . The variable size of the round nucleolus stain darkly. The granular cytoplasm of the oocytes stains light or dark with polychrome methods, and also contains large vacuolations.

Healy, (2001) has reported that spermatogenesis includes four developmental stages: 1) derivation of the spermatogonia from the germ cells; 2) mitotic proliferation of the spermatogonia; 3) production of primary and secondary spermatocytes; and 4) production of spermatids and their eventual transformation into mature spermatozoa (step (4) = spermiogenesis). Similar developmental stages were also observed in the present study during the spermatogenesis in the susceptible snails. As Roosen-Runge, (1977) has emphasised, spermatogenesis is essentially a syncytial process in which generations of cytoplasmically connected spermatogonia pass through the same developmental sequence. Pan, (1958) has reported that the developing young male germinal cells were attached to Sertoli cells are close to the area where the ova are developing. In the present study developing young and mature sperms were close to the Sertoli cells and stage II vitellogenic oocytes are also near to them. Healy, (2001) has reported that the spermatogonia having arisen from the germinal epithelium, attached with a desmosome-like junctions to so called "Sertoli cells" to form a cluster. In addition,

cytoplasmic bridges develop during spermatogonia proliferative division. Spermatogonia are generally pyriform and exhibit an oblong to spherical nucleus (with patchy heterochromatin and 1-3 nucleoli) and, in proportion to the nucleus, a relatively small quantity of cytoplasm. In the present spermatogonia mostly attached with sidewalls and some clusters of these were visible in the distal side of the acinus of the susceptible snails. The round or oval shaped nucleus of the spermatogonia attached just below the plasma membrane is rich in chromatin, containing 1-9 dark nucleoli. The little patchy light cytoplasm and close to these cells PAS-positive material glycogen stained well. No any Sertoli cell visible around these cells but thin nuclei of the cells visible in the sidewall of the acinus was present. Pan, (1958) has reported that very early stages (spermatogonia) of the male germinal cells frequently located near the atrium of an acinus. In this study these cells were frequently visible at sidewalls and rare in the ventral region of the acinus. Pan, (1958) has reported that the spermatogonia divide by mitotic division to form spermatocytes which enlarge considerably before undergoing another division. In the present findings several mitotic and few meiotic divisions were observed in the nucleus of the spermatogonia with prominent metaphase and bucket shaped spermatocyte (zygotene stage). Later, nucleus reduced in size, change shape and elongation of the cytoplasm was visible and this stage is known as the spermatids. Healy, (2001) has reported that primary spermatocytes are rounded to pyriform, and are characterised by an increased proportion of the cytoplasm relative to the nuclear volume. Within the nucleus, the presence of synaptonemal complexes (during zygotene and pachytene stages) and a single nucleolus. Secondary spermatocytes are reduced in size compared with primary spermatocytes, contain proportionally less cytoplasm. In the present study similar changes were also noticed in the bucket shaped spermatocytes, which were observed in clusters. Mitochondrial and endoplasmic reticular features are, however, similar to those observed in primary spermatocytes (Healy, 2001). In this study no any such features are recognised under the light microscope. However, primary spermatocytes exhibit a reduced size of the variable shape of the dark nuclei and increased cytoplasm with patches. The nucleus of these cells was mostly observed in the centre or near to it. The elongation of the cytoplasm has been initiated and small round shaped many darks or few light nuclei are attached to the sidewalls of the acinus of ovotestis. The PAS-positive material was also visible around the acinus. Pan, (1958) has reported another mitotic division takes place resulting in the formation of the spermatids. The small round nuclei of the spermatids are at first compact, but before the

transformation into is complete chromatin material becomes concentrated and crescent shaped. These results are agreement with the present study.

In the early spermatids of pulmonates, the nucleus is rounded and its contents initially exhibit dense chromatin patches (Healy, 2001). In the present study similar shape of the nucleus of the early spermatids was observed. The nucleus subsequently becomes evenly granular in texture. The cytoplasm contains an extensive endoplasmic reticulum, usually multiple stalks of Golgi cisternae, numerous rounded or elongate mitochondria (exhibiting unmodified cristae and usually one or more inter mitochondrial granules and one or sometimes two centrioles (Healy, 2001). The cytoplasm of the early spermatids was vacuolated and stained lightly in this study. In the In some instances, two or more spermatids may develop within a common cytoplasm (Healy, 2001). No such development was seen in the present findings. The shape of the spermatid nucleus changes during development, being initially rounded (early spermatid), then anterior-posteriorly compress with spongy fibres (middle stage), then pyriform, with fibres elongate (advanced stage), and finally rod shaped (usually with helical keels) fusing into lamellae (late stage) (Healy, 2001). The process of spermiogenesis encompass all those developmental changes, both morphological and cytochemical, which transform spermatids into spermatozoa. This process involves formation of the acrosome, condensation of the nuclear contents and completion of associated nuclear protein transitions, formation of an elongate midpiece (varying degrees of mitochondrial remodelling) and finally the deposition of whatever glycogen reserves may be present around the mitochondria and/or axoneme (Healy, 2001). The process of spermiogenesis encompass all those developmental changes, both morphological and cytochemical, which transform spermatids into spermatozoa. This process involves formation of the acrosome, condensation of the nuclear contents and completion of associated nuclear protein transitions, formation of an elongate midpiece (varying degrees of mitochondrial remodelling) and finally the deposition of whatever glycogen reserves may be present around the mitochondria and/or axoneme (Healy, 2001). In the present study as the spermiogenesis proceeds most of the spermatocytes were showing further straight elongation of the cytoplasm and pointed anterior region of dark nucleus forming the acrosome. Accumulation of the glycogen commences only after the completion of spermatozoa maturation; such deposits have been demonstrated in late spermatids, and

mature spermatozoa (Healy, 1983). In the present study PAS positive material glycogen was also noticed throughout spermiogenesis. Morphologically mature spermatozoa, after being released from the supporting or so-called "Sertoli cells" (during the process of a spermiation) move into the lumina of the ovotesticular acini and from their to the hermaphrodite duct (Hodogson, 1996). The bundles of the mature sperms are also attached to Sertoli cells in the present study.

The present research work is ideal and no body has done detailed histology and pathology of the ovotestis of the susceptible snails of *B. glabrata*, intermediate host of *S. mansoni*. This study will provide detailed information on the normal histology and pathological changes, which occur in the oogenesis and spermiogenesis in the snails. The results presented in this chapter are necessary for the academic purposes such as in the field of medical and veterinary sciences. Finally, this study will also be helpful for identifying various reproductive abnormalities in human and animals during schistosome infections.



*APPENDIX*

## Appendix

**Histological Technique:-** The details of the processing the animals is as under;

### Relaxation

For this purpose 1-10, 15, 20, 30+30 and 40 DPE susceptible, resistant and Giant 303 snails were put in the warm water (26°C) for some time until relaxed then narcotised in a 0.4% aqueous solution of Nembutal for 8-10 h. The 0.4% Nembutal solution is gradually added to the water. Snails for biology and histopathology were tested after 9-10 h by needle and when they do not responded they were transferred to Heidenhain's Susa for fixation until the shell became transparent (decalcification). In the present this process required 8-10 days. The shell of the animals was carefully removed without any damage of the organs of the snails with artery forceps under dissecting microscope. The snail's body was dissected into anterior (includes areas of the head-foot, and mantle areas) and posterior regions (remaining organs of the mantle cavity, digestive gland and ovotestis).

### Heidenhain's Susa fixative

The composition of Heidenhain's Susa fixative is as follows;

Mercuric chloride	4.5 gm
Sodium chloride	0.5 gm
40% Formaldehyde	20 ml
Distilled water	80 ml
Glacial acetic acid	4 ml
Trichloroacetic acid	2 gm.

### Dehydration

After fixation, the regions of the snails must be dehydrated thoroughly in a graded series of (30%, 50%, 70%, 90%, 100% X 2) alcohol and each change of 1 h.

### Infiltration with historesin

After dehydration regions of the snails were infiltrated with Historesin. To make historesin stock infiltration solution, one packet of historesin activator is added in 50 ml of historesin.

- 1) The regions of the snails were kept in 1:1 mixture of alcohol and historesin 12-24 h at 4°C.
- 2) Removed the mixture from the regions of the snails and added fresh historesin for 12-24 h at 4°C.

3) Removed historesin from regions of the snails and added fresh historesin for one-two weeks at 4°C.

#### **Embedding** (historesin plastic blocks)

The ratio of embedding mixture includes 15 ml of historesin and 1 ml of historesin hardener. One should never make more than 16 ml of solution.

1) Fill polythene mould to the top with historesin, put piece of Agar in the bottom of mould and then region of the snails in the centre, and allow to polymerise in fume cupboard for two h.

2) When blocks are hard they can be sawn to shape and stuck onto a perspex chuck with cyanoacrylate (super glue) adhesive.

3) The block was removed from the mould and rub down with wet carborundum paper. When block is smooth it can be joined to the perspex chuck with super glue. Cut off excess plastic with a hack saw.

#### **Sectioning**

After embedding mostly serial and few random nature of the sectioning was done transversely and longitudinally on LKB Bromma 2218 historange microtome (speed 20 mm/second speed and making ribbon) and kept in dry boxes. Sections are usually cut into very thin 4 µm thick with a sharp metal blade/glass knife. The sections are then laid flat on the surface of glass microscope slide. The serially sectioned ribbons were equal to length of the slide and with the help of needle or paint brushe place the lengths-dull side upward-in series so that the first section is in the top left hand corner of the slide and the last section on the right-hand at the bottom. With a diamond, or with a glass pencil, number the slide in the bottom right-hand corner. Dry the slides overnight in an upright position. On the oven or at a temperature near 30°C. At low temperature, the sections may not stick on drying.

Complete serial section were made of all the susceptible and resistant animals from 1-10, 15, 20, 30 and 40 DPE. The random nature of the sections was done only in giant snails at 30 DPE. Every section was examined for the detailed results of intramolluscan development (MS, embryos of DS, DS, germballs, cercaria) and histopathological responses in the various organs of susceptible, resistant and giant snails. Detail histology for normal and infected ovotestis of the susceptible snails was also analysed.

### Transference of sections to slide

Clean slides are essential if sections are to adhere. Failing that use acid alcohol, or cleaning fluid if necessary. Have ready some albumin adhesive mixture and place a very small drop on the slide and rub on well with a clean finger. The albumin adhesive mixture ingredients are as under;

White of egg of	50 ml
Glycerol	50 ml
Sodium salicylate	1 gm

### Staining

The staining method used in the present study is given below;

#### Polychrome staining for historesin sections procedure

1. Stain in 1% Alcian blue in 3% Acetic acid *pH* 2.5 30 min
2. Wash slides in running water 5 min
3. 1% Periodic acid freshly prepared (4 ml of 0.5% Periodic acid and 196 ml of distilled water) 10 min
4. Running water 5 min
5. Schiff reagent (in dark room/fume cupboard) 10 min
6. Running water 5 min
7. Iron Alum Mordant 2.5% 30 min
8. Rinse in water -
9. Heidenhain's haematoxylin 30 min
10. Running water -
11. Iron Alum differentiated with microscopic control until nucleus and cytoplasm shows different features (?)
12. Running water -
13. Acid fuchsin/xylydine ponceau counter stain 10 min
14. Dry slides on hot plate and mount.



**Note.** The staining process may be interrupted at 2, 4 and 6 numbers. The slides left to dry until it is convenient then continue. Don't leave the slide in running water longer than is needed. The timing steps are critical and they must be carried out consecutively. The slides mount with DPX and keep them on hot plate for overnight.

**Results:** Nucleus stained dark, nucleoli, nuclear histone contrasting colours, cytoplasm light and oocyte (egg) pink. Collagen fibres and mucus green, muscles and epithelium stained shades of pink. Nematodes cuticle, refractive bodies and excretory glands yellow with aurantia background green. The trematode cuticular spines and granules yellow.

### **Mounting**

The stained slides were mounted with DPX and coverslips and dried on hot plate over night. Finally, the slides were interpreted on a light microscope. The mounting media DPX has refractive index 1.515 No. and consists of 80% Xylene.

## *REFERENCES*

## REFERENCES

- Abdulssalam, M. and Sarwar, M.M, 1953. Occurance of *Orincho bilharzia turkestanicum* in Pakistan. Proceeding of the 4<sup>th</sup> Pakistan Science Conference. 4, 142-143.
- Amer, M, 1994. Cutaneous schistosomiasis. Contemporary Tropical Dermatology. 12, 713-717.
- Anwar, A.H, 1982. Studies on ecology, pathogenesis and prophylaxis of schistosomiasis in cattle and buffaloes. Res. Study No. 6 Anim. Sci. Sector, PARC Board, U.A.F.
- Anwar, A.H. and Gill S.A, 1990. A study on ecology of schistosomiasis in cattle and buffaloes. Pakistan Veterinary Journal. 10, 86-87.
- Aradaib, I.E., Omer, O.H., Abbas, B.B., Bushra, H.O., Elmalik, K.H., Saad, A.M., Osburn, B.I. and Taylor, M.G, 1995. *Schistosoma bovis* whole egg antigen did not protect Zebu calves against experimental schistosomiasis. Preventive Veterinary Medicine. 21, 339-345.
- Aradaib, I.E., Abbas, B.B., Reimann, H.P. and Osburn, B.I, 1995. Experimental bovine schistosomiasis in Zebu calves. Ciencia-Rural. 25, 99-103.
- Baker, F.C, 1945. The molluscan family Planorbidae. Univ. Illinois Press, Urbana, Illinois, pp. 520.
- Basch, P.F, 1976. Intermediate host specificity in *Schistosoma mansoni*. Experimental Parasitology. 39, 150-169.
- Baudoin, M, 1975. Host castration as parasitic strategy. Evolution. 29, 335-352.
- Bayne, C.J. and Hull, C.J, 1988. The host parasite interface in molluscan schistosomiasis: Biotin as a probe for sporocyst and hemocyte surface peptides. Veterinary Parasitology. 29, 131-142.
- Bayne, C.J. and Yoshino, T.P, 1989. Determinants of compatibility in mollusc-trematode parasitism. American Zoologist. 29, 399-407.
- Becker, W, 1968. Untersuchungen uber die aus der Mutter sporocyste suswandernden Trochtersporocysten von *Schistosoma mansoni* I. Beitrage zum Kohlenhydrastoffwechsel dieser Stadien. Zeitschrift fur Parasitenkunde. 30, 233-251.
- Becker, W, 1980. Metabolic interrelationship of parasitic trematodes and molluscs, specially *Schistosoma mansoni* in *Biomphalaria glabrata*. Zeitschrift fur Parasitenkunde. 63, 101-111.
- Bethlem, E.P., Schettino, G. and Carvalho, C.R, 1997. Pulmonary schistosomiasis. Curr opin Pulm Med. 3, 361-365.

Bidinger, P.D. and Crompton, D.W.T, 1989. A possible focus of schistosomiasis in Andhra Pradesh, India. Transaction of the Royal Society of Tropical Medicine and Hygiene. 83, 526.

Bilharz, T.M, 1852. Fernerr Beobachtungen uber das die Pfortader des Menschen bewohnende *Distomum haematobium* und sein verhaltniss zu gewissen pathologischen Bildungen aus brieflichen Mitheilungen an Professor v. Siebold vom 29. Marz 1852. Zeitschrift fur Wissenschaftliche Zoologie. Leipzig. 4, 72-76.

Blackstock, N.,: Personal communication.

Bloch, E.H, 1980. In vivo microscopy of schistosomiasis. II. Migration of *Schistosoma mansoni* in the lungs, liver and intestine. American Journal of Tropical Medicine and Hygiene. 29, 62-70.

Bogitsh, B.J, 1975. Cytochemical localization of peroxidase activity in the miracidium of *Schistosoma mansoni*. The Journal of Parasitology. 61, 621-626.

Borges, C.C., Souza, C.P. and Andrade, Z.A, 1998. Histopathologic features associated with susceptibility and resistance of Biomphalaria snails to infection with *Schistosoma mansoni*. Mem Inst Oswaldo Cruz. 93, 117-121.

Boros, D.L. and Warren, K.S, 1970. Delayed hypersensitivity-type granuloma formation and dermal reaction induced and elicited by a soluble factor isolated from *Schistosoma mansoni* eggs. Journal of Experimental Medicine. 132, 488-507.

Bruce, J.I., Warren, K.S. and Sadun, E.H, 1972. The pathophysiology of *Schistosoma mansoni* in monkeys. (Abstract), Journal of Parasitology. 48, 20.

Cameron, T.D. and Thomas, W.M, 1951. The parasites of the Domestic animals. Second Edition, Adam and Charles Black 4, 5 and 6 Soho Square London W. 1.

Chandler, A.C, 1926. A new schistosome infection in man, with notes on other human fluke infection in India. Indian Journal of Medical Research. 14, 179-183.

Cheng, T.C, 1973. General Parasitology. Academic Press New York and London, pp. 417-419.

Cheng, T.C. and Bier, J.W, 1972. Studies on molluscan schistosomiasis: An analysis of the development of the cercaria of *Schistosoma mansoni*. Parasitology. 64, 129-141.

Chirstopher, T. and Rao, T.S, 1975. Nasal schistosomiasis in animals. Food Farm Agriculture, Calcuta. 7, 27-28.

Chitsulo, L., Engels, D., Montresor, A. and Savioli, L, 2000. The global status of schistosomiasis and its control. Acta Trop. 77, 41-51.

Cooke, G.S., Lalvani, A., Gleeson, F.V. and Conlon, C.P, 1999. Acute pulmonary schistosomiasis in traveler returning from lake Malawi, sub-Saharan Africa. Clin Infect Dis. 29, 836-839.



- Cort, W.W., Ameel, D.J. and Woude, A.V.D, 1952. Development of the mother and daughter sporocysts of a snake Plagiorchioid, *Lechriorcis primus* (Trematoda: Reniferidae). The Journal of Parasitology. 38, 187-202.
- Cousin, C., Ofori, K., Acholonu, S., Miller, A., Richards, A., Lewis, F. and Knight, M, 1995. *Schistosoma mansoni*: Changes in the albumin gland of the *Biomphalaria glabrata* snails selected for nonsusceptibility to the parasite. Journal of Parasitology. 8, 905-911.
- Crews, A.E. and Esch, G.W, 1986. Seasonal dynamics of *Halipegus occidualis* (Trematoda: Hemiuridae) in *Helisoma anceps* and its impacts on fecundity of the snail host. Journal of Parasitology. 72, 646-651.
- Crews, A.E. and Yoshino, T.P, 1989. *Schistosoma mansoni*. Effects of infection on reproduction and gonadal growth in *Biomphalaria glabrata*. Experimental Parasitology. 68, 326-334.
- Dawes, B, 1946. The Trematoda. Cambridge at the University Press.
- De Jong-Brink, M, 1995. How schistosome profit from the stress responses thus elicit in their hosts. Advances in Parasitology. 35, 177-256.
- Diaz-Rivera, R.S., Ramos-Morales, F., Sotomayor, Z.R., von Lichtenberg, F., Garcia-Palmeiri, M.R., Cintron-Rivera, A.A. and Marcahnd, E.J, 1957. The pathogenesis of *Manson's schistosomiasis*. Annals of International Medicine. 47, 1082-1107.
- Doherty, J.F., Moody, A.H. and Wright, S.G, 1996. Katayama fever: an acute manifestation of schistosomiasis. BMJ. 313, 1071-1072.
- Dunne, A.M, 1978. Veterinary Helminthology. Second Edition Williams Heinemann Medical Book Limited, London. WC LB 3 HH.
- Eckelbarger, Bieler, R. and Mikkelsen, P.M, 1990. Ultrastructure of sperm development and mature sperm morphology in three species of commensal Bivalves (Mollusca: Galeommatoidea). Journal of Morphology. 205, 63-75.
- Etges, F.J. and Gresso, W, 1965. Effect of *Schistosoma mansoni* infection upon fecundity in *Australorbis glabratus*. Journal of Parasitology. 51, 757-760.
- Faust, E.C., Beaver, P.C. and Jung, R.C, 1968. Animal Agents and Vectors of Human Diseases. Third Edition Lea and Febiger, Philadelphia, p 461.
- Gadgill, R.K. and Shah, S.N, 1952. Cited by Southgate, V.R., and Agrwal, M.C., Schistosomiasis in India. Parasitology Today. 6, 166-168.
- Gadgill, R.K. and Shah, S.N, 1995. *Schistosoma nasale* in India. Indian Journal of Medical Research. 43, 695-701.
- Garson, S. and Williams, J.S, 1957. Transmission of *Schistosoma mansoni*. (Abstract) Journal of Parasitology. 43, 27-28.

Gordon, R.M., Davey, T.H. and H. Peaston, H, 1934. The transmission of human bilharziasis in Sierra Leone, with an account of the life cycle of the schistosome concerned, *Schistosoma mansoni*, and *Schistosoma haematobium*. Annals of Tropical Medicine Parasitology. 28, p 323.

Godoy A., Souza, C.P., Guimarães, C.T. and Andrade, Z.A, 1997. Unusual histological findings in *Biomphalaria glabrata* with high degree of resistance to *Schistosoma mansoni* miracidia. Mem Inst Oswaldo Cruz 92, 121-122.

Healy, J.M., 2001. Spermatogenesis and oogenesis. In "The Biology of Terrestrial Molluscs. Edition Barkers, G.M. pp. 357-382.

Hicken, H.I.T, 1970. Integrated principles of zoology. 4<sup>th</sup> edition Mosby.

Hirata, M., Kage, M., Takushima, M. and Fukuma, T., 1993. Different courses of granulomatous reactions around *Schistosoma japonicum* eggs in three strains of mice. Journal of Parasitology. 79, 266-273.

Hirata, M., Takushima, M., Kage, M. and Fukuma, T, 1993. Comparative analysis of hepatic, pulmonary, and intestinal granuloma formation around freshly laid *Schistosoma japonicum* eggs in mice. Parasitology Research. 79, 316-321.

Hunbendick, B, 1955. Phylogeny in the Planorbidae. Tran. Zool. Soc. London. 28, 453-542.

Hurd, H, 1990. Physiological and behavioral interaction between parasites and invertebrate hosts. Advances in Parasitology. 29, 271-318.

Hussain, M.F., Basmacil, S.M. and Hassan, H.A, 1984. Urinary schistosomiasis in sheep: a case report. Annals of Tropical Medicine and Parasitology. 78, 439-441.

James, B.L, 1965. The effects of parasitism by larval digenea on the digestive gland of the intertidal prosobranch, *Littorine saxatilis* (olivi) subsp. *Tenbrosa* (Montagu). Parasitology. 55, 93-115.

Johnston, L.A. and Yoshino, T.P, 1996. Analysis of lectin-and snail plasma-binding glycopeptides associated with the tegumental surface of the primary sporocysts of *Schistosoma mansoni*. Parasitology. 112, 469-479.

Jordan, P. and Webbe, G, 1969. "Human schistosomiasis". London William Heinemann, Medical Book limited.

Jordon, P. and Webbe, J, 1982. Schistosomiasis. Epidemiology, treatment and control. London William Heinemann Medical Book limited.

Jourdane, J, 1982. Biological control of snail hosts of schistosomiasis. WHO/VBC/82.837. pp. 11.

- Jourdane, J. and Theron, A, 1987. Larval development: eggs to cercariae. In "The Biology of Schistosomes from Genes to Latrines" (Eds. Rollinson, D., Simpson, A.J.G.), Academic Press New York/London.
- Kassim, O.O. and Richards, C.S, 1979. Host reaction in *Biomphalaria glabrata* to *Schistosoma mansoni* miracidia, involving variations in parasite strains numbers and sequence of exposures. International Journal for Parasitology. 9, 565-570.
- Khalid, S.E. and Mahmood, S.M, 2001. Schistosomiasis available differential for haematuria in travelers in Pakistan. Journal of Pakistan Medical Association. 51(9), 9/2.
- Khalil, A., Baveja, U.K., Jain, N., Mathur, N.B. and Puri, P.K, 1993. Acute schistosomiasis in the Indian subcontinent. Indian Pediatrics, 30, 1458-1460.
- King, C.L, 2001. Initiation and regulation of the disease in schistosomiasis. In: Mahmoud, A.A.F, ed. Schistosomiasis. London: Imperial College Press, 213-264.
- Kinoti, G.K, 1971. The attachment and the penetration apparatus of the miracidium of schistosoma. Journal of Helminthology. 45, 229-235.
- Lapage, G, 1968. "Veterinary Parasitology". Second Edition Oliver and Boyd Edinburgh and London. pp. 24, 67.
- Lewis F.A., Richards, C.S., Knight, M., Cooper, L.A. and Clark, B, 1993. *Schistosoma mansoni*: analysis of an unusual infection phenotype in the intermediate host snail *Biomphalaria glabrata*. Experimental Parasitology. 77, 349-361.
- Lie, K.J., Heyneman, D. and Richards, C.S, 1977. *Schistosoma mansoni*: temporary reduction of natural resistance in *Biomphalaria glabrata* induced by irradiated miracidia of *Echinostoma paraensei*. Experimental Parasitology. 43, 54-62.
- Lie, K.J., Jeong, K.H. and Heyneman, D, 1987. Molluscan host reactions to helminthic infection. In "Immune Responses in Parasitic Infections". (Soulsby, E.J.L, Ed), CRC Press, Boca Raton, F.L.
- Lo, C.T, 1972. Compatibility and host-parasite relationships between species of the genus *Bulinus* (Basommatophora: Planorbidae) and an Egyptian strain of *Schistosoma haematobium* (Trematoda: Digenea). Malacologia. 11, 225-280.
- Locker, E.S, 1994. On being a parasite in an invertebrate host: a short survival course. Journal of Parasitology. 80, 728-747.
- Loker, E.S, 1979. Effects of *Schistosomatium douthiui* infection on the growth, survival, and reproduction of *Lymnaea catascopium*. Journal of Invertebrate Pathology. 34, 138-144.
- McClelland, G. and Bourns, T.K.R, 1969. Effects of *Trichobilharzia ocellata* on growth, reproduction and survival of *Lymnaea stagnalis*. Experimental Parasitology. 24, 137-146.

MC Mullen, D.B., Endo-Itabashi, T., Seto, S., Komiyama, S. and Stone, P.R, 1951. Seasonal studies of *Schistosoma japonicum* in the intermediate host, *Oncomelania nasophora*. American Journal of Hygiene, 54, 416-430.

Meglitsch, P.A, 1967. Invertebrate Zoology. Second Edition Oxford University Press London p 192.

Minchella, D.J, Leathers, B.K., Brown, K.M. and McNair, J. M, 1985. Host and parasite counter adaptations: An example from a fresh water snail. American Naturalist.126, 843-854.

Molyneux, D.H, 1993. In "Modern Parasitology". A textbook of parasitology edited by Cox, F.E.G., Second Edition Blackwell Scientific Publication London Edinburg Boston, p 259.

Montgomery, R.E, 1906 a. Observations on bilharziasis among animals in India. I. Journal of Tropical Veterinary Science. 1, 14-46.

Montgomery, R.E, 1906 b. Observations on bilharziasis among animals in India. II. Journal of Tropical Veterinary Science. 1, 138-174.

Muraleedharan, K., Kumar, P. and Hedge, K.S, 1976 a. Studies on the epizootiology of nasal schistosomiasis of bovines. 2-Intensity and severity of infection. Mysore Journal of Agricultural Sciences. 10, 463-470.

Muraleedharan, K., Kumar, P., Hedge, K.S. and Alwar, V.S, 1976 b. Studies on the epizootiology of nasal schistosomiasis of bovines. 1-Prevalence and incidences of infection. Mysore Journal of Agricultural Sciences. 10, 463-470.

Muraleedharan, K., Kumar, P., Hedge, K.S. and Alwar, V.S, 1976 c. A note on the intermediate host of *Schistosoma nasale*, Rao, 1933 and on the seasonal prevalence of its cercariae. Indian Veterinary Journal. 53, 819-820.

Naik, K.N, 1942. Experiments on the control of nasal granuloma. Indian Journal of Veterinary Sciences and Animal Husbandry. 12, 150-159.

Nash, T.E., Cheever, A.W., Ottesen, E.A. and Cook, J.A, 1982. Schistosome infections in humans perspectives and recent findings. Annals of Internal Medicine. 97, 740-754.

Newton, W.L, 1952. The comparative tissue reaction of two strains of *Australorbis glabratus* to infection with *Schistosoma mansoni*. The Journal of Parasitology. 362-366.

Newport, G.R., McKerrow, J., Hedstorm, R., Pettitt, M., McGarrigle, L., Barr, P.J. and AgaBian, N, 1988. Cloning of the proteinase that facilitates infection by schistosome parasites. Journal of Biological Chemistry. 263, 13179-13184.

Pan, C.T, 1958. The general histology and topographic microanatomy of *Australorbis glabratus*. Bulletin of the Museum of Comparative Zoology. 119, 242-245.

Pan, C.T, 1963. Generalized and focal tissue response in the snail *Australorbis glabratus* infected with *Schistosoma mansoni*. Annals of New York Academy of Sciences. 113, 475-485.

Pan, C.T, 1965. Studies on the host-parasite relationship between *Schistosoma mansoni* and the snail *Australorbis glabratus*. American Journal of Tropical Medicine and Hygiene. 14, 931-975.

Pan, C.T, 1980. Studies on the host-parasite relationship between *Schistosoma mansoni* and *Australorbis glabratus*. Journal of Invertebrate Pathology. 36, 307-372.

Pappas, P.W, 1988. The relative roles of the intestines and external surfaces in the nutrition of monogeneans, digeneans and nematodes. In Arme, C., and Chappell, L.H., Editions Molecular transfer across parasite membranes. 96 (Supplement), S105-S121.

Paraense, W.L. and Deslandes, N, 1955. Observation on the morphology of *Australorbis glabratus*. Mem Inst Oswaldo Cruz. 53, 87-103.

Pathan, Z.A, 1999. "Studies on screening and chemical control of intermediate host snail". M.Sc: Thesis, Department of Parasitology, Sindh Agriculture University, Tando Jam.

Pellegrine, J, 1967. Protection against human schistosome cercariae. Experimental Parasitology. 21, 112-131.

Prah, S.K. and James, C, 1977. The influence of physical factors on the survival and infectivity of miracidia of *Schistosoma mansoni* and *Schistosoma haematobium*. I. Effect of temperature and ultra-violet light. Journal of Helminthology. 51, 73-85.

Rabello, A.L., Dasilva, R.A.P., Rocha, R.S. and Katz, N, 1994. Recent molecular approaches to the study of schistosome Genetics. American Journal of Tropical Medicines and Hygiene. 50, 748-752.

Rao, M.A.N, 1933. Bovine nasal schistosomiasis in Madras Presidency with a description of the parasite. Indian Journal of Veterinary Sciences and Animal Husbandry. 3, 29-38.

Rao, P.L.N. and Murthy, G.K, 1964. Treatment of nasal schistosomiasis in cattle. Indian Veterinary Journal. 34, 341-343.

Rao, N.S.K. and Naik, R.H, 1957. Nasal schistosomiasis in buffaloes. Indian Veterinary Journal. 34, 341-343.

Ricahrd, C.S, 1984. Influence of snail age on genetics variation in susceptibility of *Biomphalaria glabrata* for infection with *Schistosoma mansoni*. Malacologia. 25, 493-502.

Rifkin, E, 1971. Interaction between *Schistosoma mansoni* schistosomules and penetrated mouse skin at the ultrastructural level. In "Aspects of the biology of Symbiosis" (Cheng, T.C, edition), University Park Press, Baltimore, Maryland, pp. 25-43.

Rocha, J.V., Lombardineto, F. and Bacellar, A.A.A, 1995. Calculo do fator comprimento de rampa (L), um a metodologia para uso em sistema de Informa coes Geograficas, SP, (Trabalho a Ser Publicado).

Rogers, S.H. and Reeder, R.L, 1987. Structure and function of the spermatheca in a snail host of schistosomiasis, *Biomphalaria glabrata*. Journal of Morphology. 191, 205-308.

Rollinson, D. and Simpson, A.J.G, 1987. The Biology of schistosomes from genes to latrines. Academic Press Harcourt Brace Jovanovich, Publishers London.

Ross, A.G.P., Bartley, P.B., Sleight, A.C., Olds, G.R., Li, Y., Williams, G.M. and MCManus, D.P, 2002. Schistosomiasis. The New England Journal of Medicine. 346, 1212-1220.

Saad, M., Din, N., Kornelis, D., Vanzeyl, R.J.M. and Deelder, A, 1994. Immunologic characterization of tow monoclonal antibodies reactive carbohydrates epitopes of circulating *Schistosoma mansoni* egg antigen. American Journal of Tropical Medicines and Hygiene. 50, 487-498.

Sahay, M.N. and Sahai, B.N, 1978. Studies on the susceptibility of the laboratory animal, kids and lambs to experimental nasal schistosomiasis. Indian Journal of Parasitology. 64, 1135-1136.

Sahito, S, 2002. "Laboratory screening of the schistosome susceptible intermediate snail host". M.Sc: Thesis, Department of Parasitology, Sindh Agriculture University, Tando Jam.

Sambon, L.W, 1907. Remarks on *Schistosoma mansoni*. Journal of Tropical Medicine and Hygiene. 10, 303.

Sasa, M, 1972. A historical review of early Japanese contributions to the knowledge of *Schistosomiasis japonica*. In: Yokogawa M, ed. Researches in filariasis and schistosomiasis 2. Baltimore: University Park Press. pp. 235-261.

Sathe, B.D. and Renapukar, D.M, 1983. Schistosomiasis in India. Bulletin of the Haffkine Institute. 11, 8.

Schutte, C.H.J, 1974 b. Studies on the South African strains of *Schistosoma mansoni*. Part 2: The intramolluscan larval stages. South African Journal of Science. 70, 327-346.

Schutte, C.H.J, 1975. Studies on the South African strains of *Schistosoma mansoni*. Part 3: Notes on certain host-parasite relationship between intramolluscan larvae and intermediate host. South African Journal of Science. 71, 8-20

Sluiters, J.F, 1981. Development of *Trichobilharzia ocellata* in *Lymina stagnalis* and effects of infections on the reproductive system of the host. Zeitschrift fur Parasitenkunde. 64, 303-319.

Smith, J.H.M.D. and Christie, J.D, 1986. The pathobiology of *Schistosoma haematobium* in humans. Progress in Pathology. 17, 333-345.

Smith, H.A. and Jones, T.C, 1961. Veterinary Pathology. 2<sup>nd</sup> Edition Henry Kimpton 134 great Portland street, London W.1.

Smith, J.H. M.D., Elwi, A. and Kamel, I.A, 1975. A quantitative postmortem analysis of urinary schistosomiasis in Egypt. II. Evaluation and epidemiology. American Journal of Tropical Medicine and Hygiene. 24, 806-822.

Sonsino, P, 1876. On a new parasite of cows, *Bilharzia bovis*. Rendiconti dell'Accademia della Scienze Fisiche e Matematiche. Napoli. 15, 84-87.

Soomro, N.M, 1996. Pathology of schistosome infection in mice and vector snails. Ph.D thesis, University of North Wales, Bangor, United Kingdom.

Souza, C.P., Janotti-Passos, L.K. and Freitas, J.R, 1995 a. Degree of host-parasite compatibility between *Schistosoma mansoni* and their intermediate molluscan hosts in Brazil. Mem Inst Oswaldo Cruz. 90, 5-10.

Souza, C.P., Borges, C.C., Santana, A.G. and Andrade, Z.A, 1997. Comparative histopathology of *Biomphalaria glabrata*, *B. tenagophila* and *B. straminea* with variable degrees of resistance to *Schistosoma mansoni* miracidia. Mem Inst Oswaldo Cruz. 92, 517-522.

Sreeramula, P, 1982. Some epidemiological observations on nasal schistosomiasis in Andhra Pradesh. Livestock Advisor. 7, 47-48.

Suilt, Y.S.M., Domingo, E.O., Dalmacio-Cruz, A.E., DePeralta, D.S. and Imperial, E.S, 1964. Parasitic cirrhosis among Filipinos. Journal of Philippine Medical Association. 40, 1021-1038.

Sullivan, J.T. and Richards, C.S, 1981. *Schistosoma mansoni*, NIH-SM-PR-PR strain, in susceptible and nonsusceptible stocks of *Biomphalaria glabrata*: Comparative Histology. Journal of Parasitology. 67, 702-708.

Sussan, E. and Aiello, B.S, 1998. Merck Veterinary Manual (Ed. 8<sup>th</sup>) Merck and Company INC. pp. 29-31.

Theron, A, 1981. Dynamics of larval populations of *Schistosoma mansoni* in *Biomphalaria glabrata*. II. Chronobiology of the intramolluscal larval development during the shedding period. Annals of Tropical Medicine and Parasitology. 75, 547-554.

Utqhart, G.M., Armour, J., Duncan, J.L., Dunne, A.M. and Jennings, F.W, 1987. Veterinary Parasitology. Longman Scientific and Technical, Longman group UK Limited, Essex CM20 2JE, England.

- Varma, A.K, 1954. Studies on nature, incidence, distribution and control of schistosomiasis and fascioliasis in Bahar. Indian Journal of Veterinary Sciences and Animal Husbandry. 24, 11-33.
- Vegila, F. and Le Roux, P.L, 1929. "On the morphology of a schistosome (*Schistosoma mattheei* sp. nov.) from the sheep in the Cape Province", pp. 335-346. 15<sup>th</sup> Annual Report, Director of Veterinary Services, Union of South Africa 1929. Government Printer, Pretoria.
- von Lichtenberg, F, 1964. Studies on granuloma formation. III. Antigen sequestration and destruction in the schistosome pseudotubercle. American Journal of Pathology. 45, 75-94.
- Wajdi, N, 1966. Penetration by the miracidia of *Schistosoma mansoni* into the snail host. Journal of Helminthology. XL, 235-244,
- Wilcoks, C. and Manson-Bahr, P.E.C, 1972. "Manson's Tropical Diseases". Seventeenth Edition, Baillier Tindall, London.
- Wilson, R.A. and Denison, J, 1980. The parasitic castration and gigantism of *Lyamina truncatula* infected with the larval stages of *Fasciola hepatica*. Zeitschrift fur Parasitenkunde. 61, 109-119.
- World Health Organization, 1985. The control of schistosomiasis. Report of a WHO Expert Committee, Technical Report Series No. 728, Geneva, pp. 28-33 and 113.
- World Health Organization, 1989. An estimates of global needs for praziquentel within schistosomiasis control programme. 102, Rev. 1, p 2.
- World Health Organization, 1993. The control of schistosomiasis. Second Report of the WHO Expert Committee. WHO Technical Report Series n° 830.
- Wright, C.A, 1966 a. "The pathogenesis of helminthes in the mollusca. Helminthological Abstract. 35, 207-224.
- Wright, C.A, 1966 b. "Miracidial responses to molluscan stimuli". Proceeding First International Congress Parasitology. (Rome, 1964). 1058.
- Wright, C.A, 1966 c. "Relationships between schistosomes and their molluscan hosts in Africa". Journal of Helminthology. 40, 403-412.
- Wright, C.A, 1966 d. "Experimental Taxonomy: a review of some techniques and their applications". International Review Genetics. Experimental Zoology. 2, 1-42.
- Wright, C.A, 1971. Flukes and Snails. The science of biology series 4. London George Allen and UNWIN Limited. pp. 38-58.
- Yapp, W.F, 1963. Molluscs, In Barradacle Manual of elementary zoology. 14<sup>th</sup> edition Oxford University Press London. pp. 69-70.



Yoshino, T.P. and Vasta, G.R, 1996. Parasitic invertebrates interactions. In "Invertebrate Immune Responses". Volume 2 (Cooper, E.L. ed.), Advances in comparative and Environmental Physiology, Springe-Verlag, Berlin.